

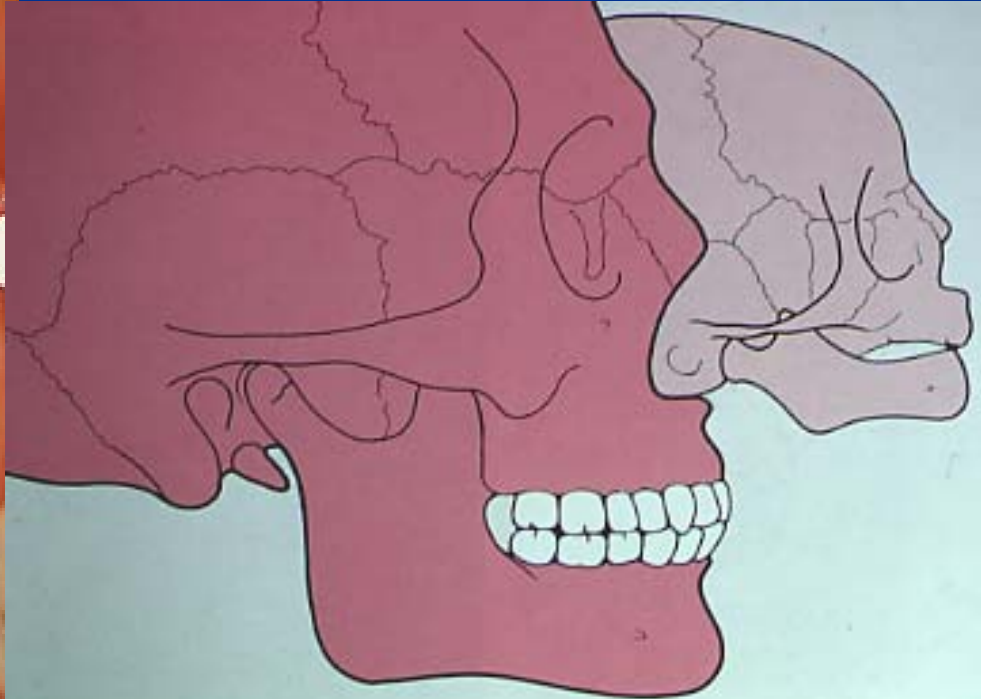
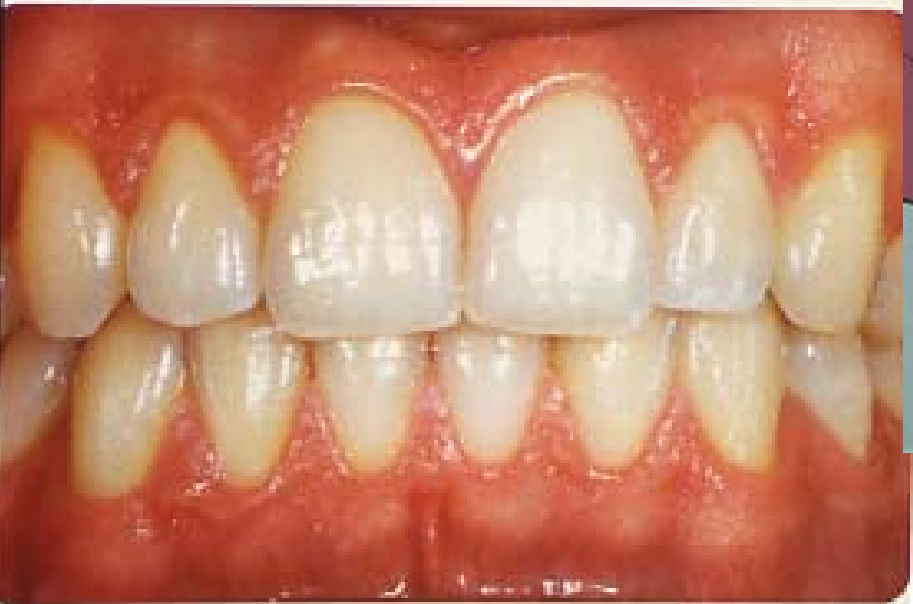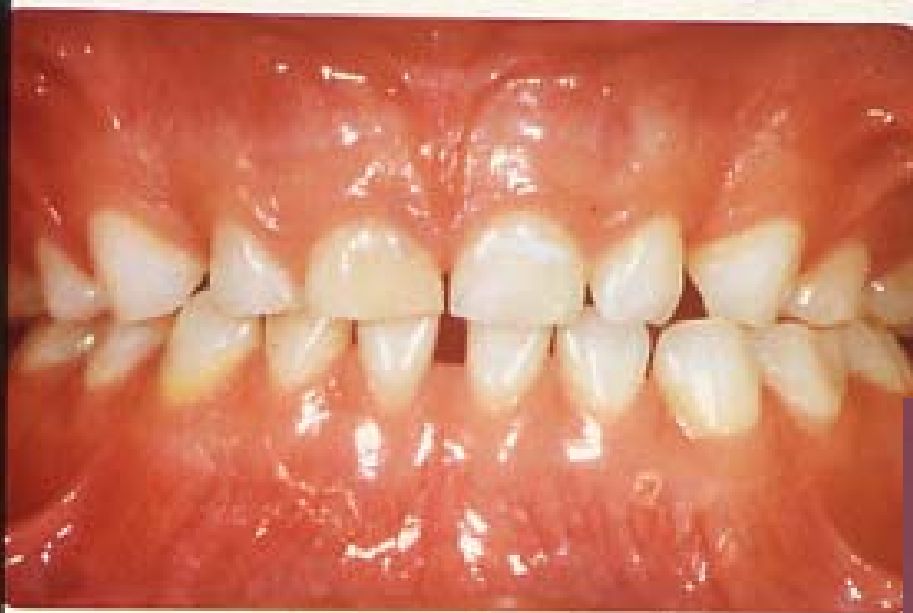Ortodonzia:

Come...

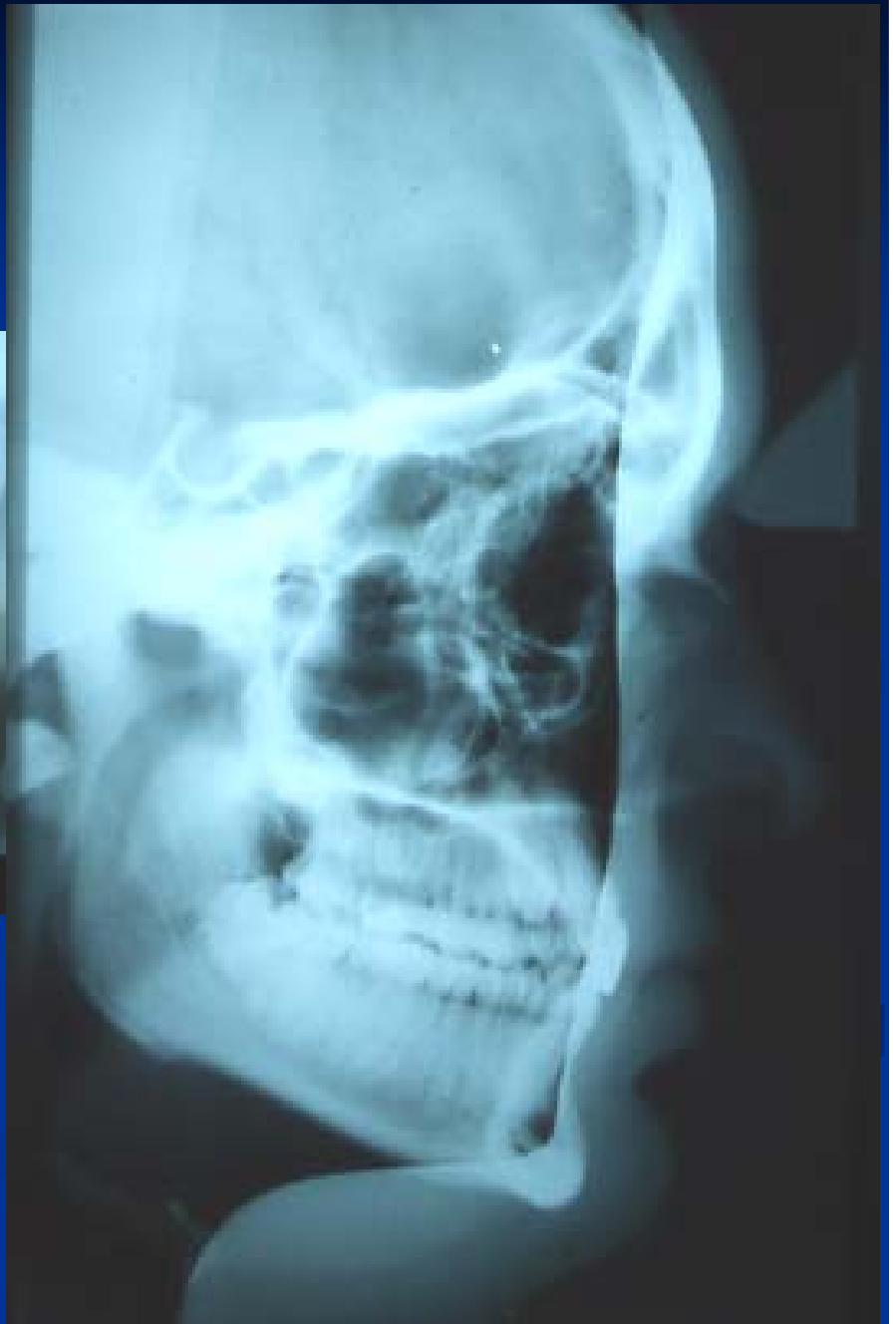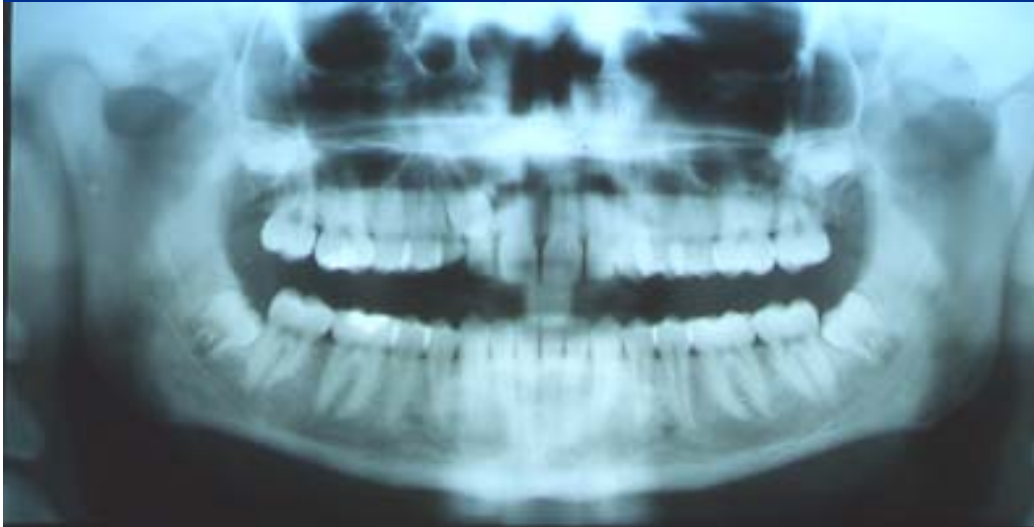Quando...

Perché...

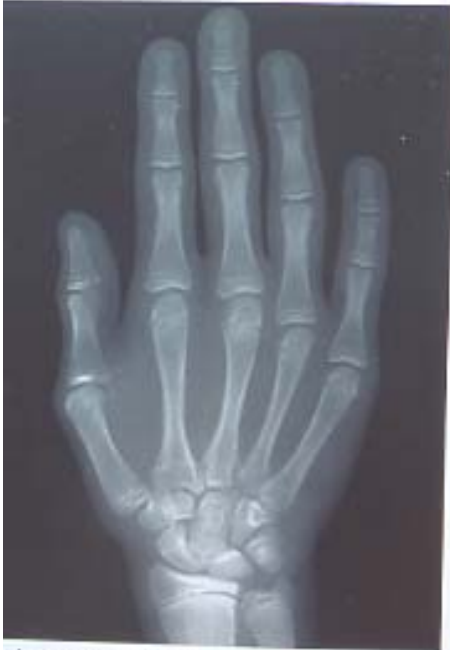



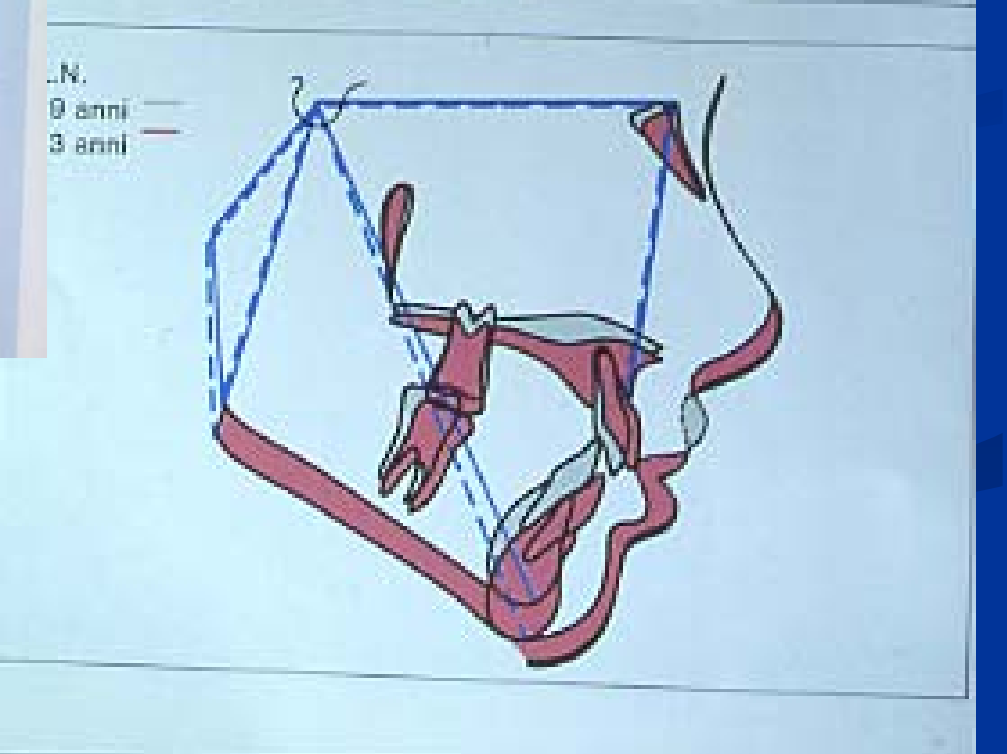
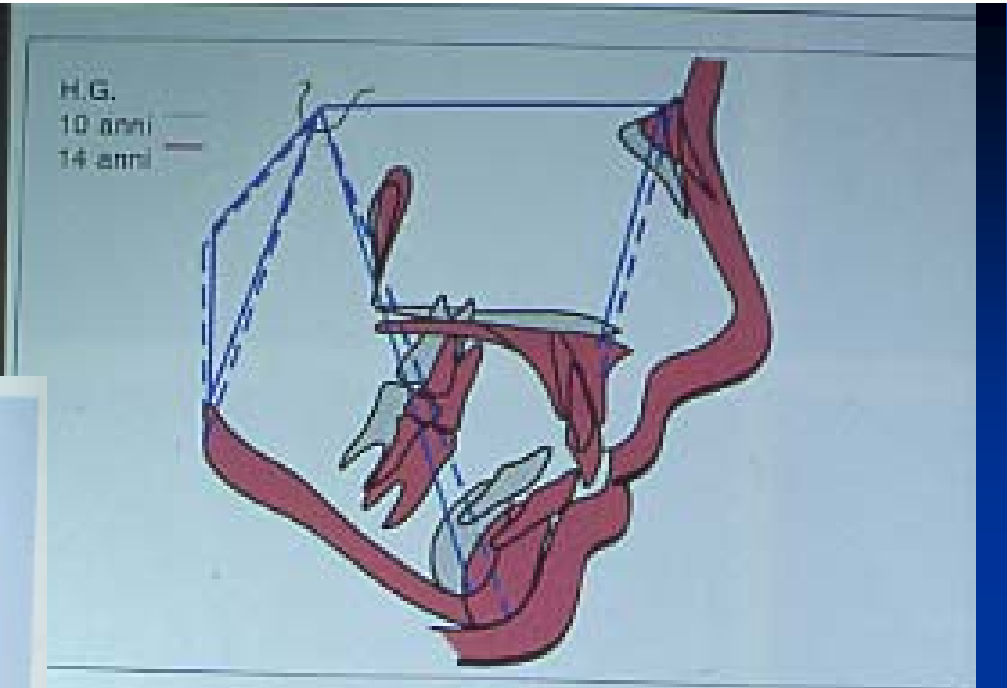
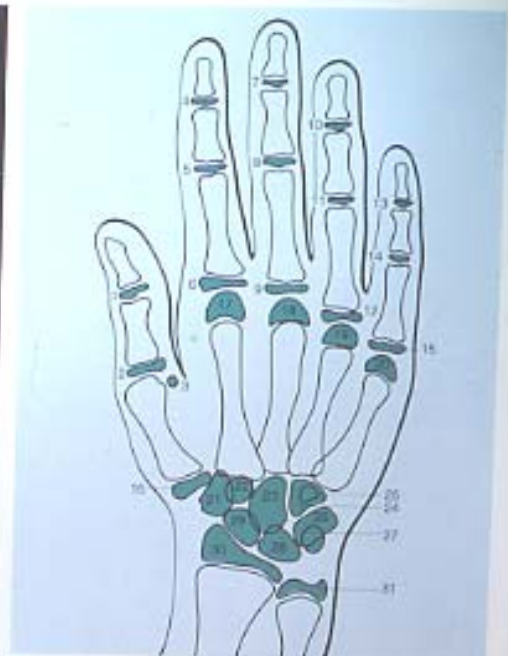**Quali esami radiologici  
sono utili?**

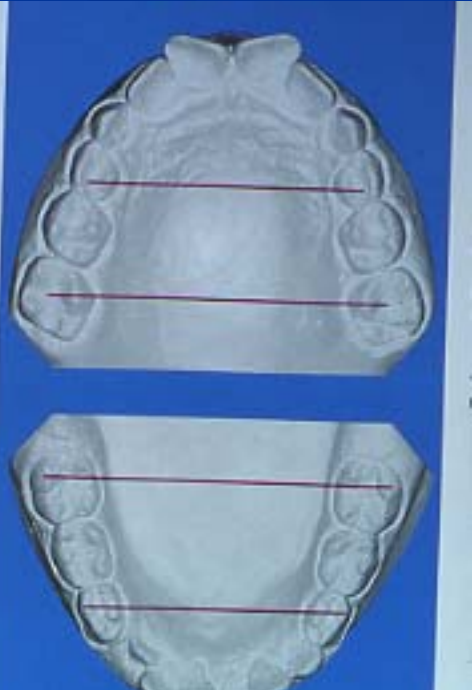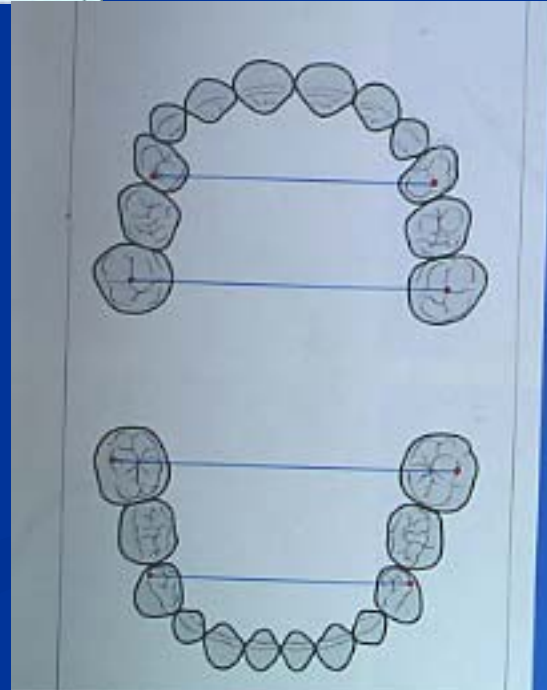
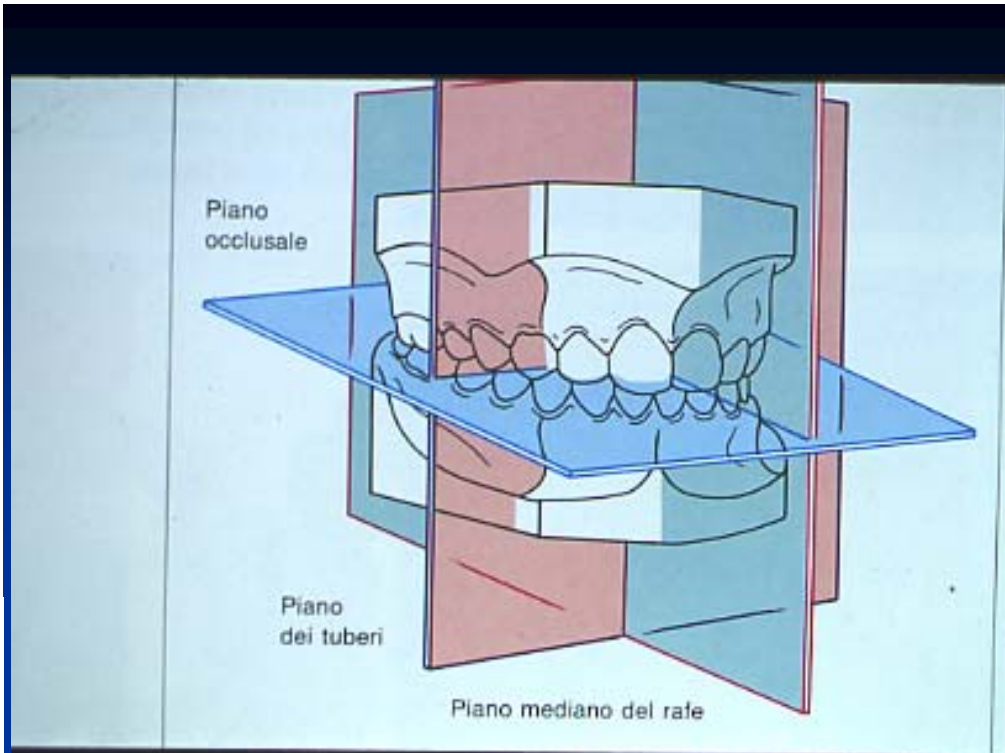


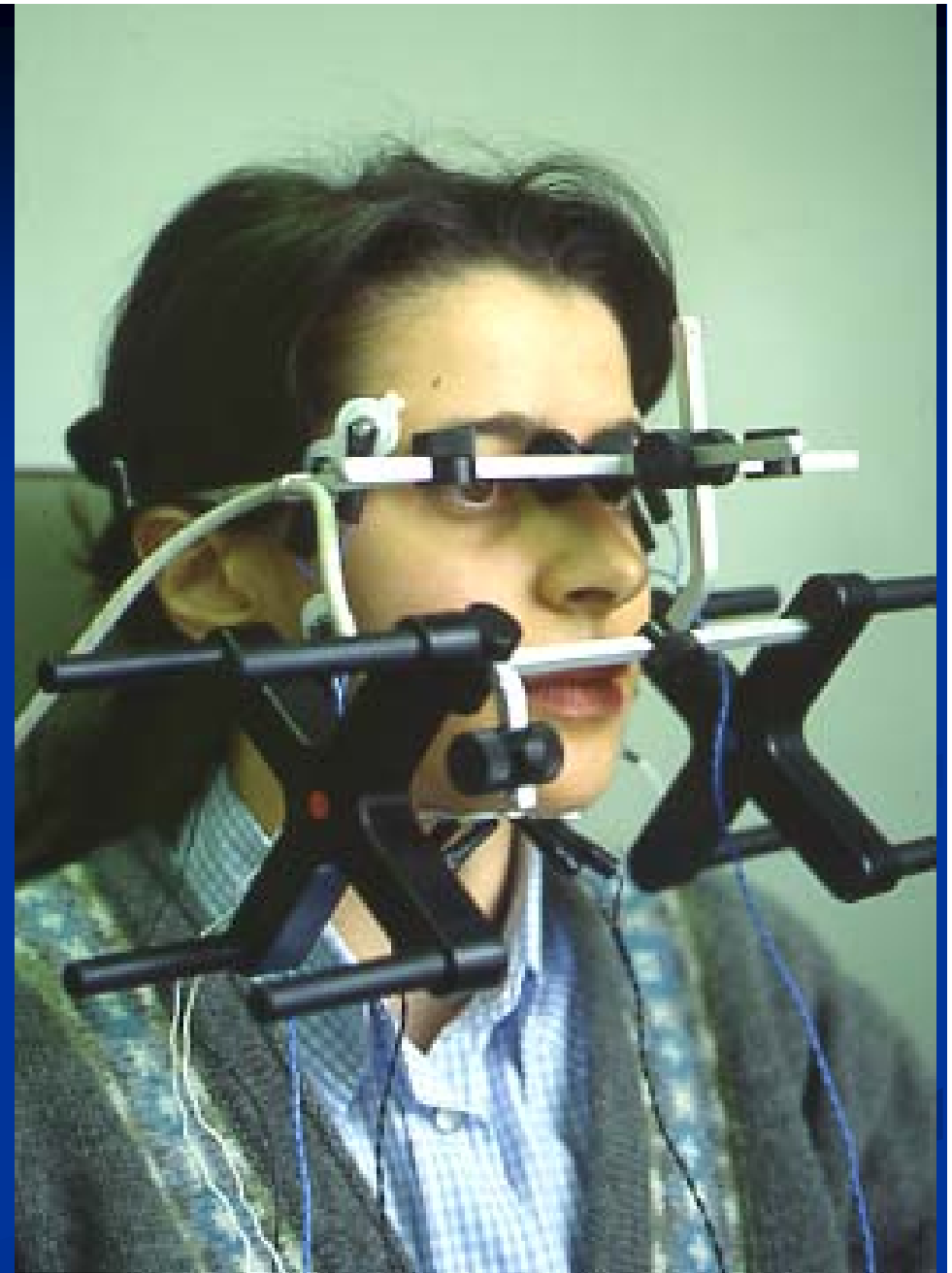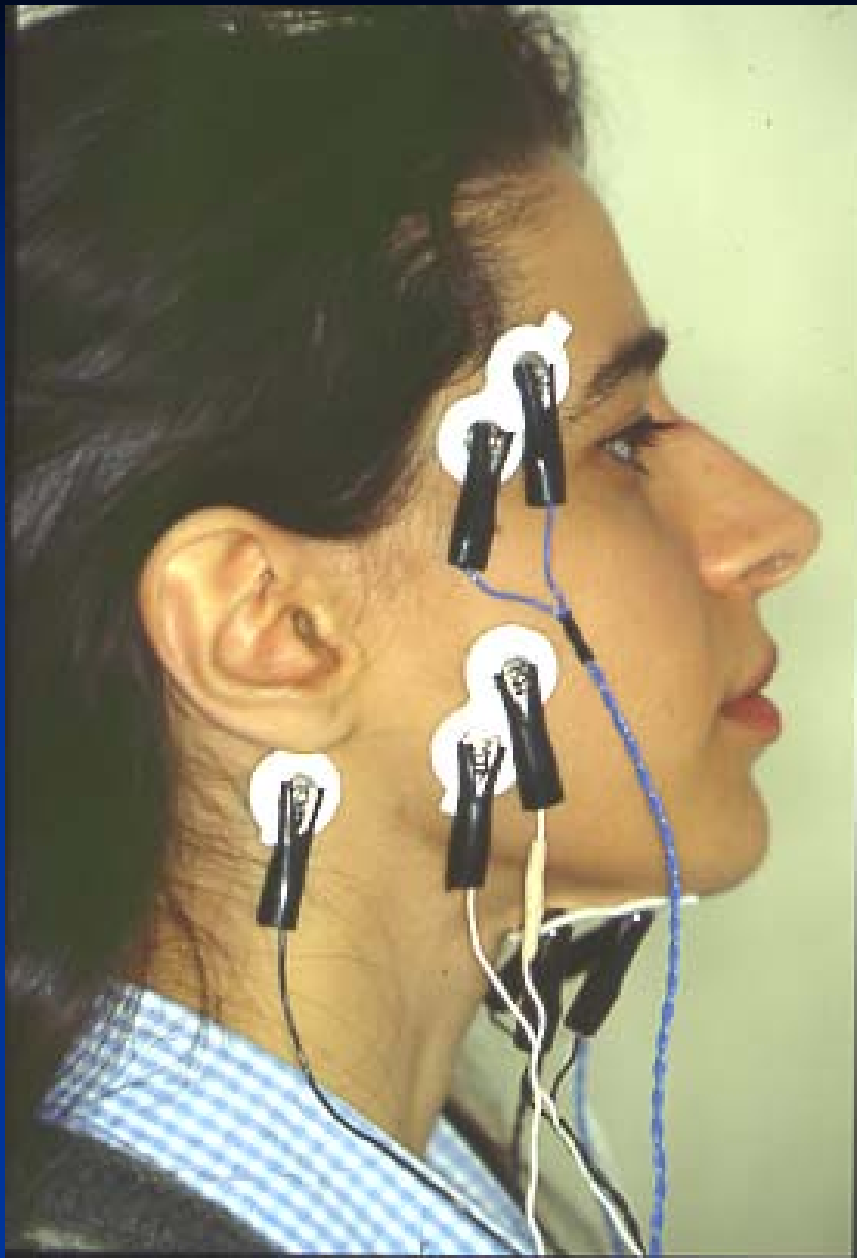




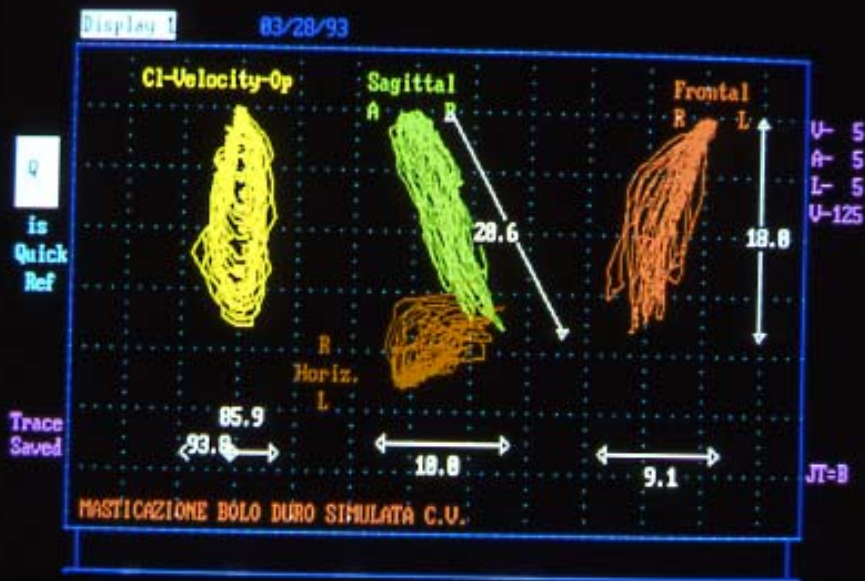
Anteroposterior view





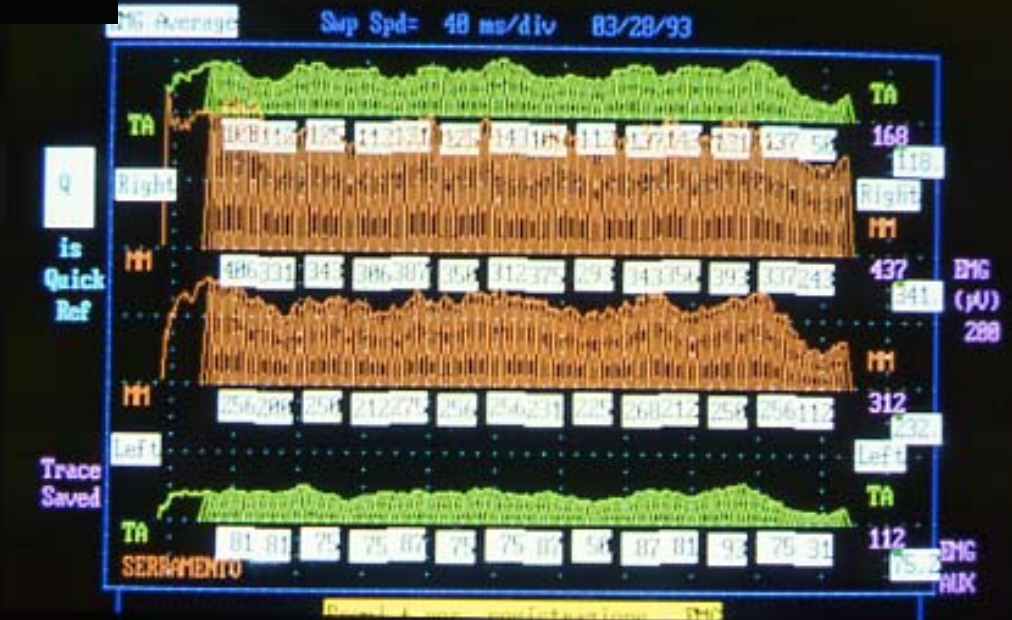


**ELETTROMIOGRAFIA-CHINESIOGRAFIA**



# TRACCIATO CHINESIOGRAFICO

# TRACCIATO ELETTROMIOGRAFICO



# Come...

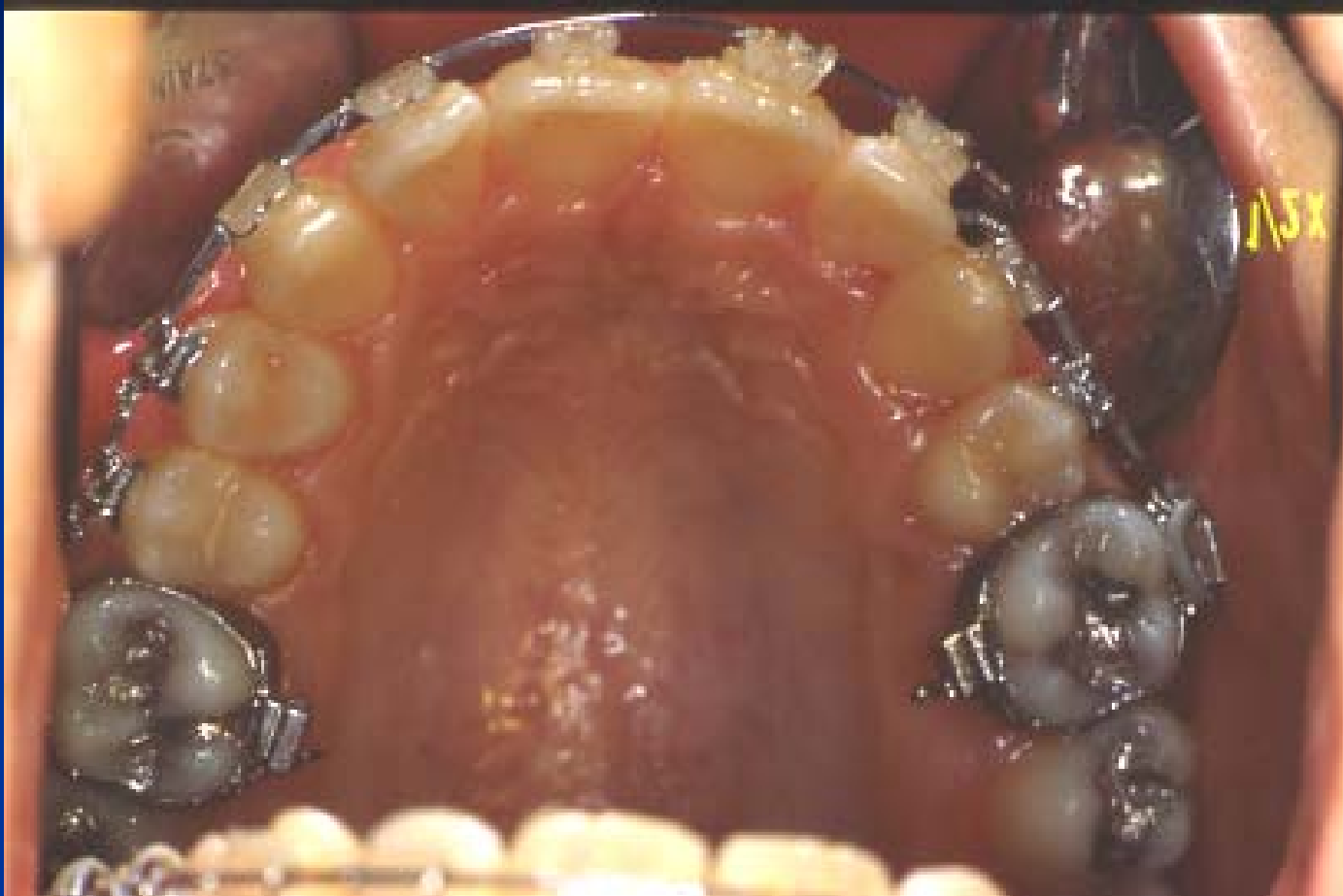## Apparecchiature:

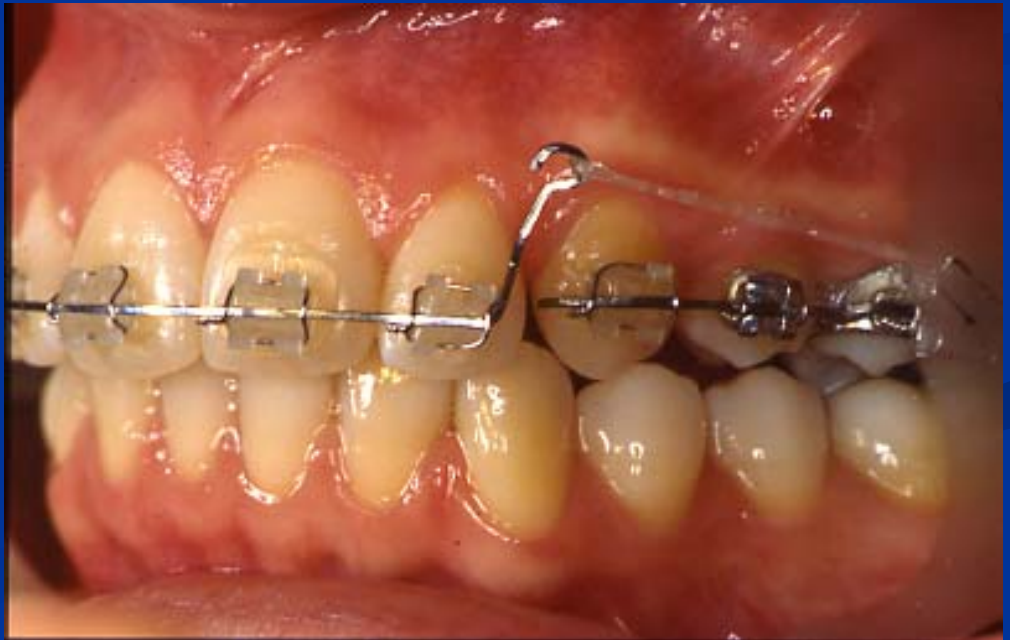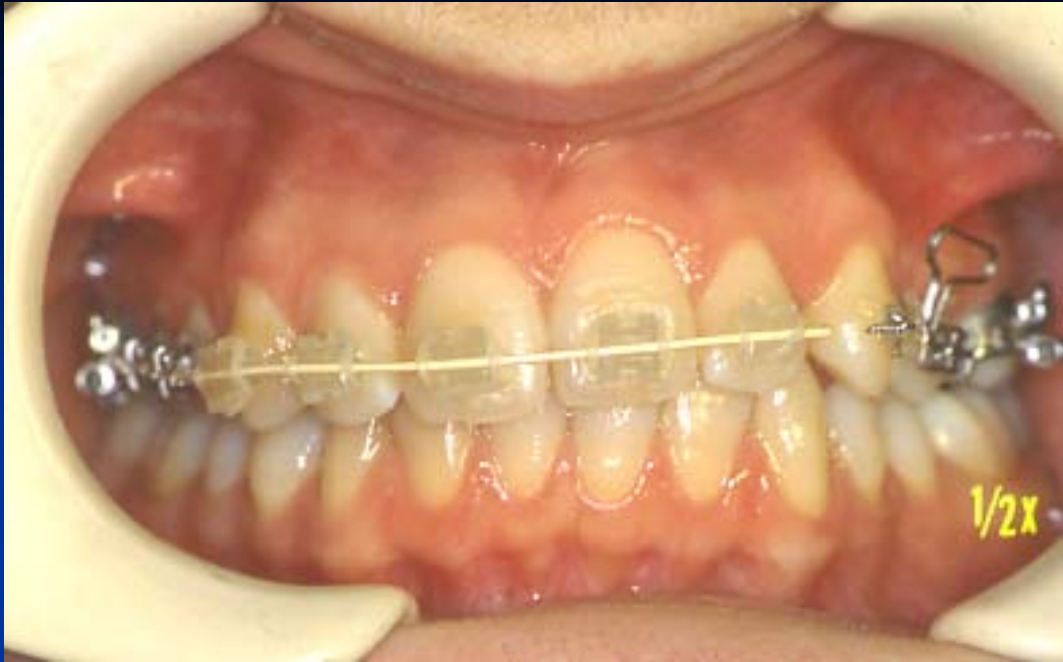- Fisse
- Rimovibili
- Miste

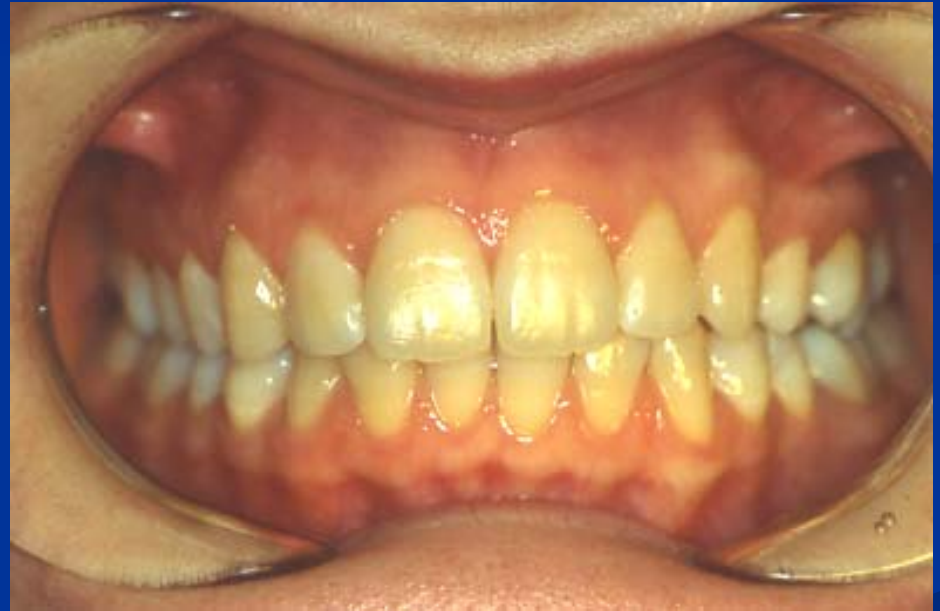Come...

## Apparecchiatura Fissa

- bande acciaio
- attacchi
  - acciaio
  - porcellana
- filo ortodontico





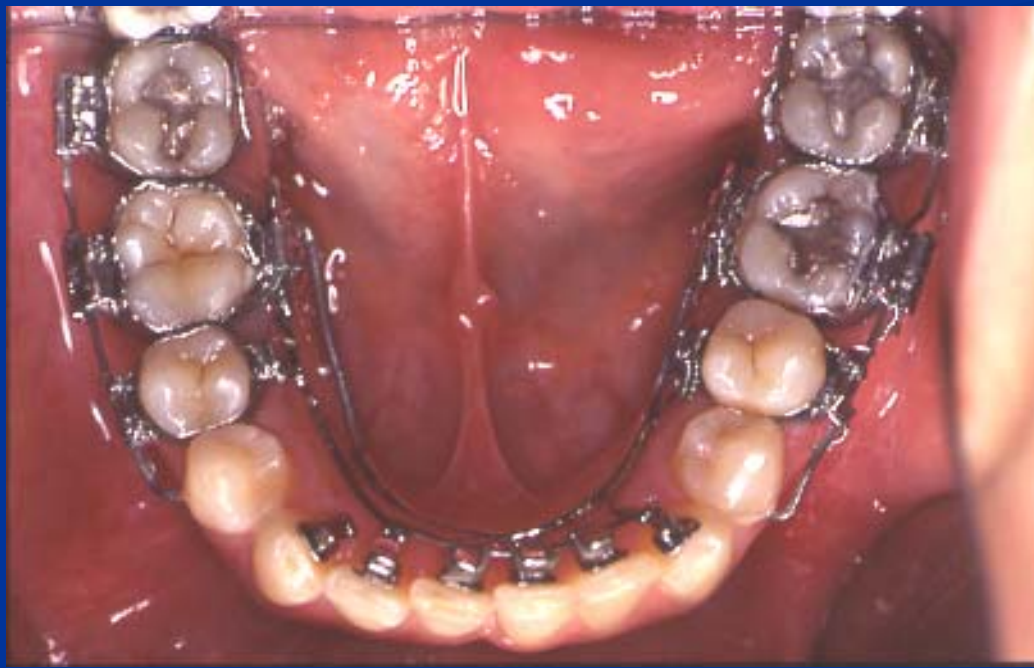
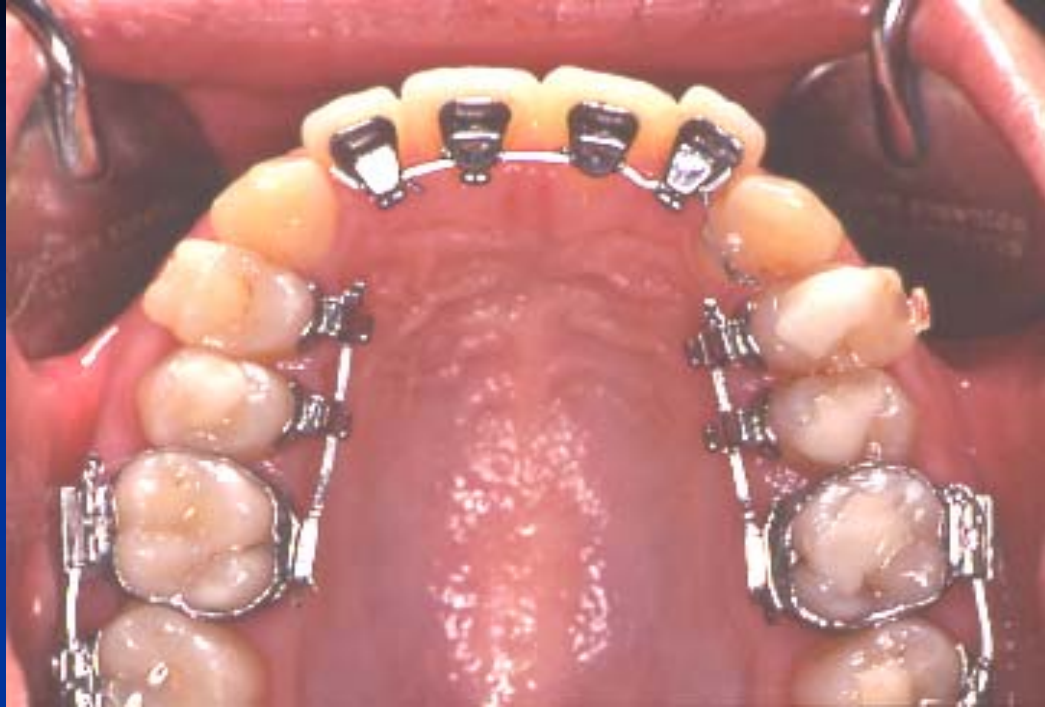
Come...

Apparecchiature fisse:

-attacchi linguali

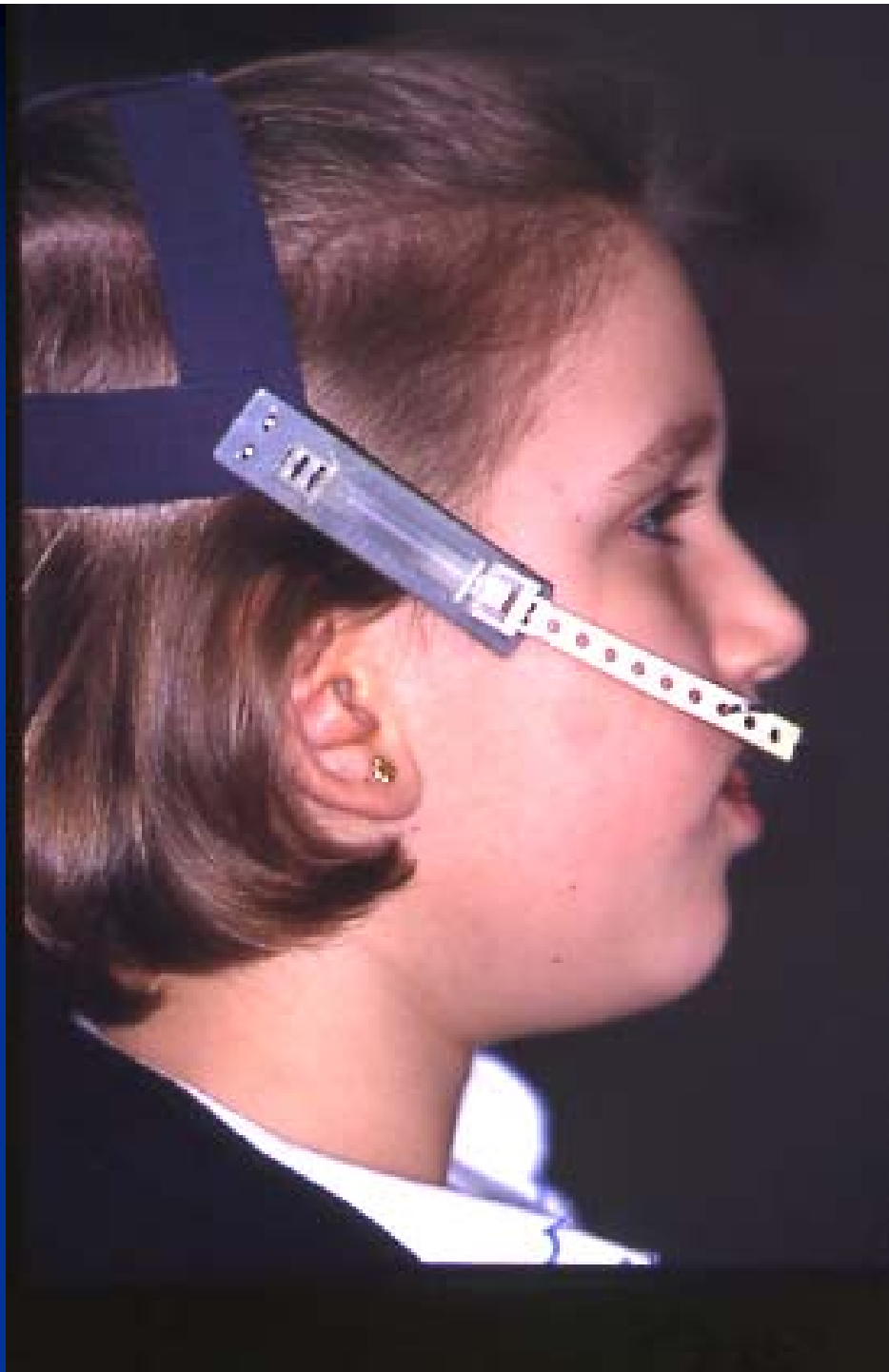


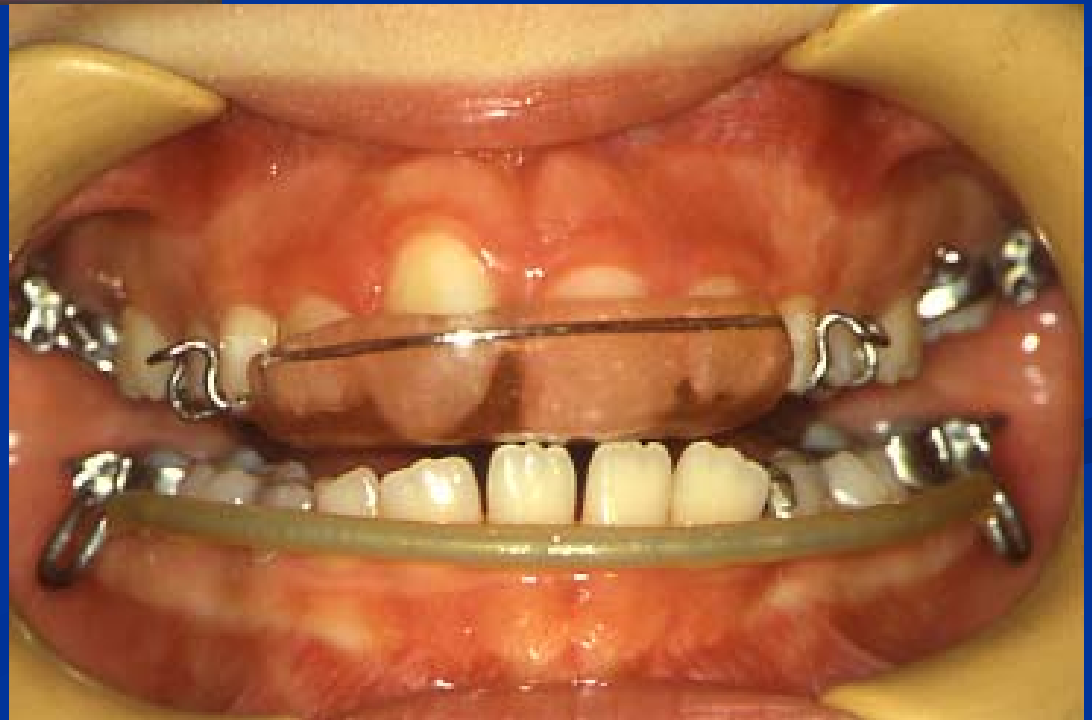
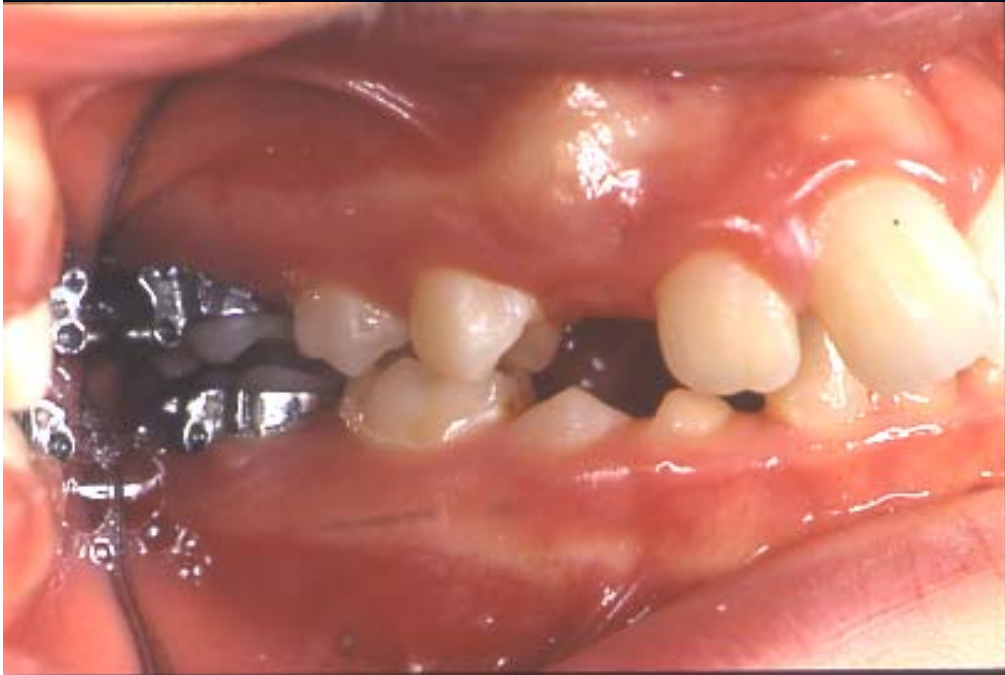
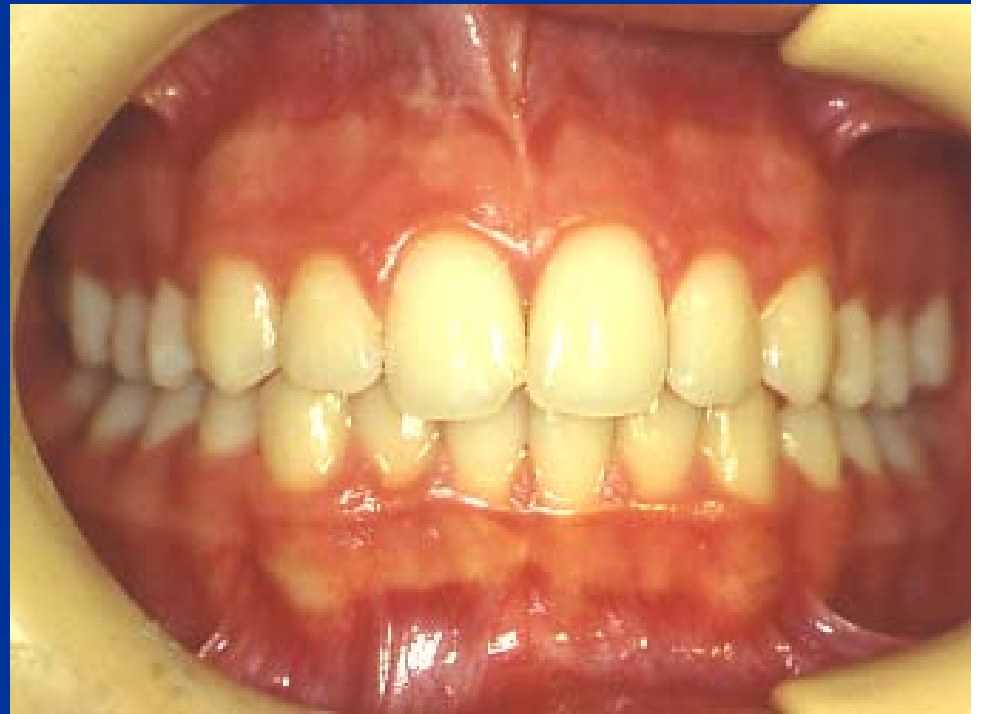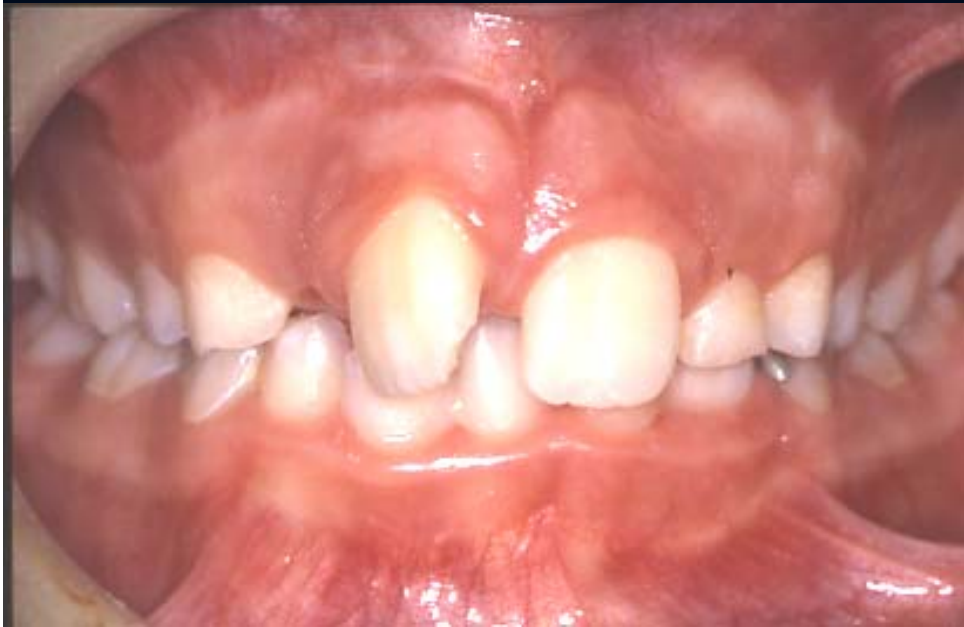Come...

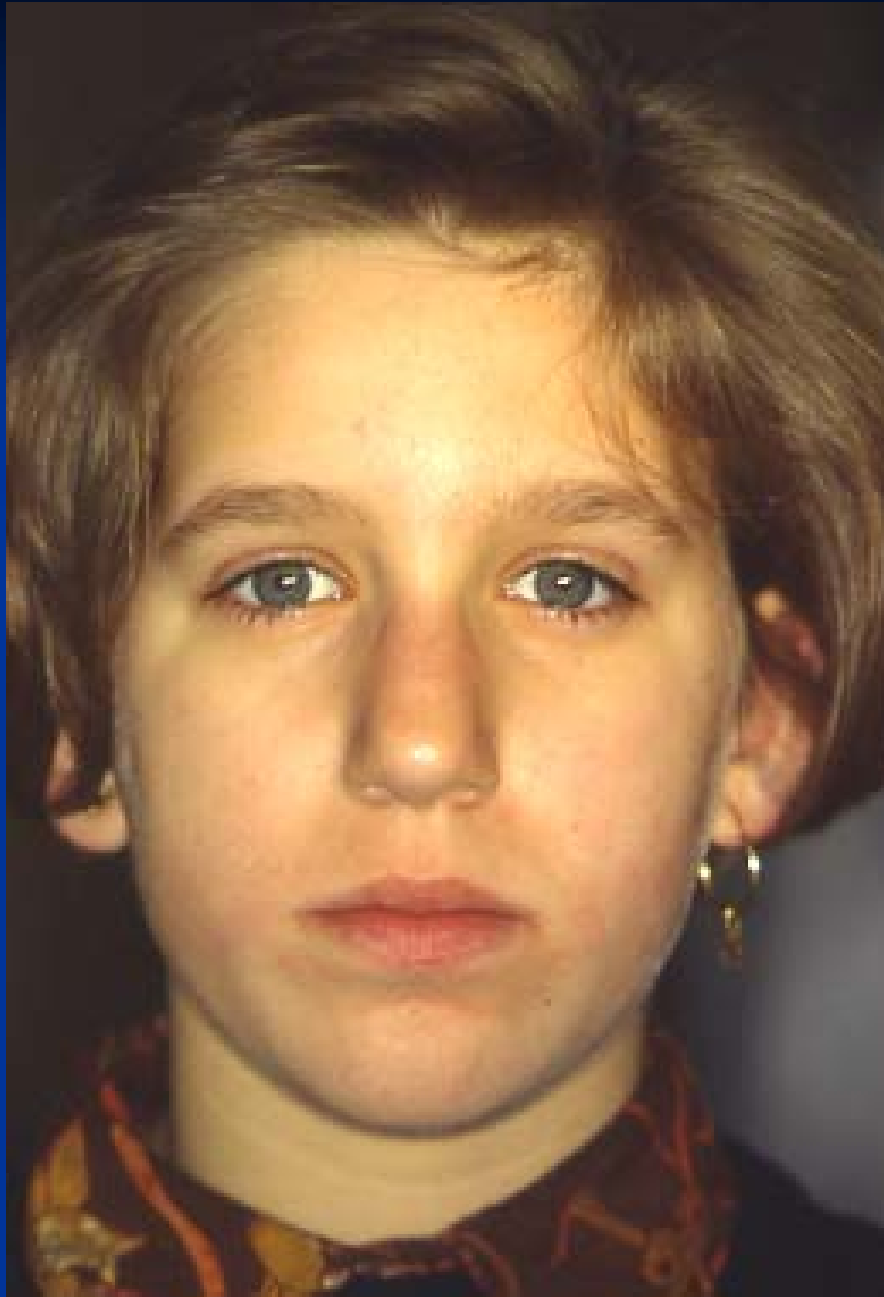Apparecchiature miste:

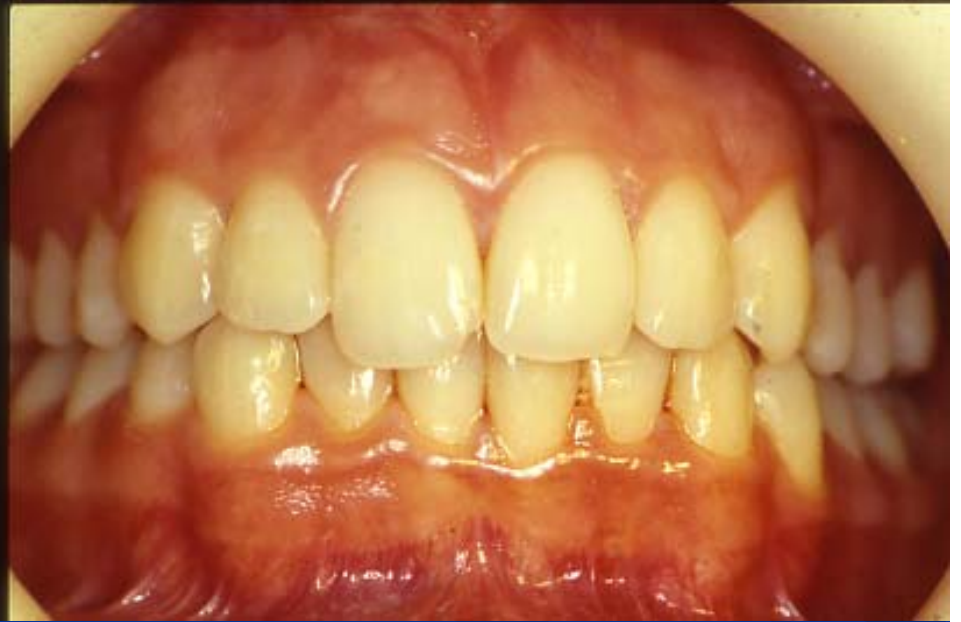-bande + trazione  
extraorale...







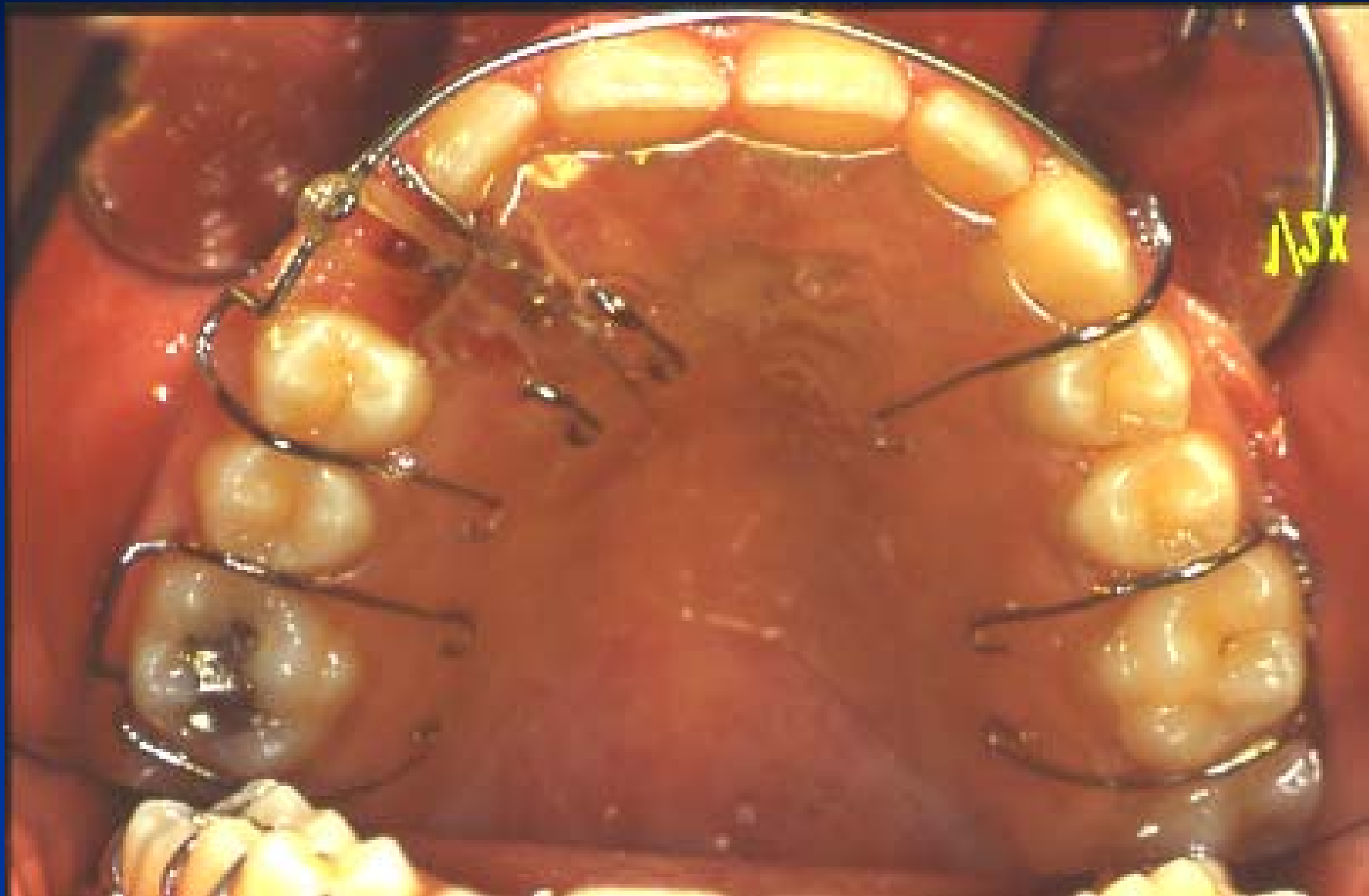


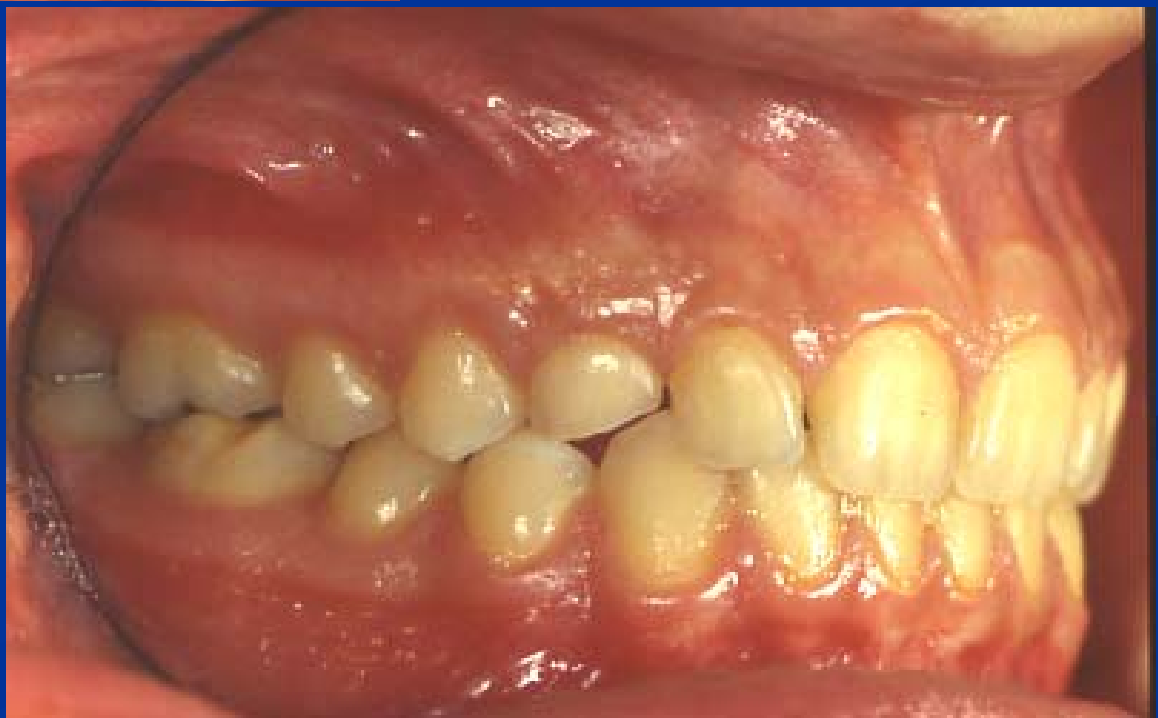
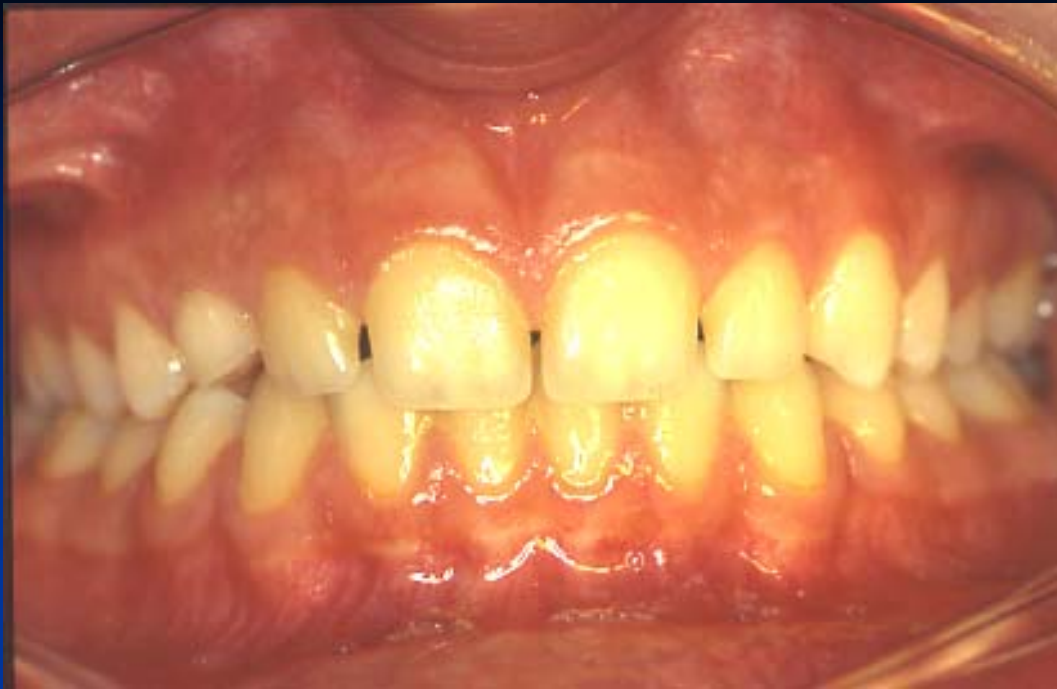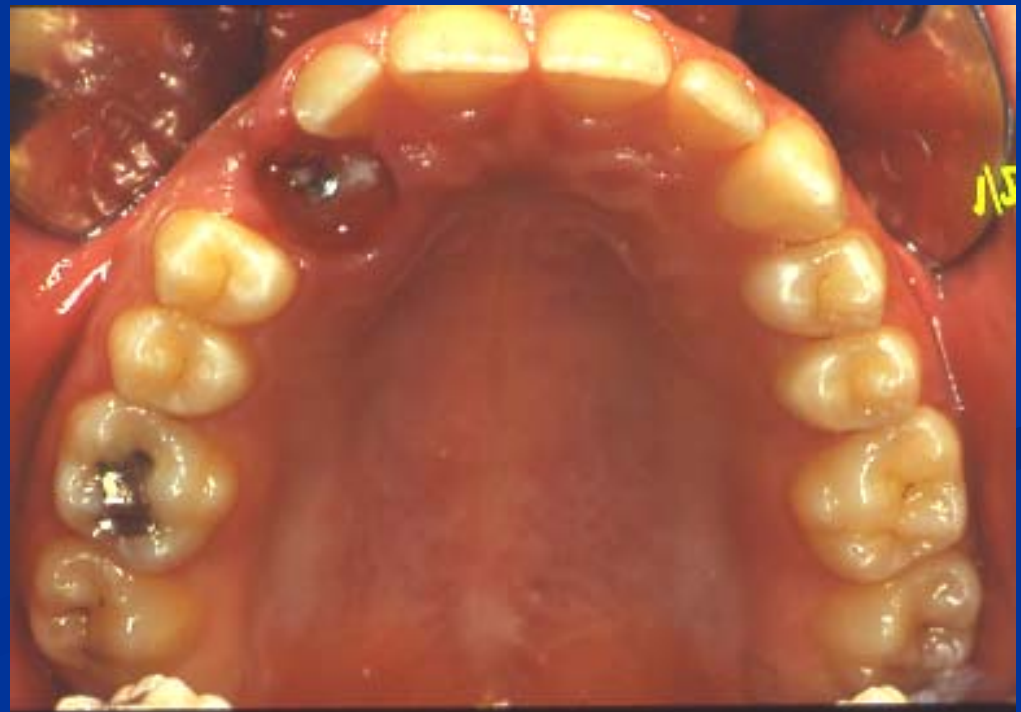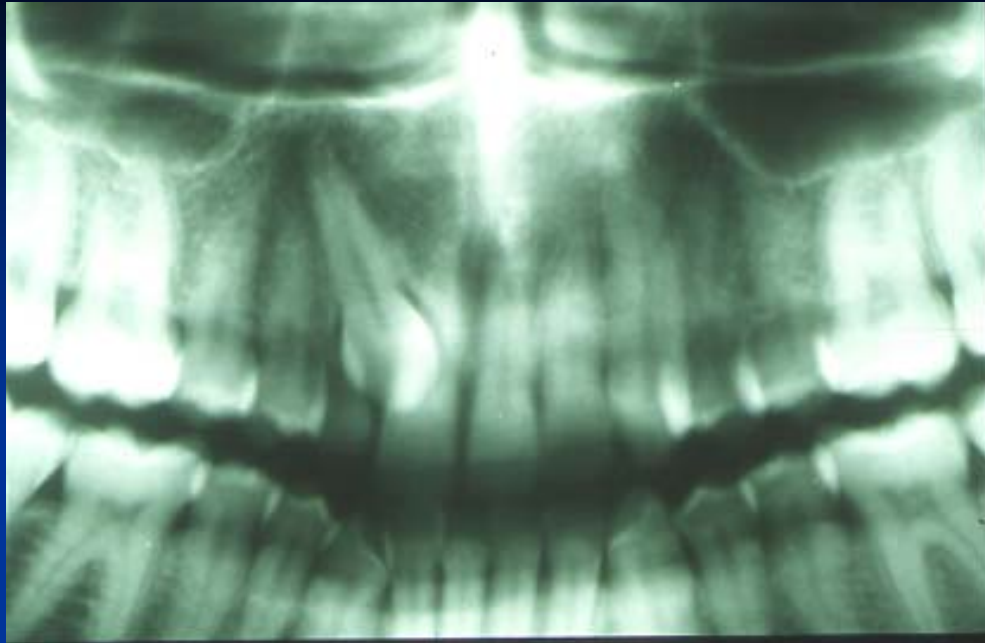
Come...

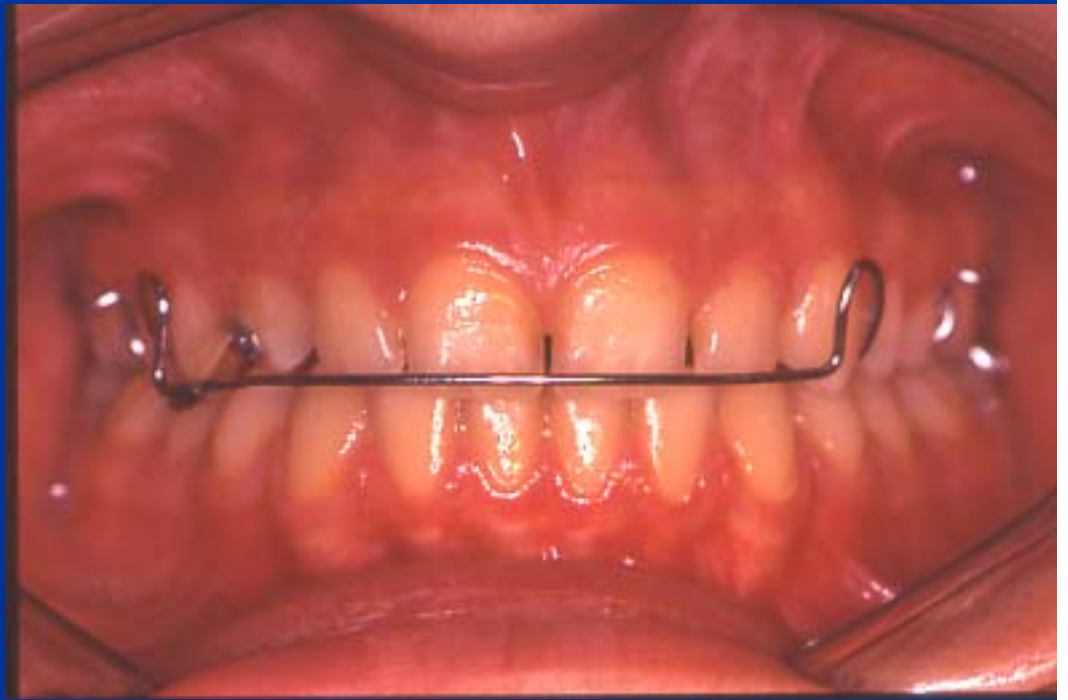
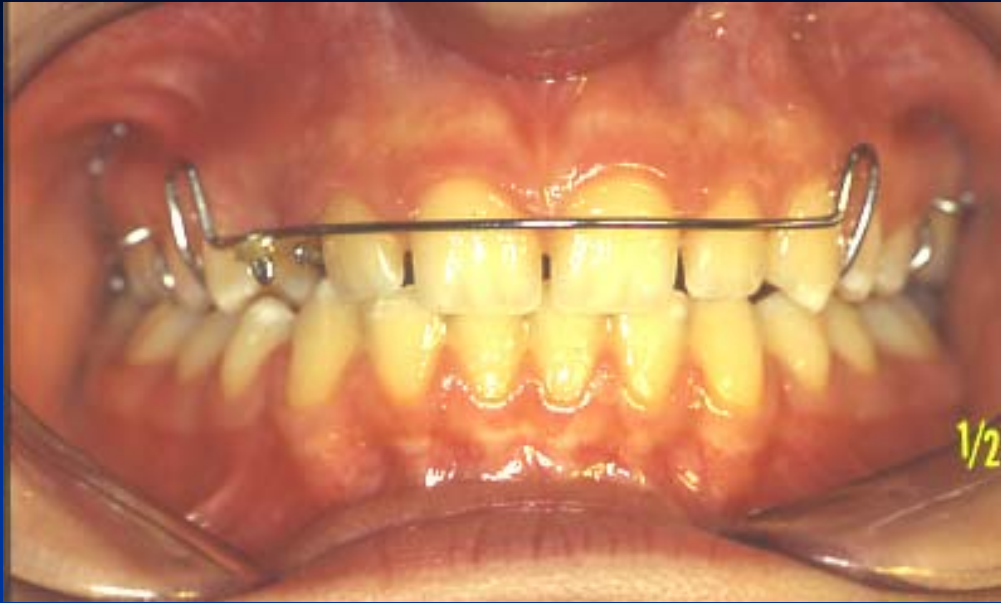Apparecchiature  
rimovibili:

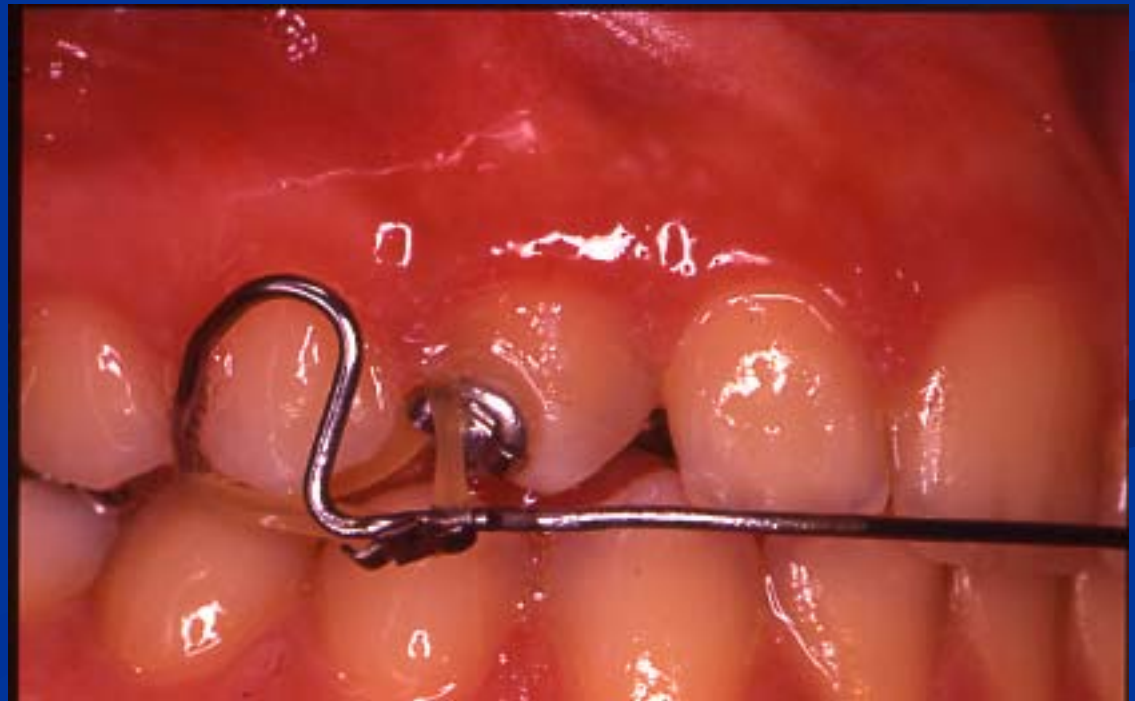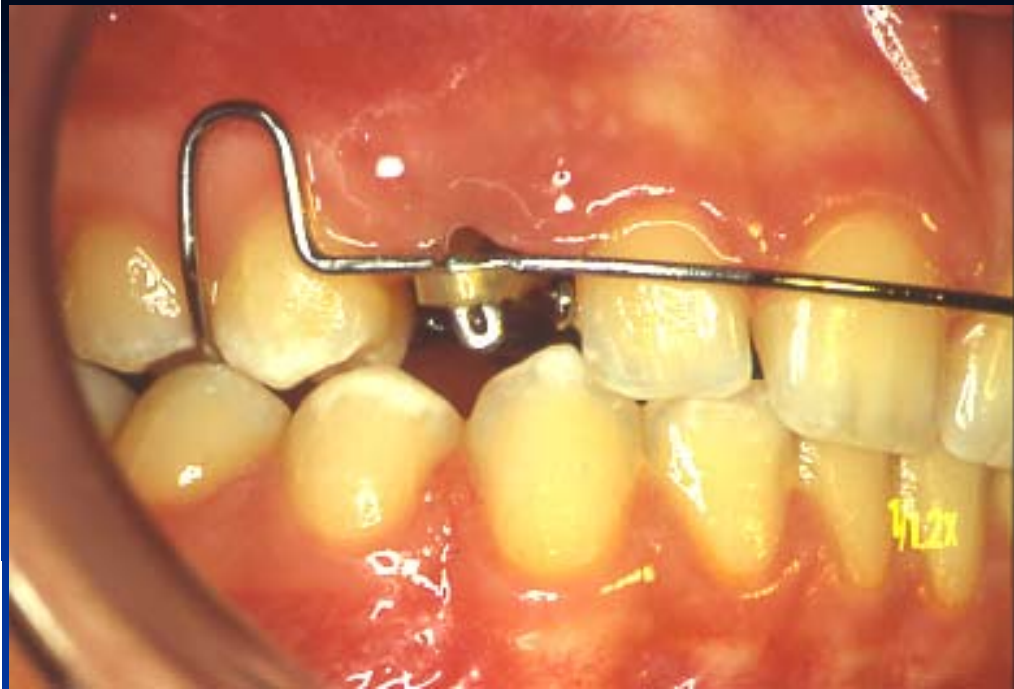-placca

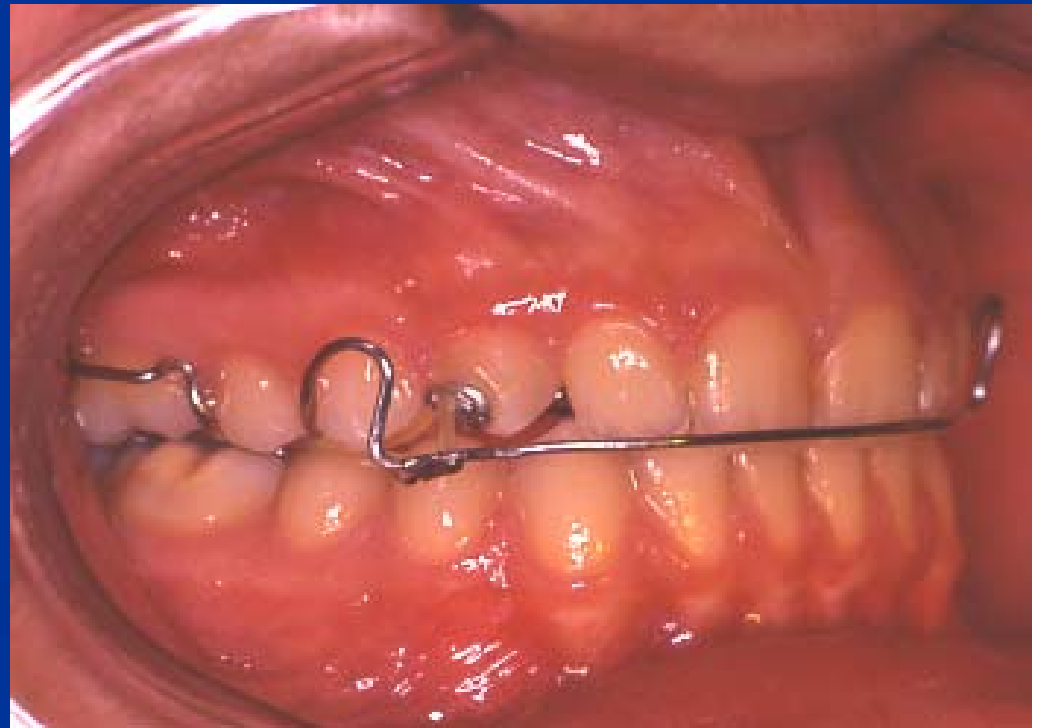
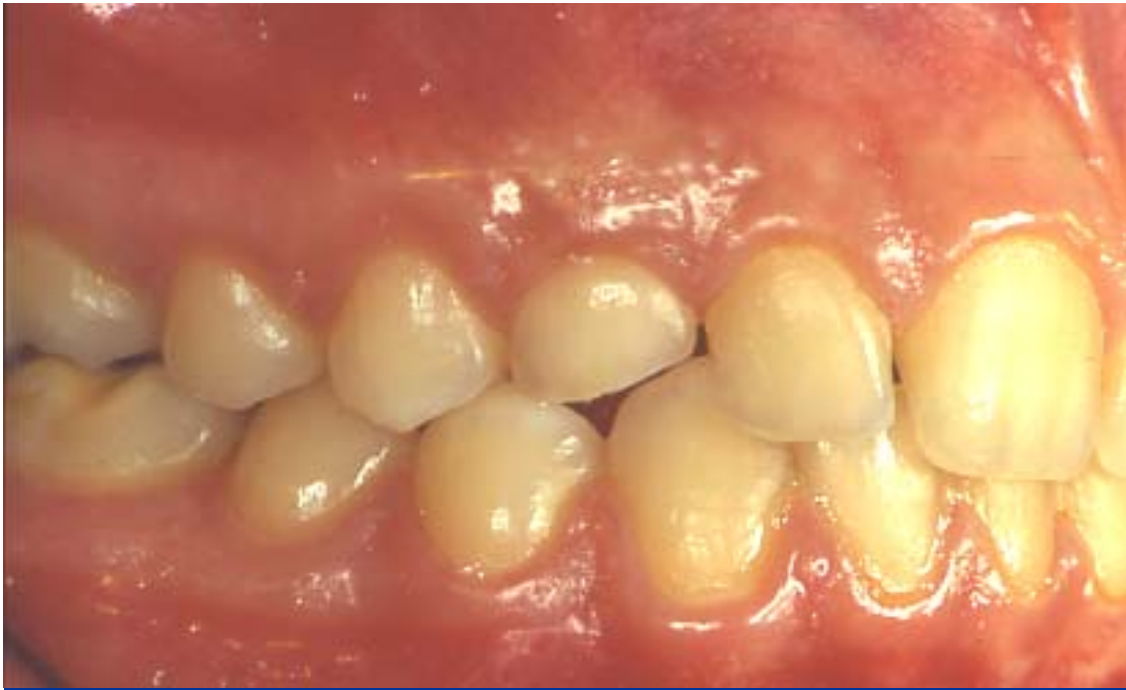






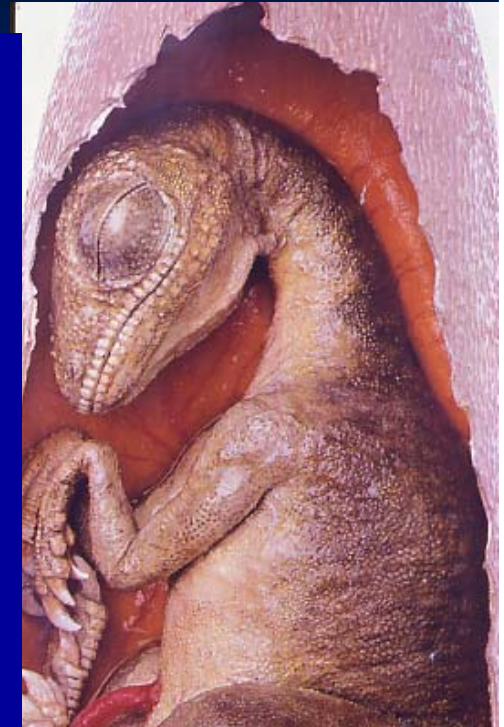




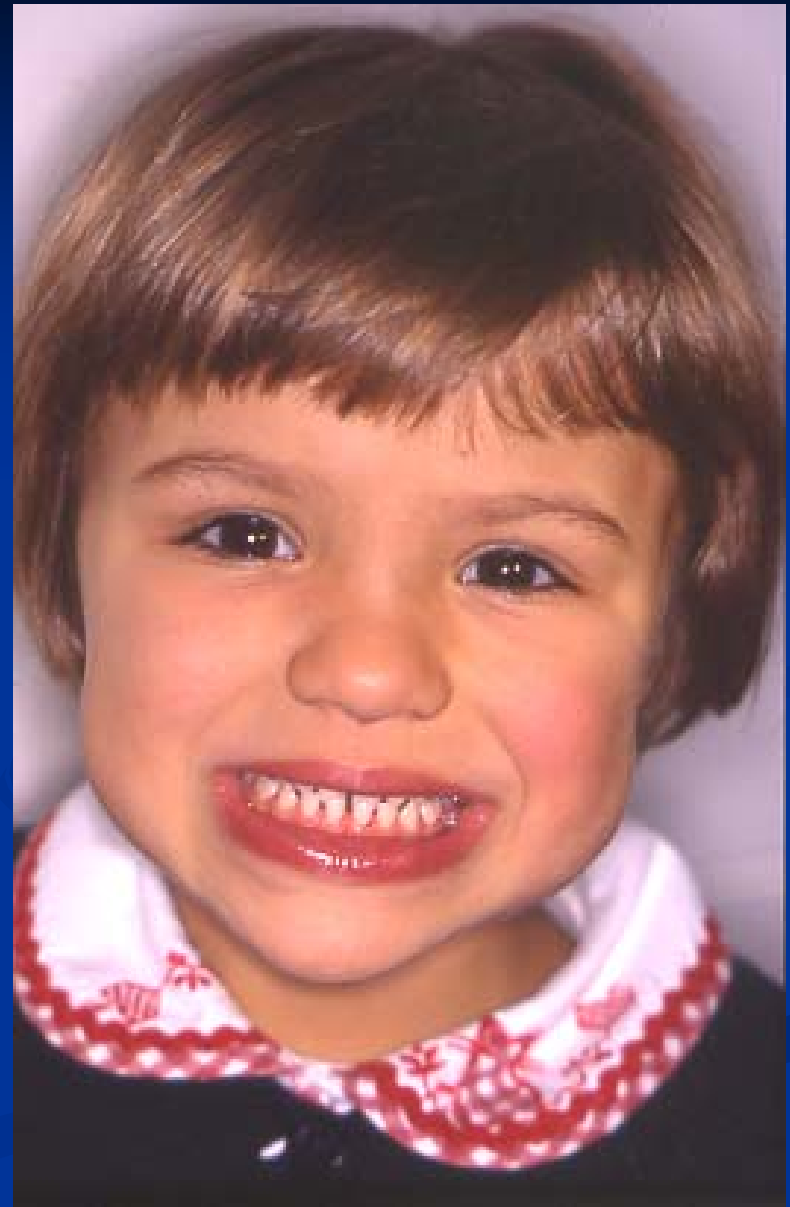# Quando...

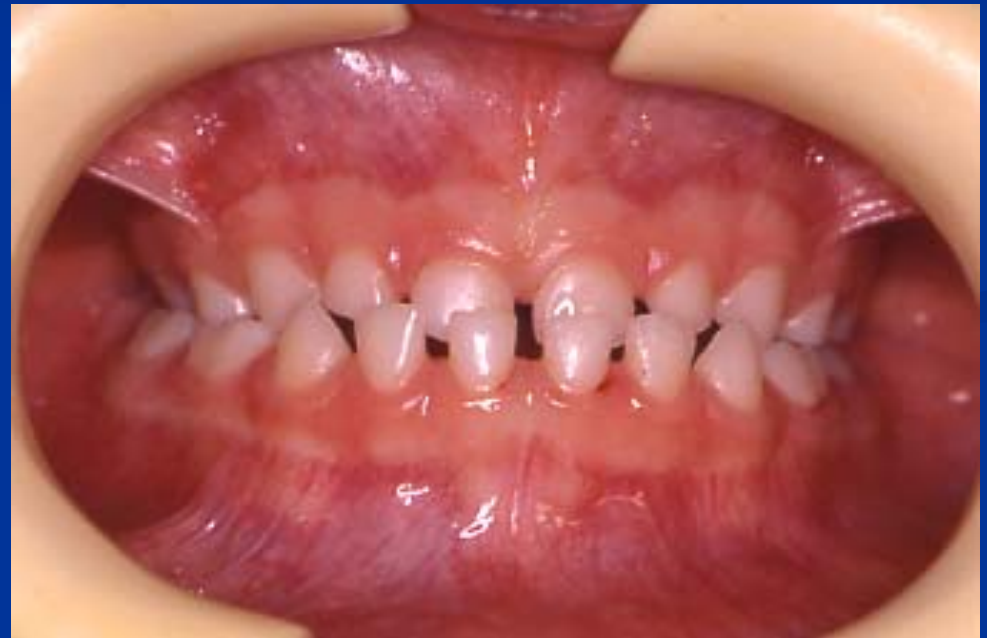- Precoce (4-7 anni)
- Dentatura mista (8-12 anni)
- Dent. Permanente (12-18 anni)
- Adulto ... e terza età



Quando...

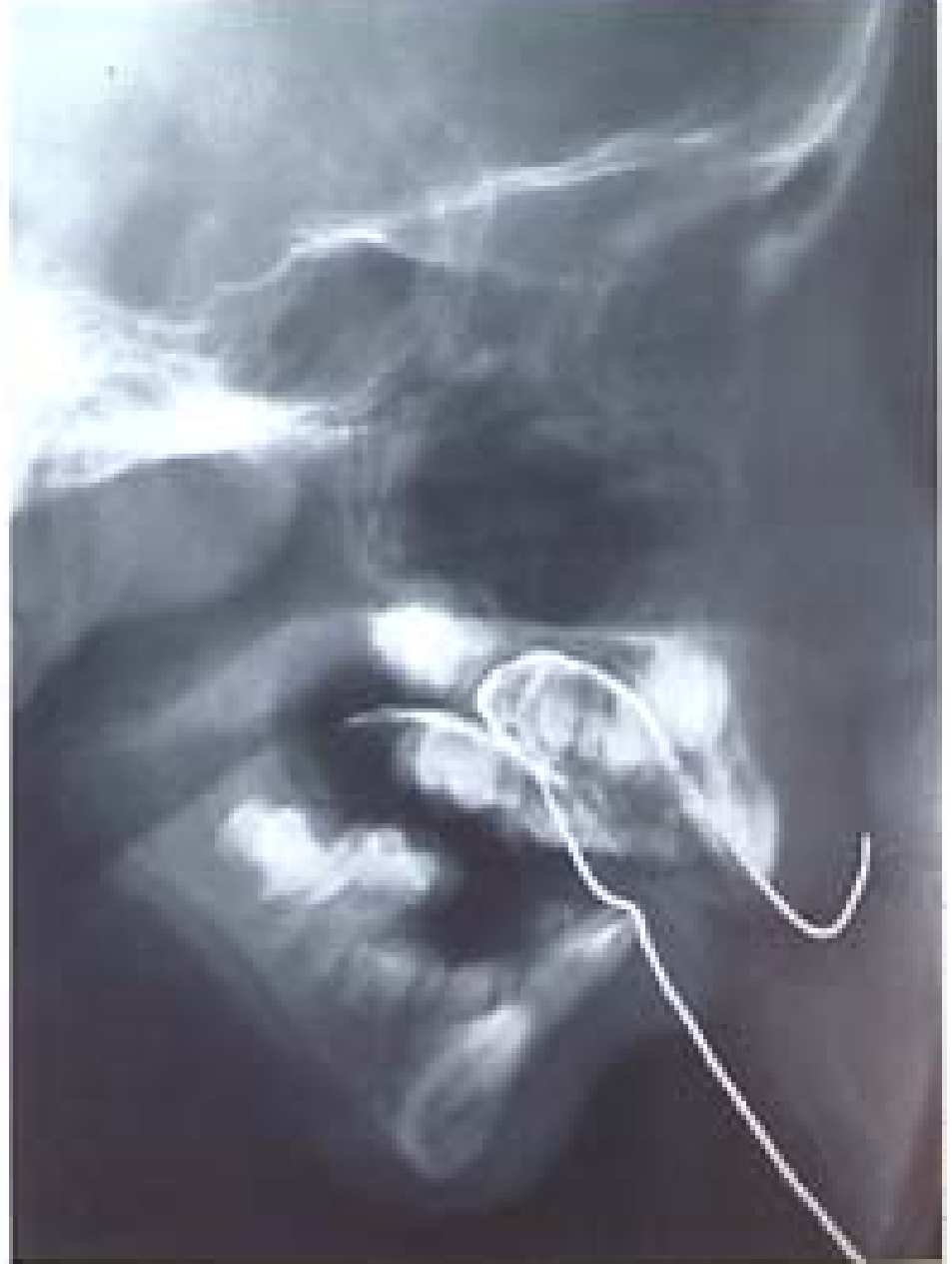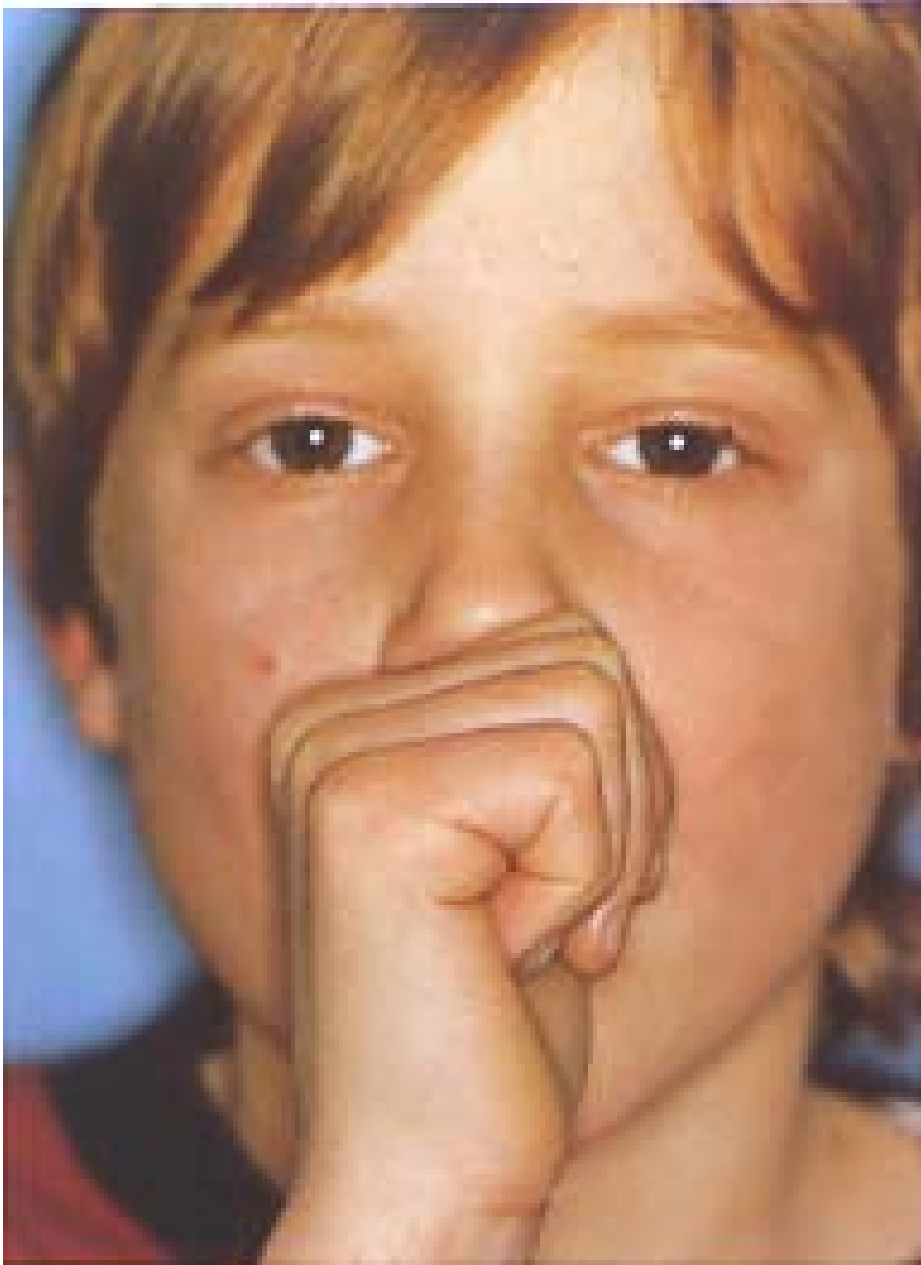-Precoce  
(in grave malocclusione)

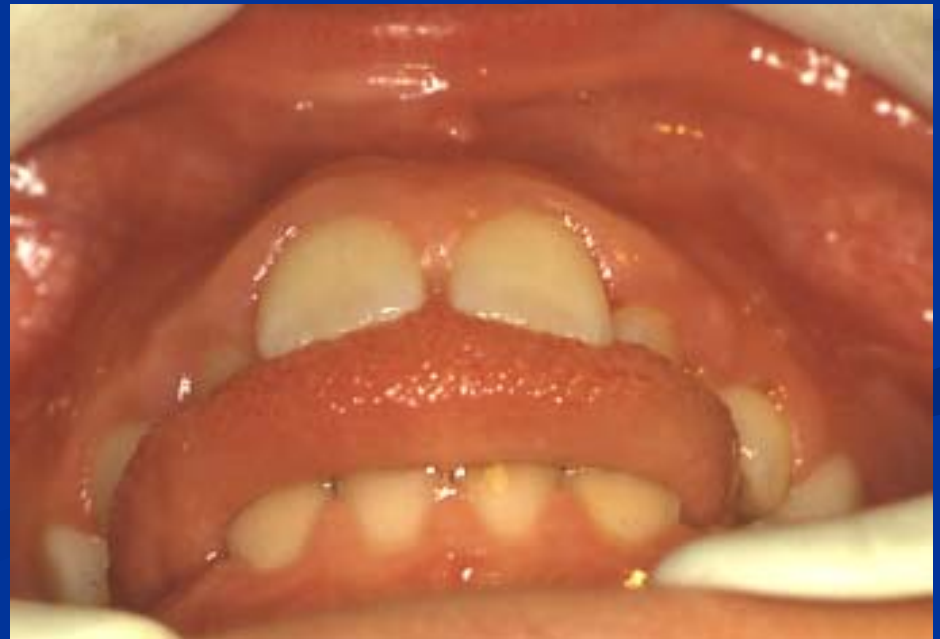
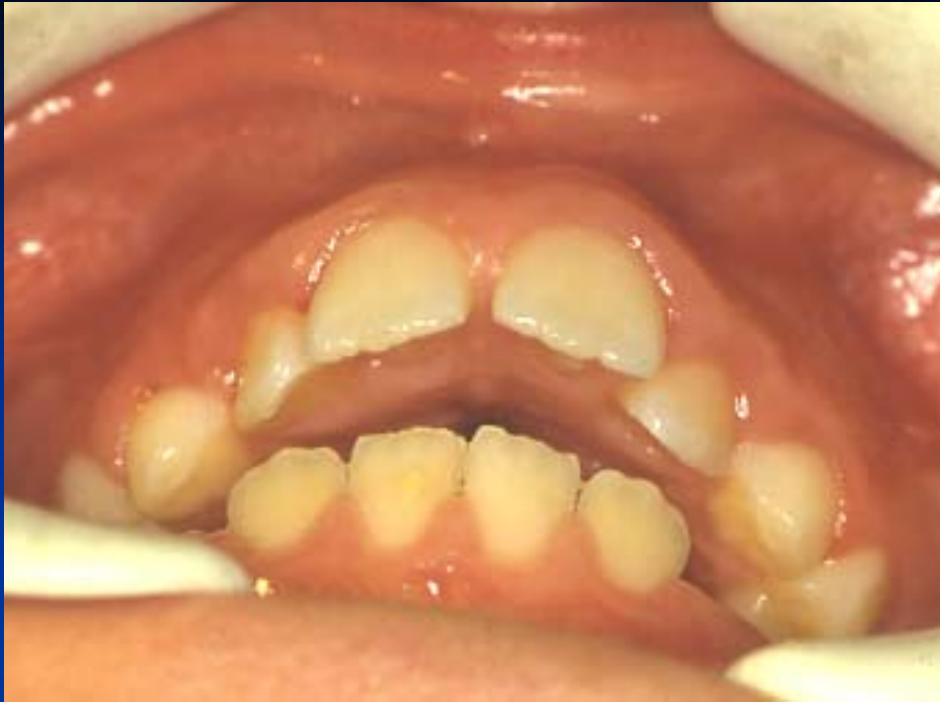


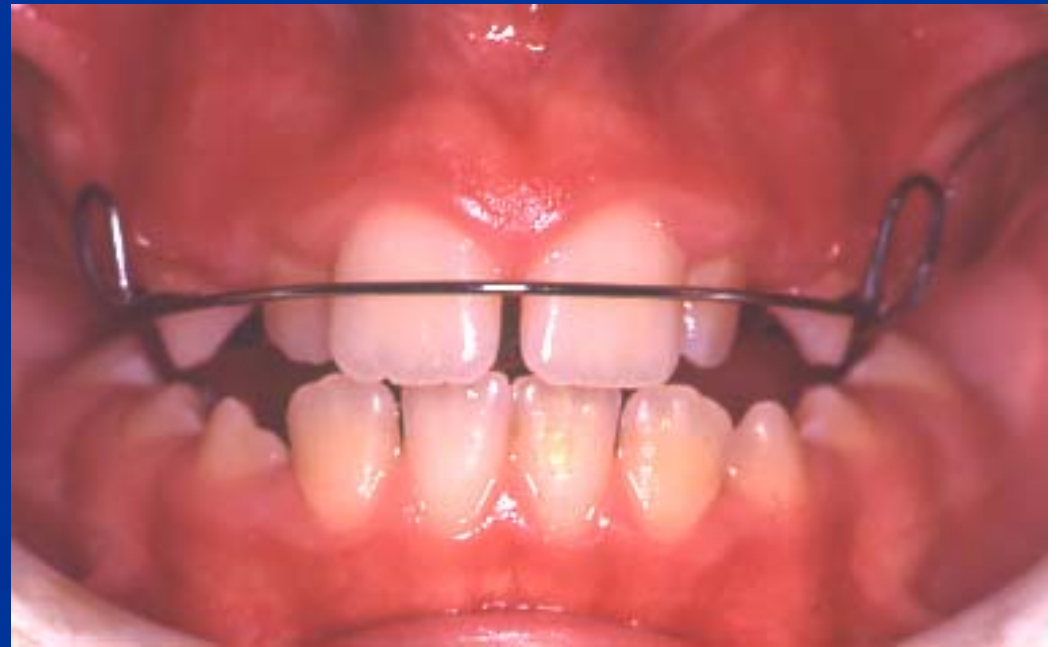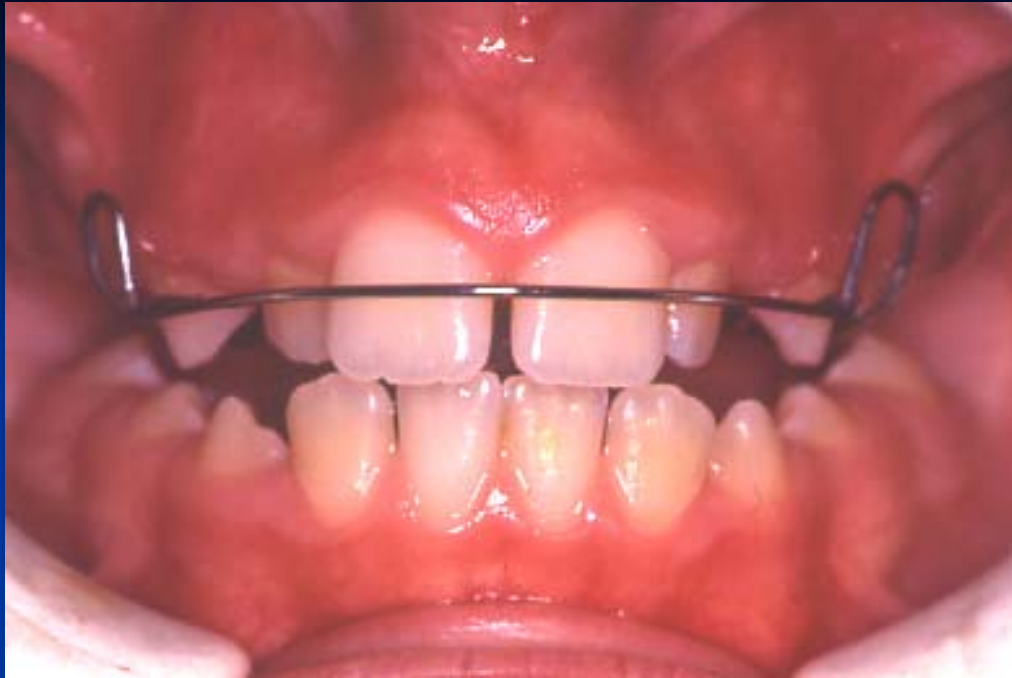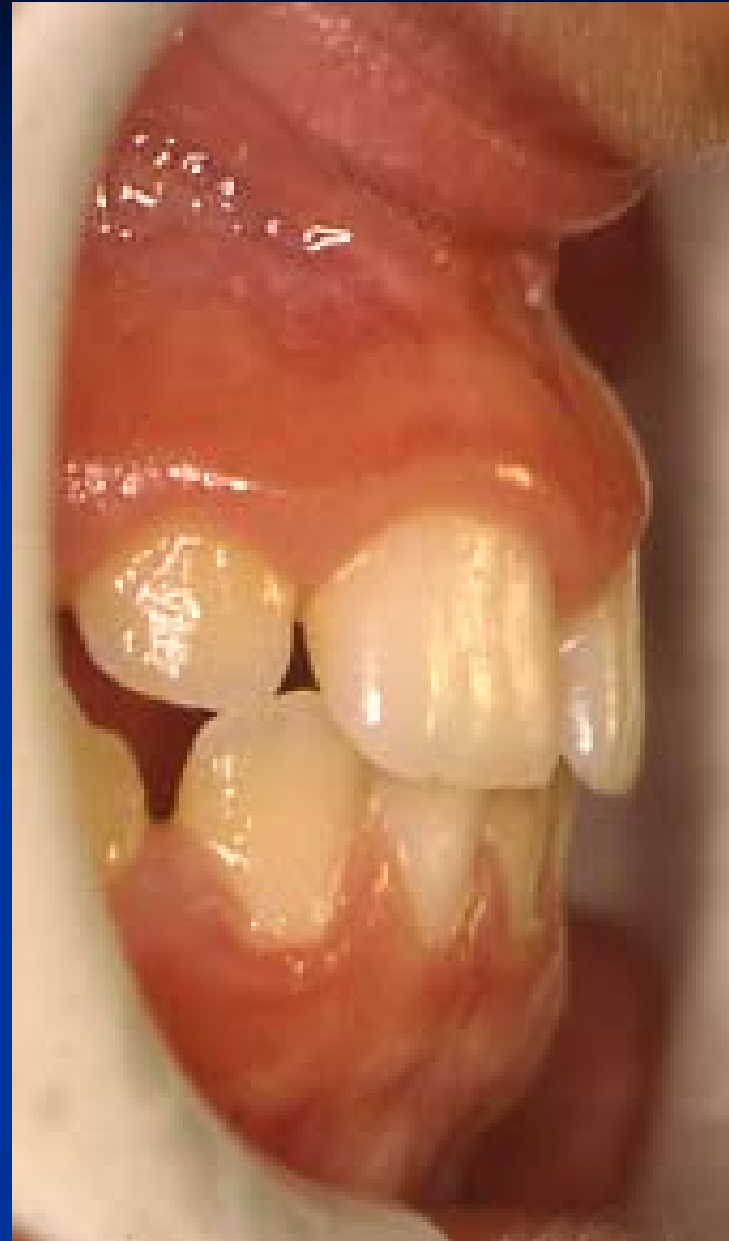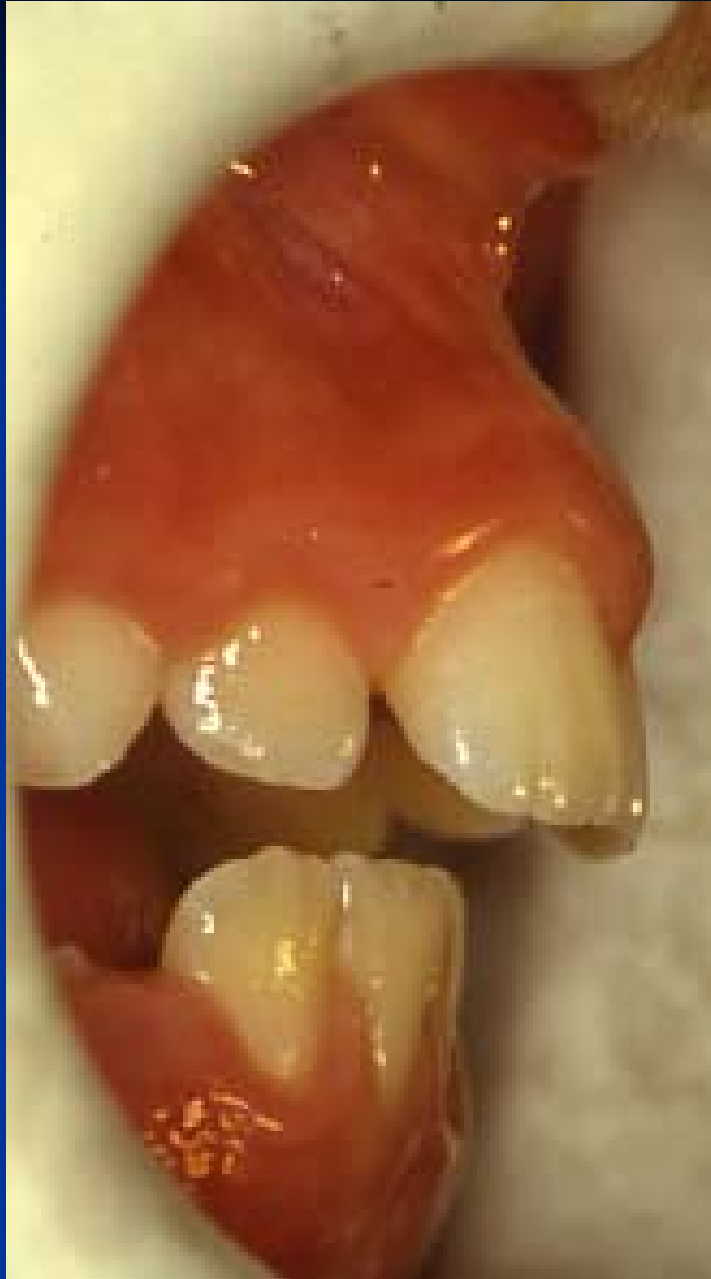# Quando...

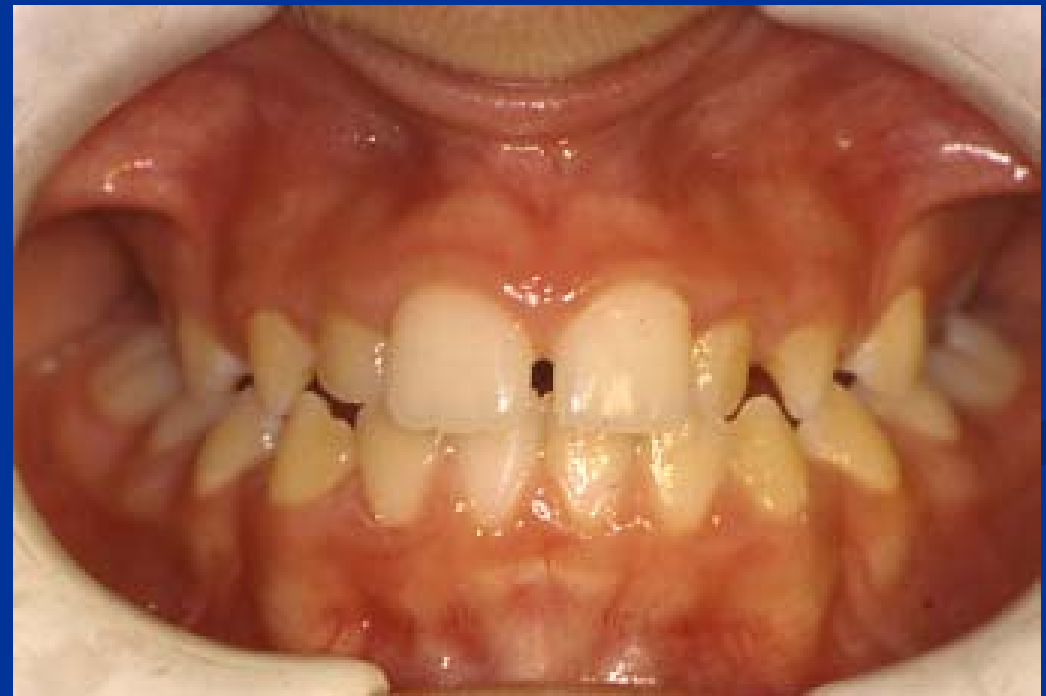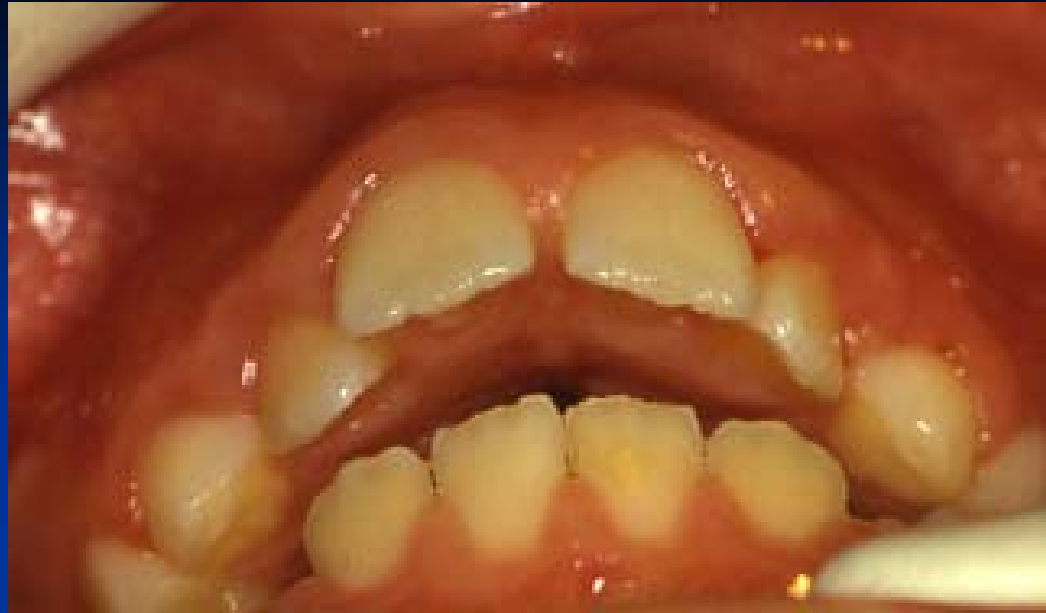- Intercettiva
- succhiamento pollice
- spinta linguale
- respirazione
- morsi incrociati

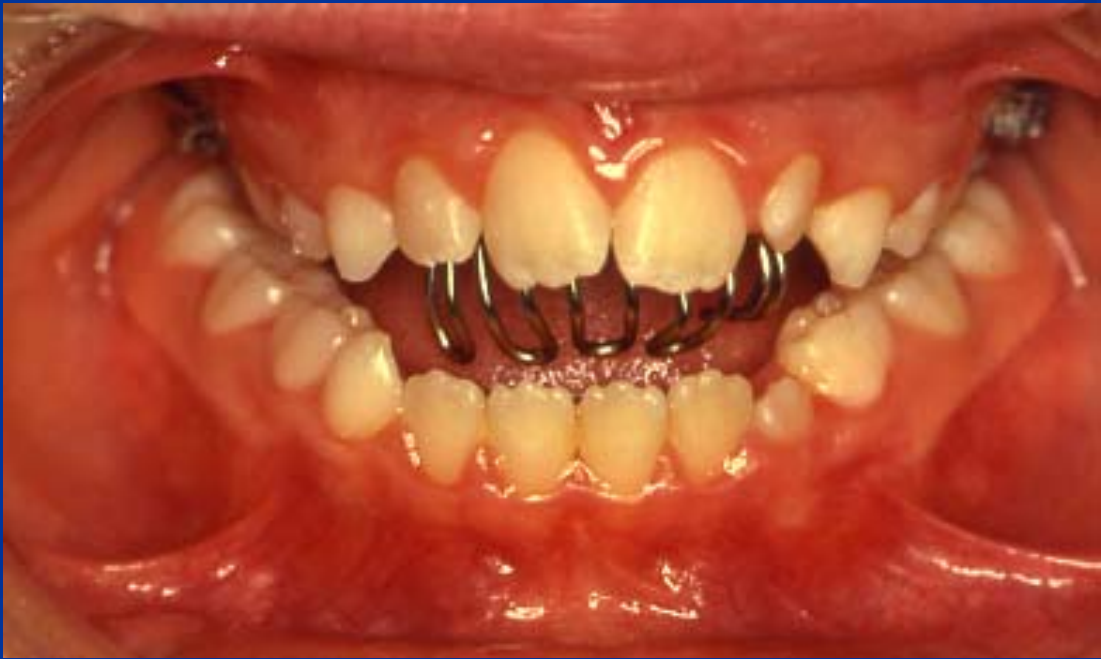
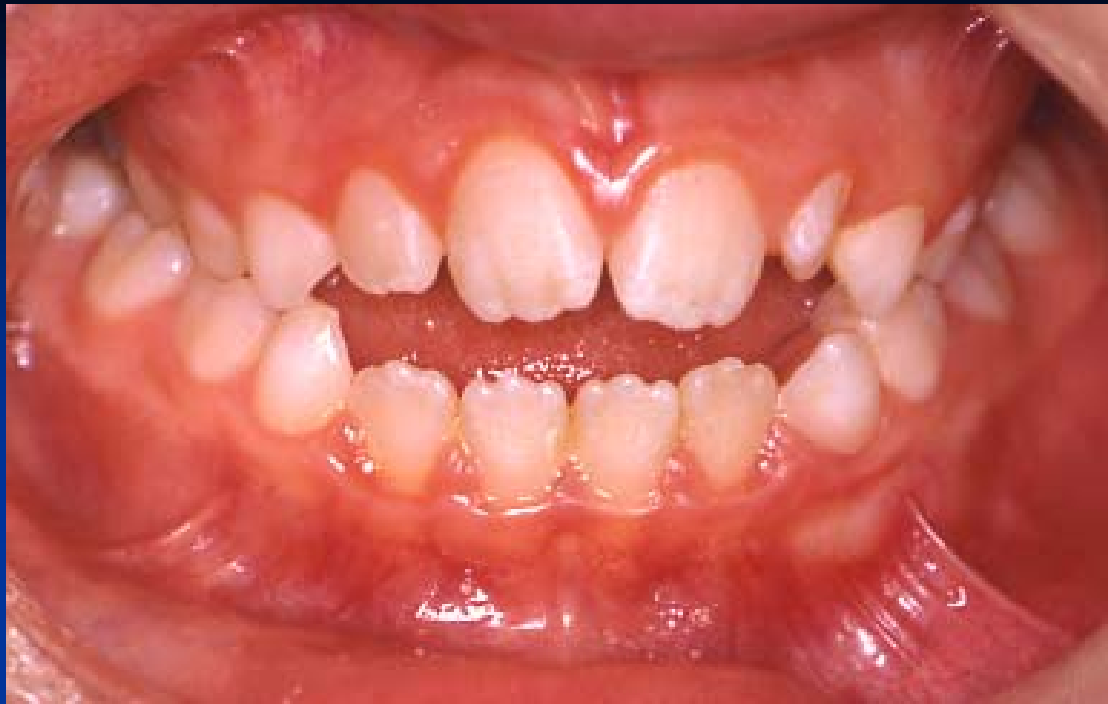

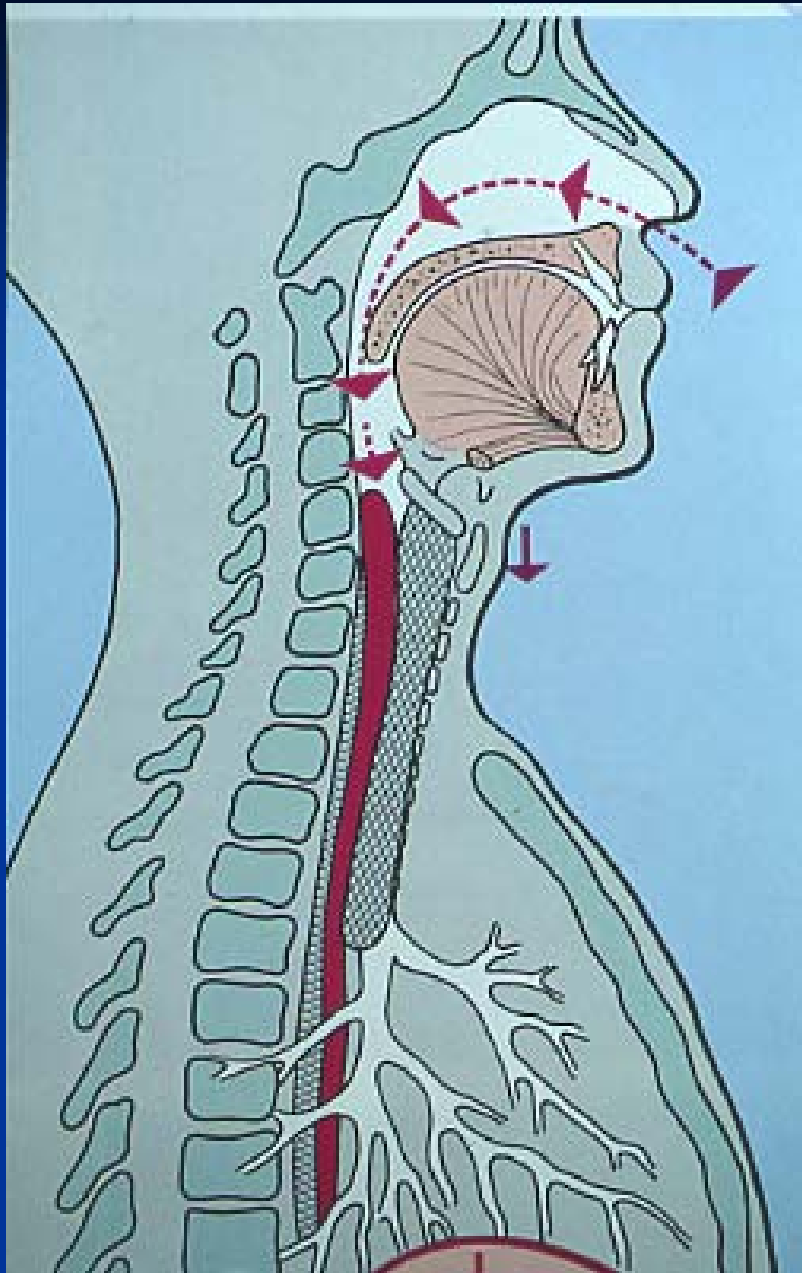










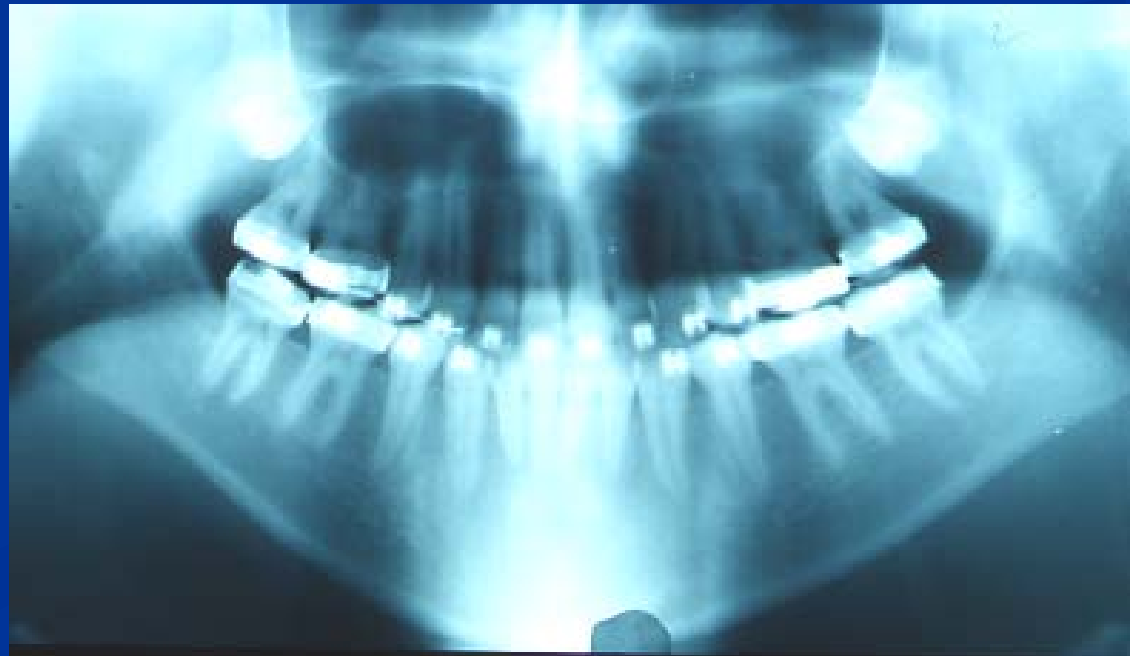

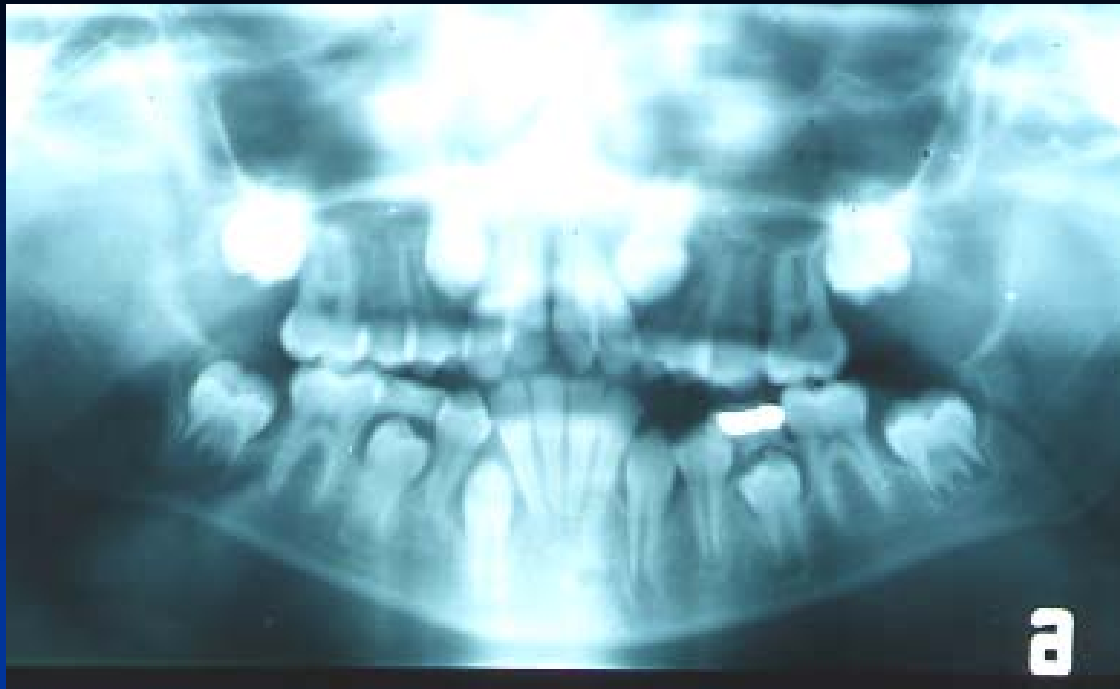
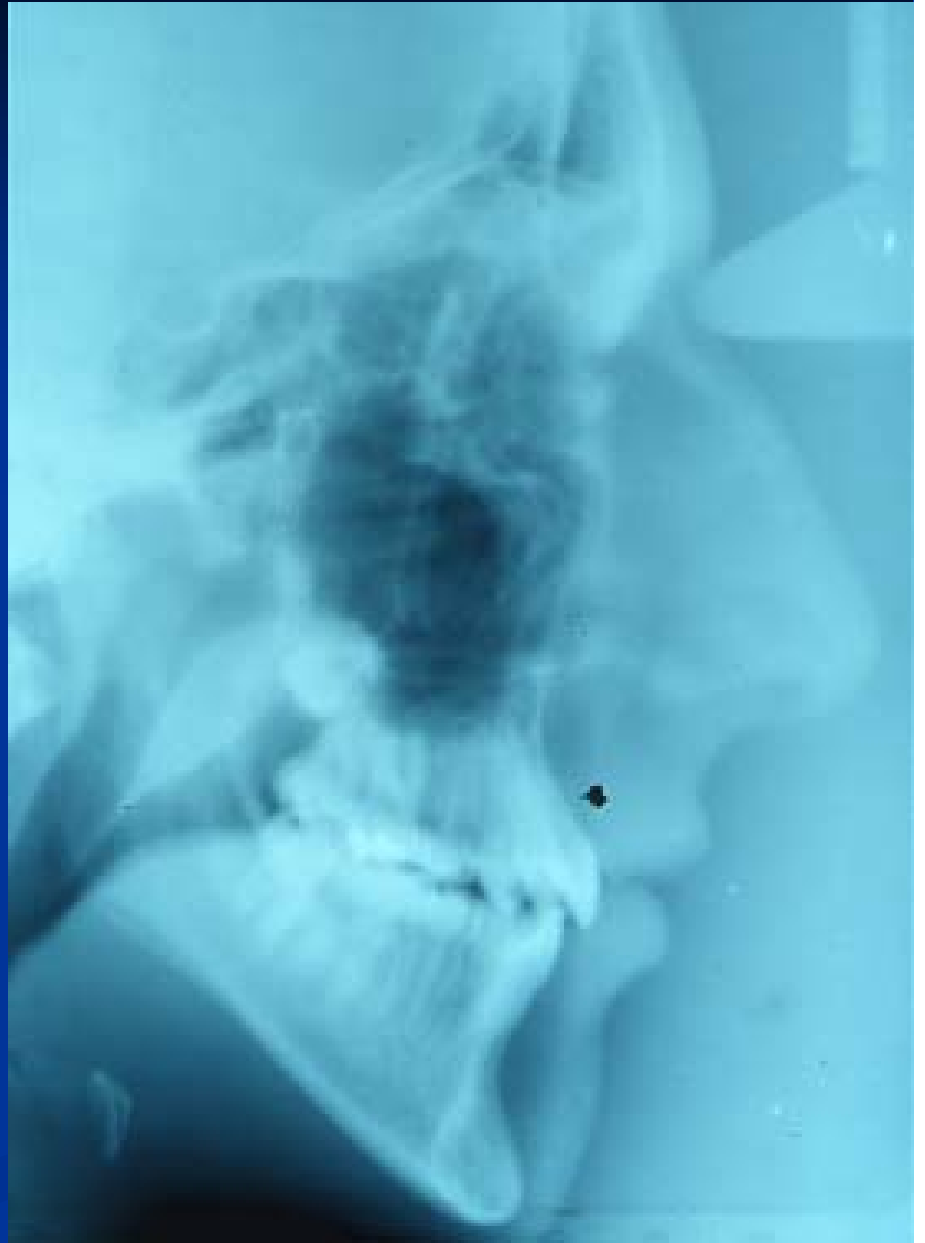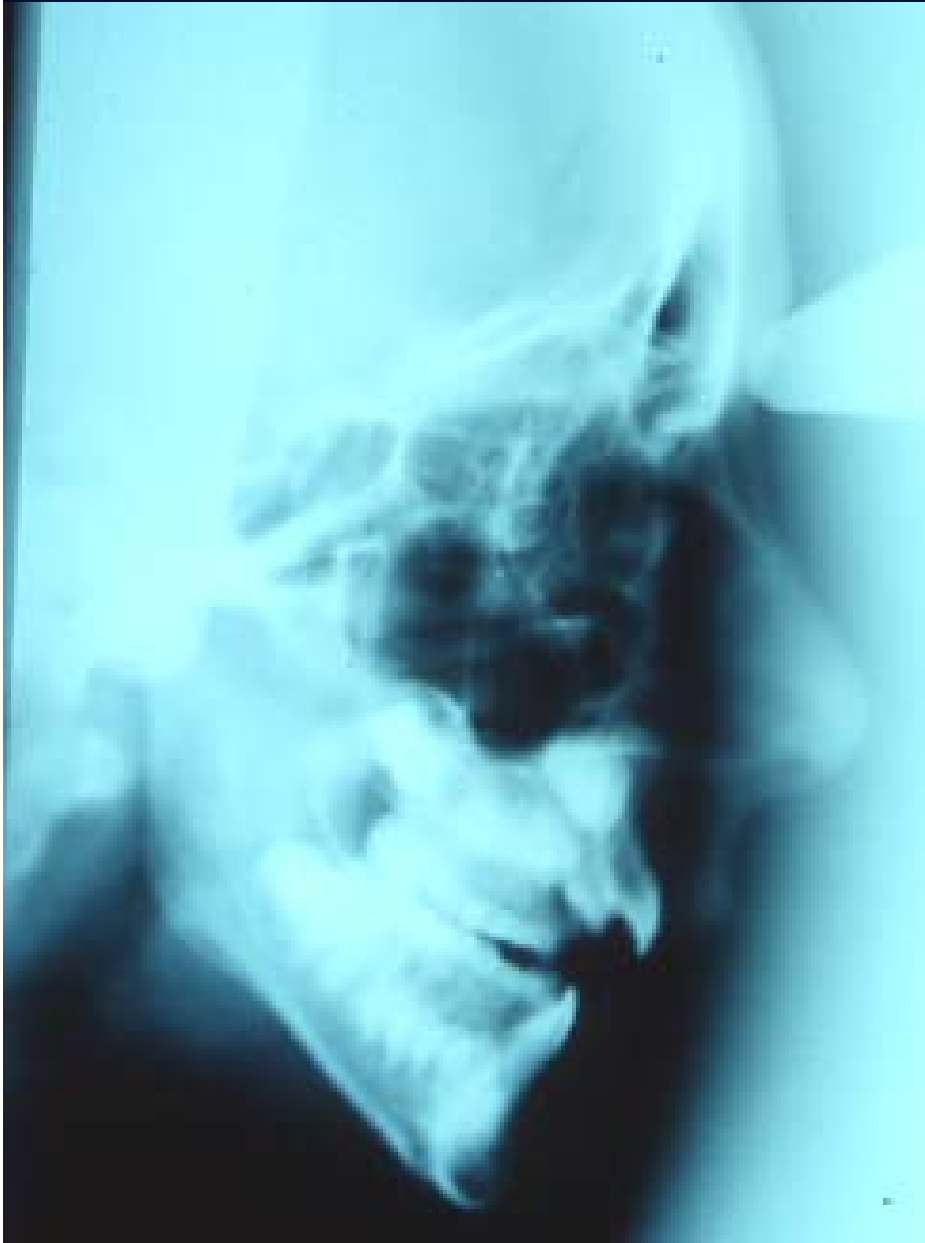## Caratteristiche della cd. (Facies Adenoidea)

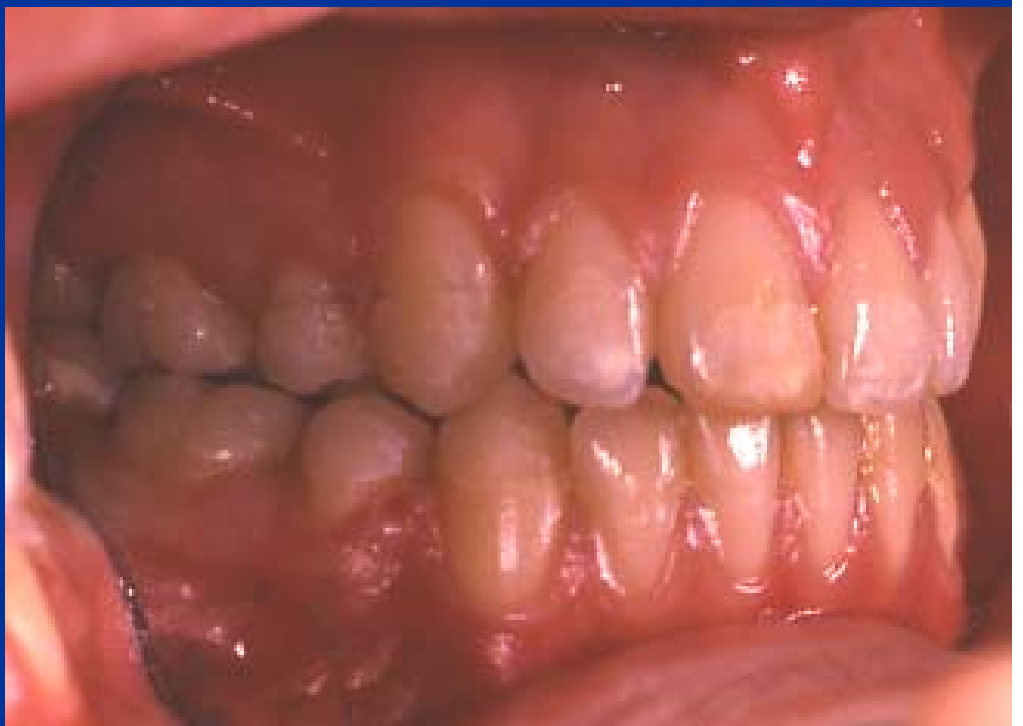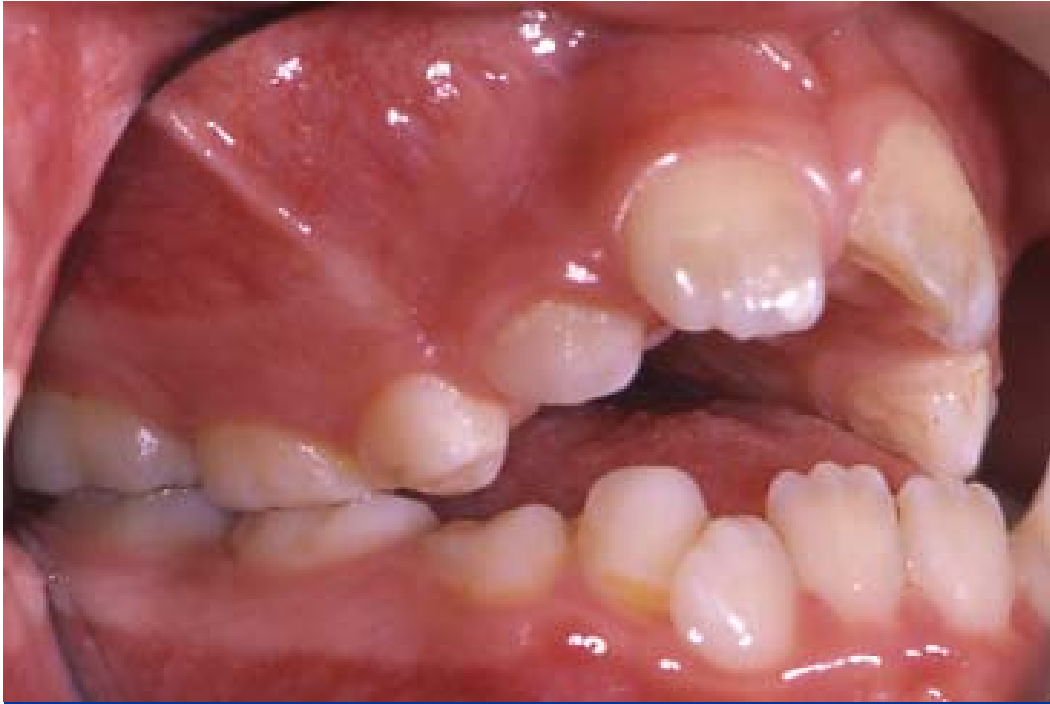- FACCIA LUNGA E STRETTA
- INESPRESSIVITA' DEL VISO
- IPOTONO DELLA MUSCOLATURA FACCIALE
- NASO PICCOLO E A SELLA CON NARICI IPOTONICHE
- LABBRA FLACCIDE SECCHIE E SCREPOLATE CON LABBRO SUPERIORE CORTO ED INCOMPETENTE (che lascia scoprire i denti) E LABBRO INFERIORE SPESSO ED EVERSO
- FREQUENTI GENGIVITI E CARIE DENTALI
- ARCATA MASCELLARE STRETTA ED AFFOLLATA CON TENDENZA AL MORSO CROCIATO
- PALATO OGIVALE (volta palatina stretta ed alta)
- INCISIVI SUPERIORI PRO - O RETRO - INCLINATI, INCISIVI INFERIORI RETRO INCLINATI
- POSTURA LINGUALE BASSA CHE raramente PUO' DETERMINARE PROGNATISMO MANDIBOLARE
- RETROGNATISMO E POST-ROTAZIONE MANDIBOLARE (più spesso)
- IPERESTENSIONE del CAPO (per assicurare una migliore pervietà delle vie aeree)

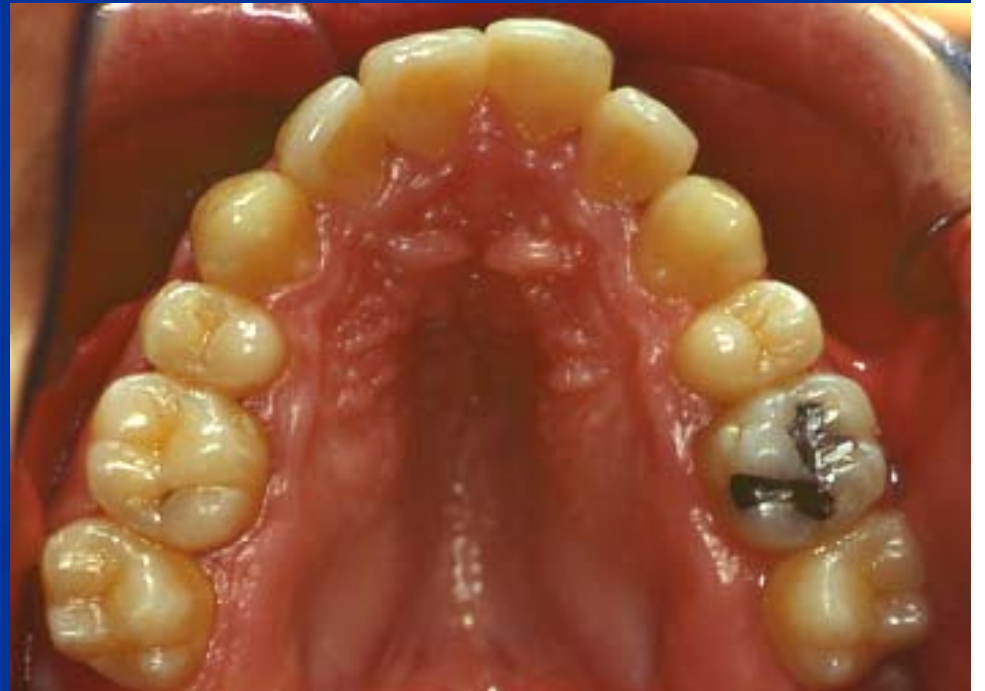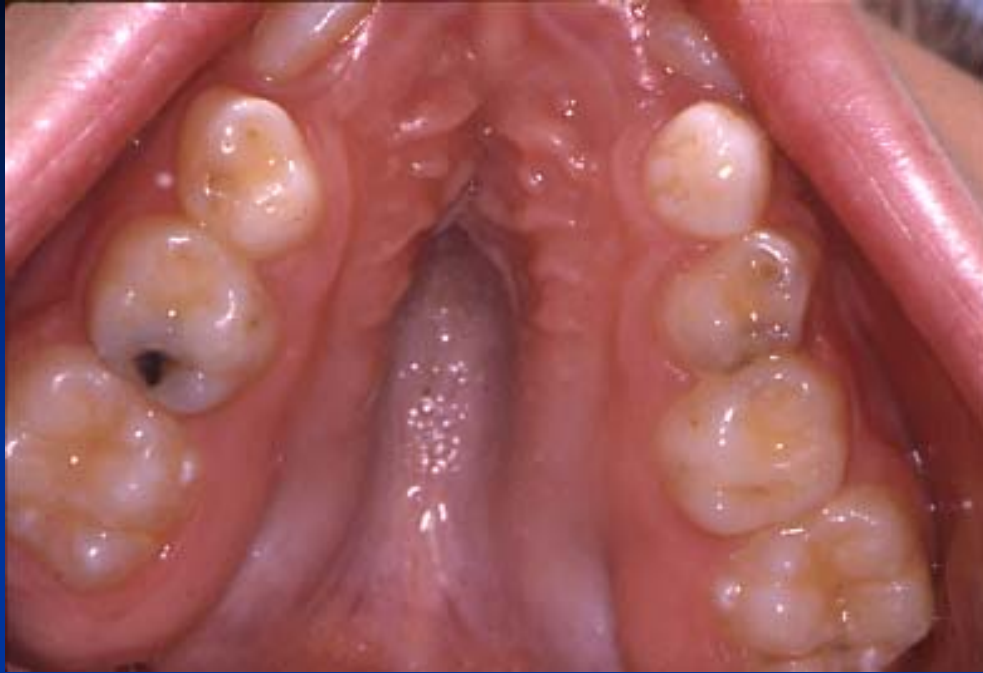## **Cause (più frequenti) di Ostruzione nasale persistente nei bambini**

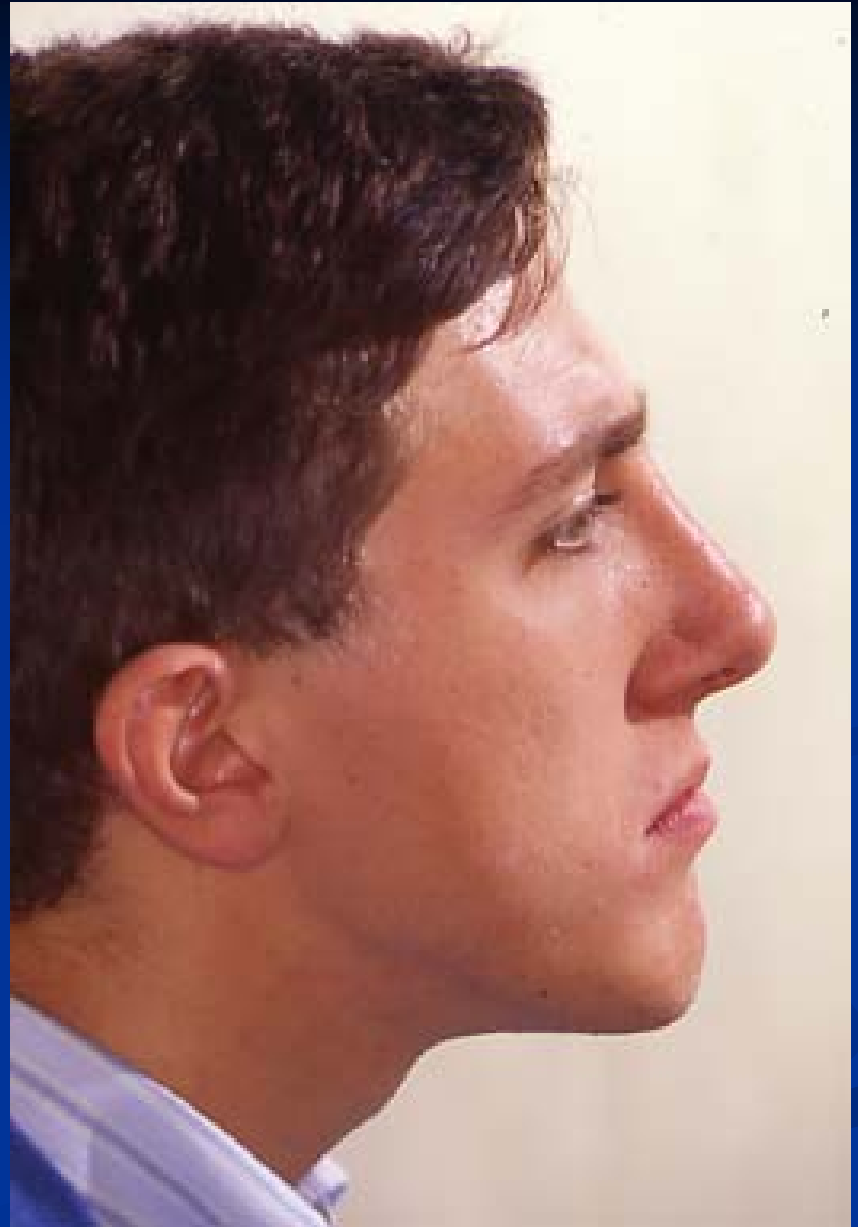
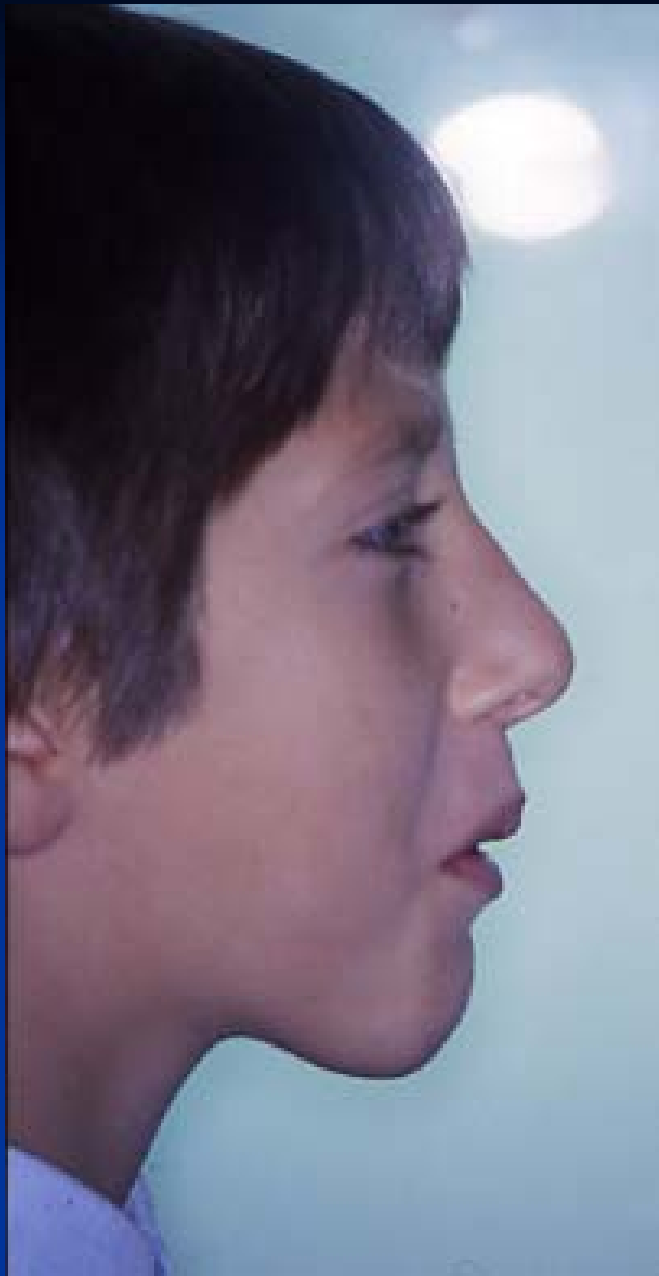- **IPERTROFIA ADENOIDEA e ADENO - TONSILLITE**
- **RINITE ALLERGICA PERENNE e VASOMOTORIA**
- **RINO SINUSITE CRONICA**
- **DEVIAZIONE SETTALE**
- **IPERTROFIA dei TURBINATI**
- **POLIPOSI NASALE**
- **TUMORI BENIGNI / MALIGNI**
- **ATRESIA COANALE**

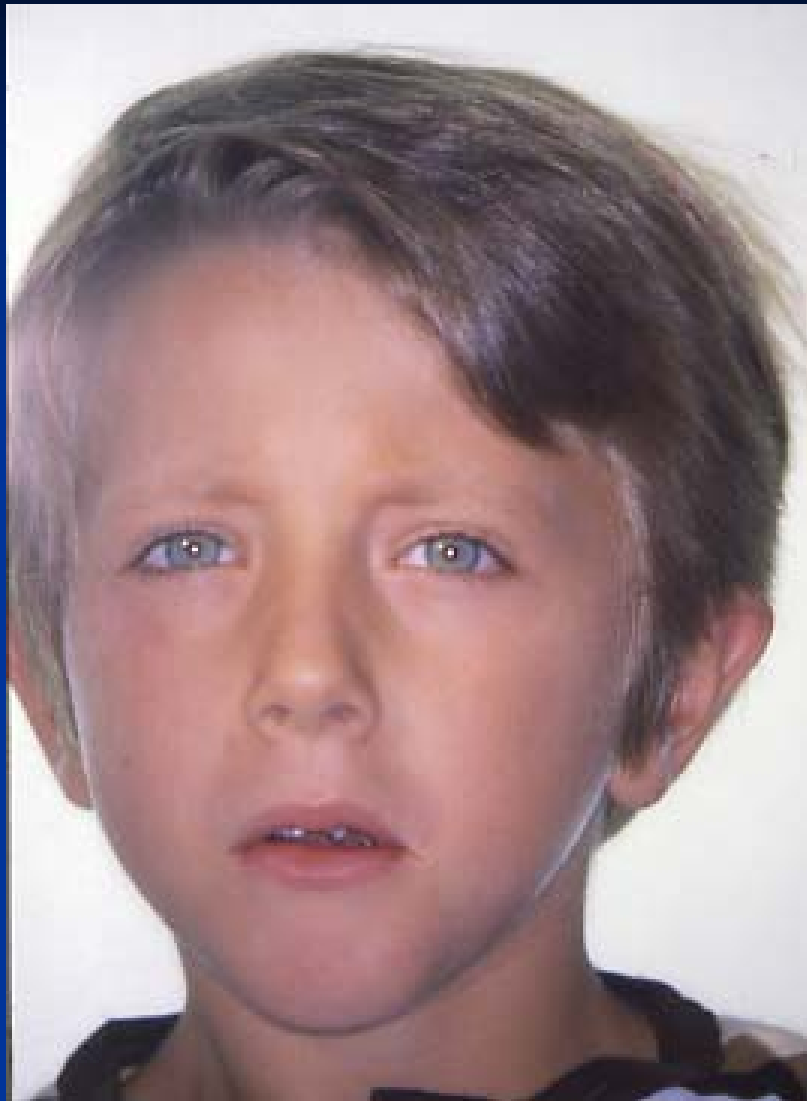

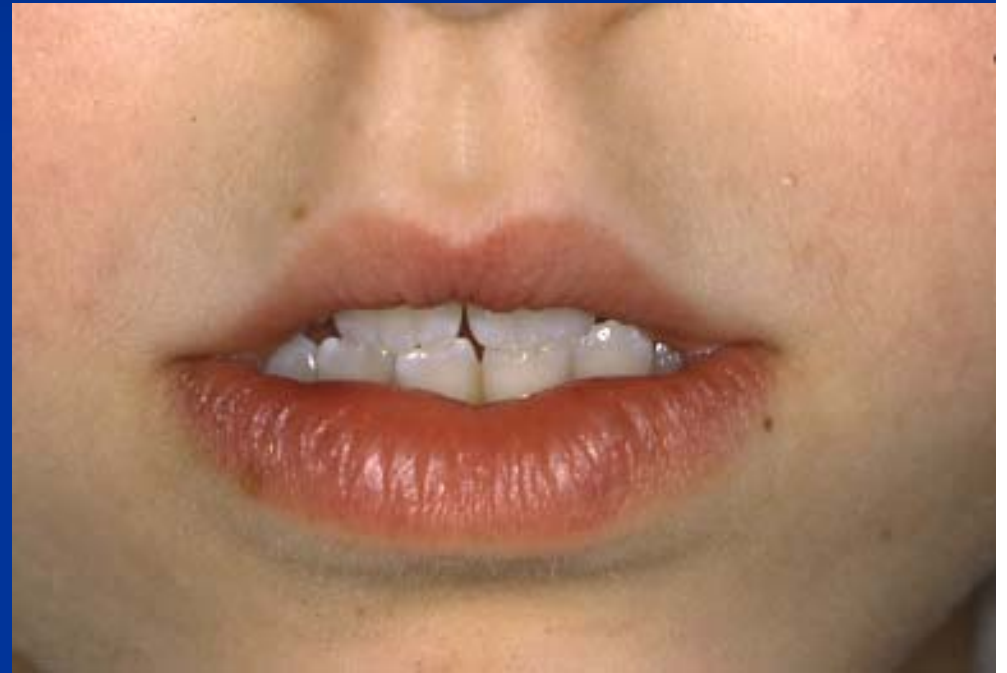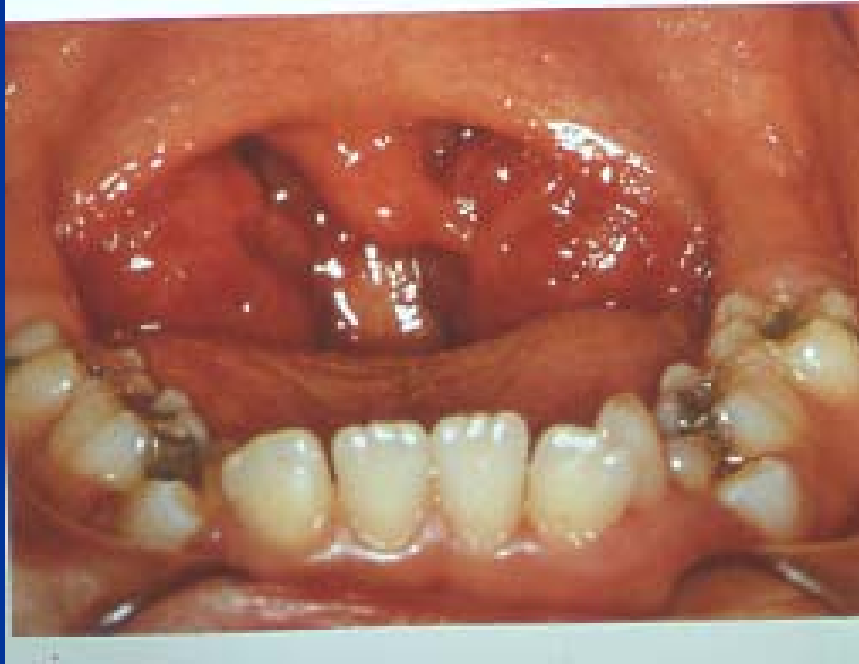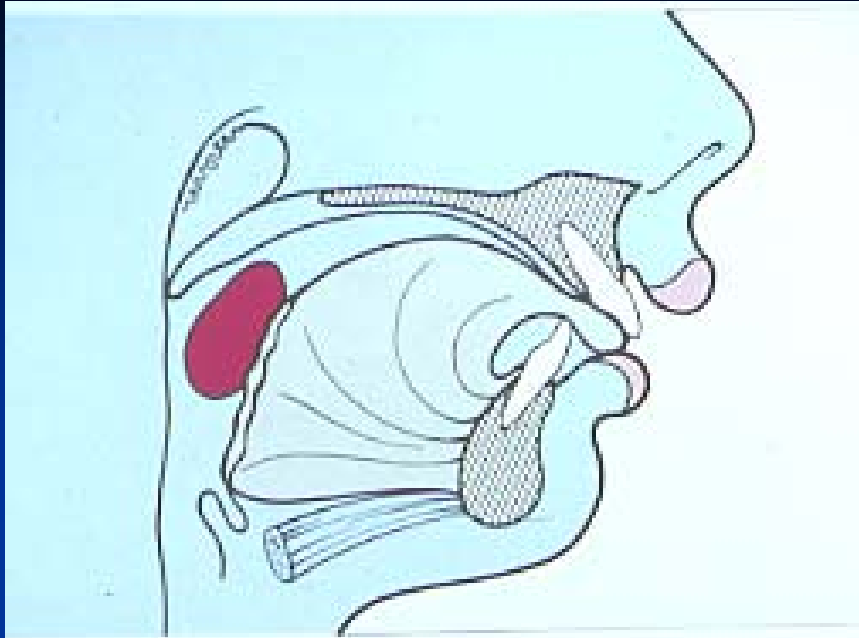





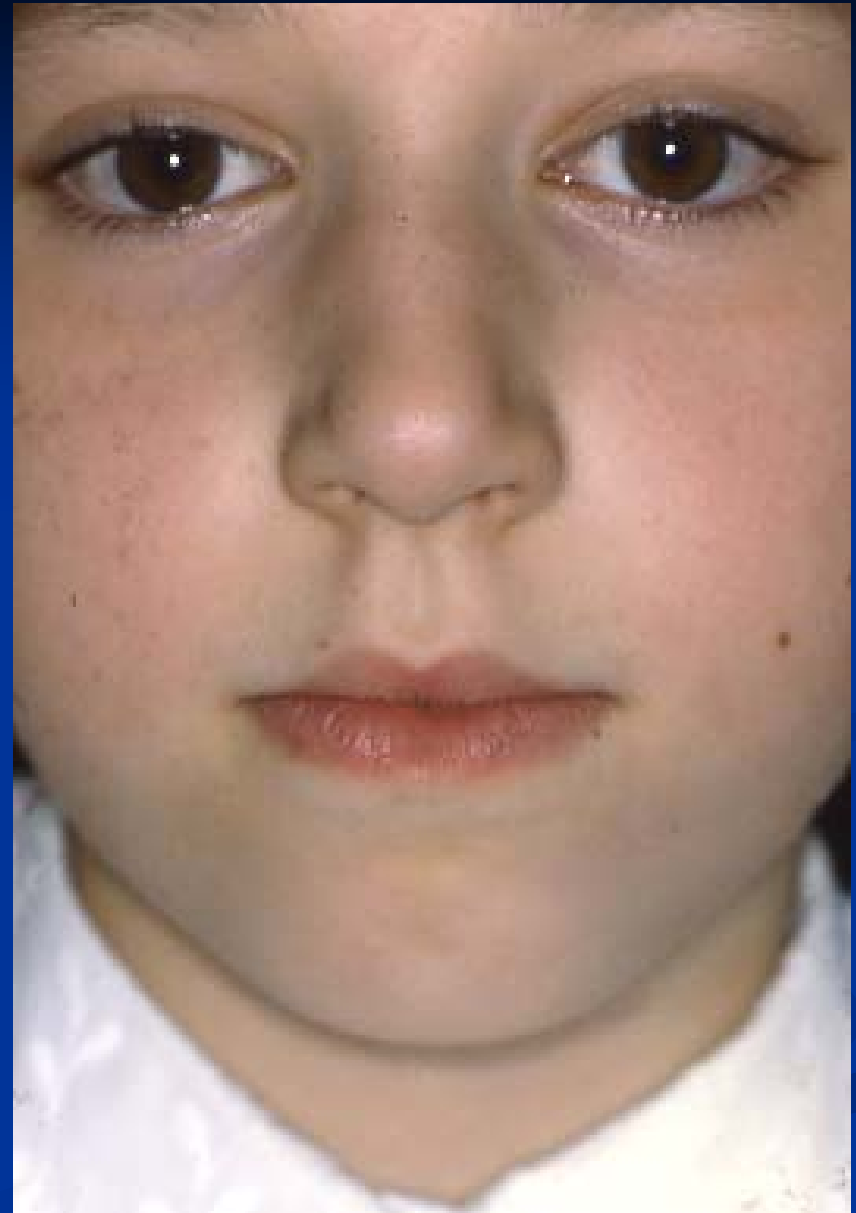
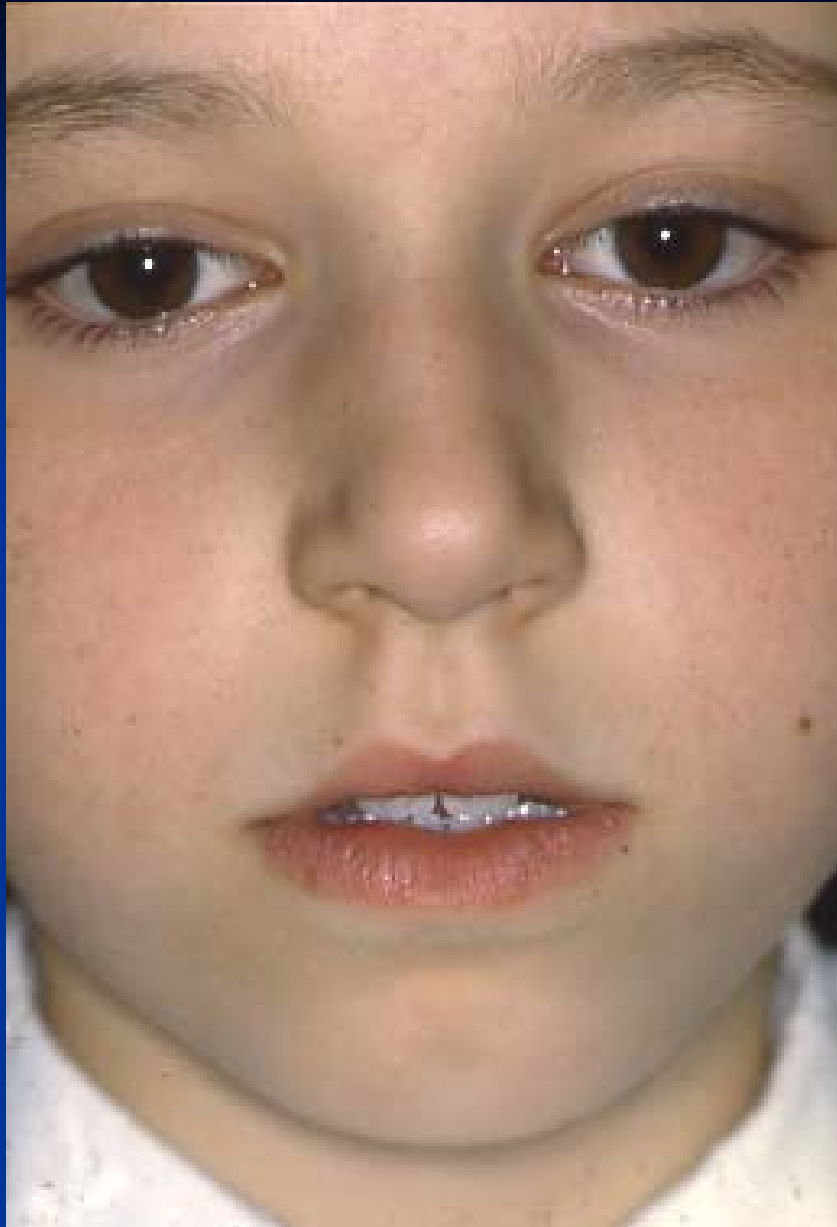

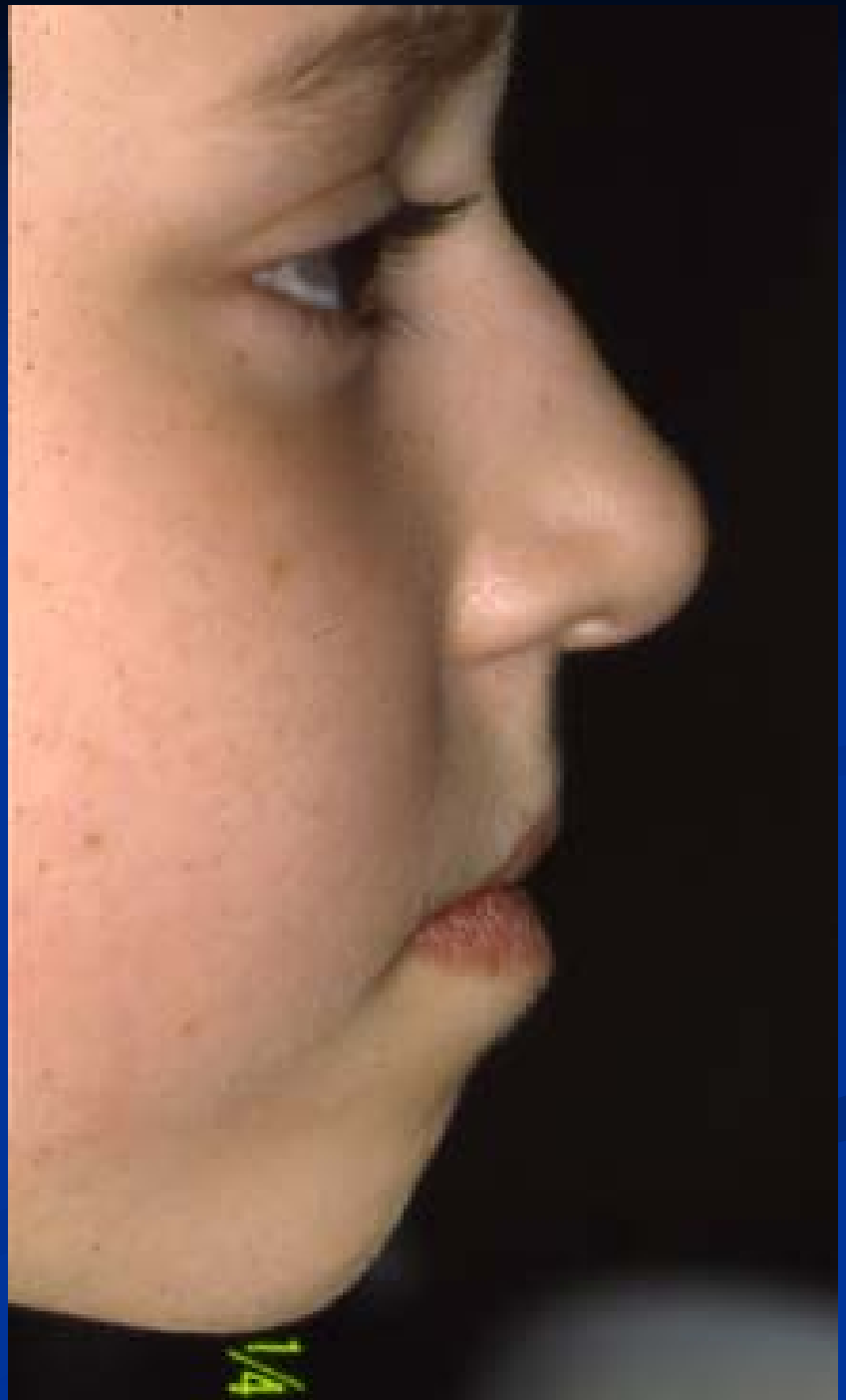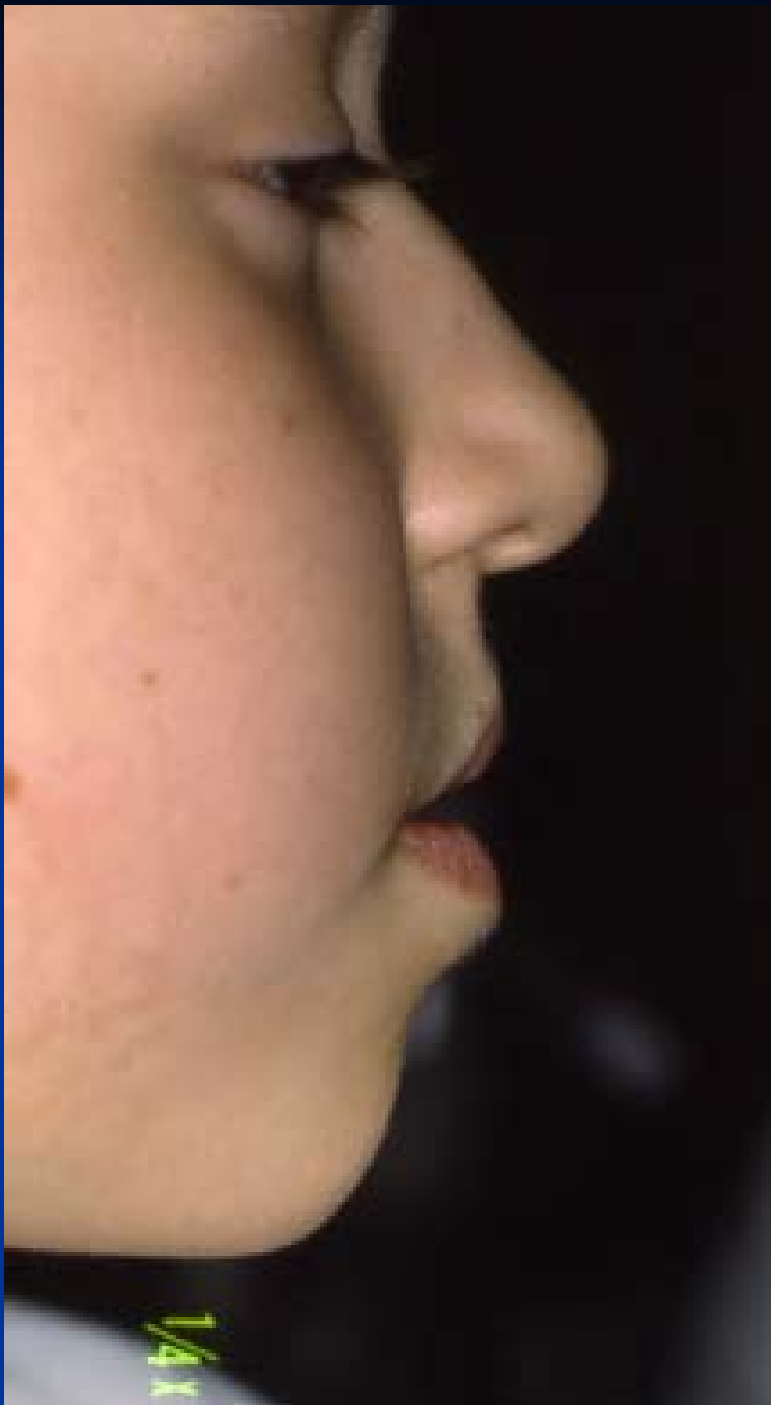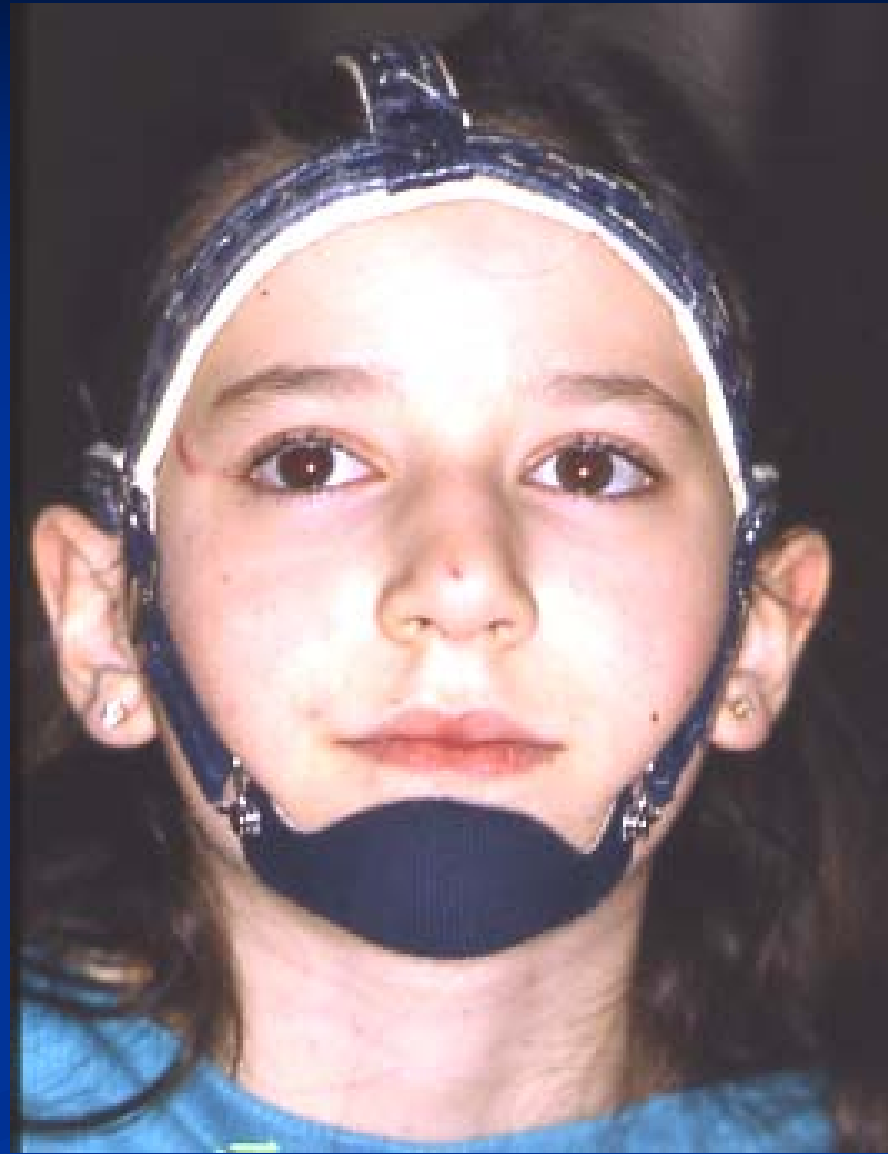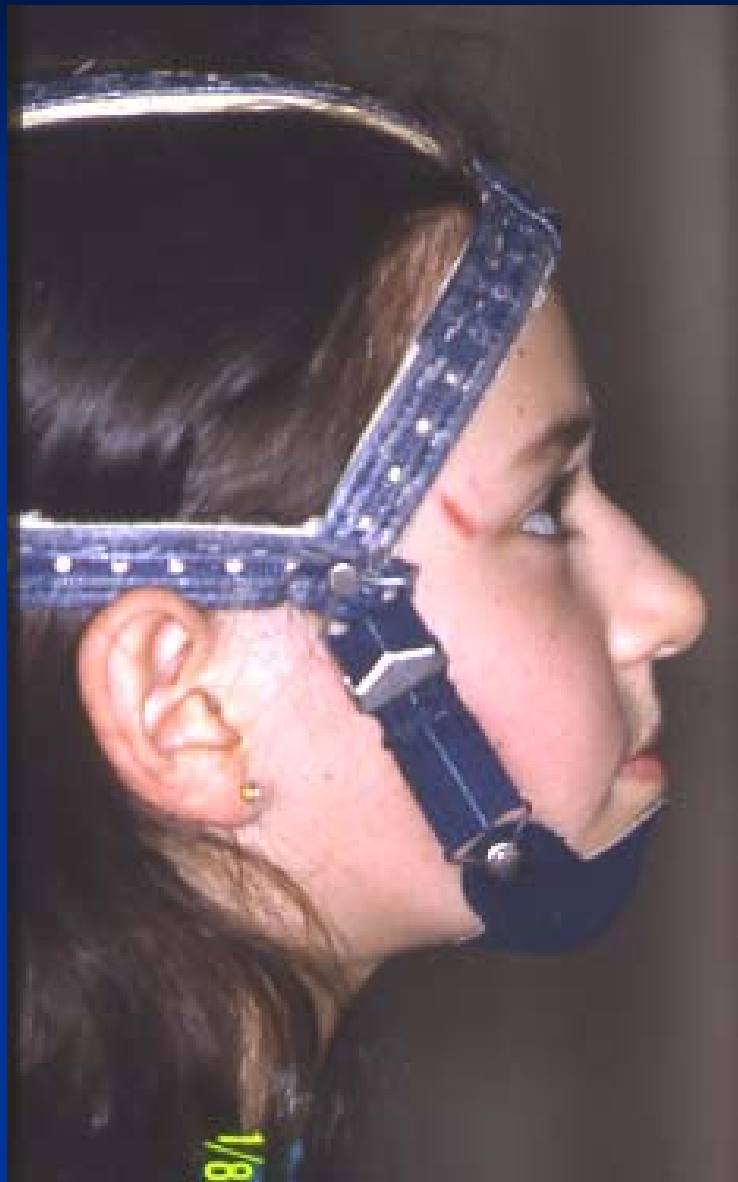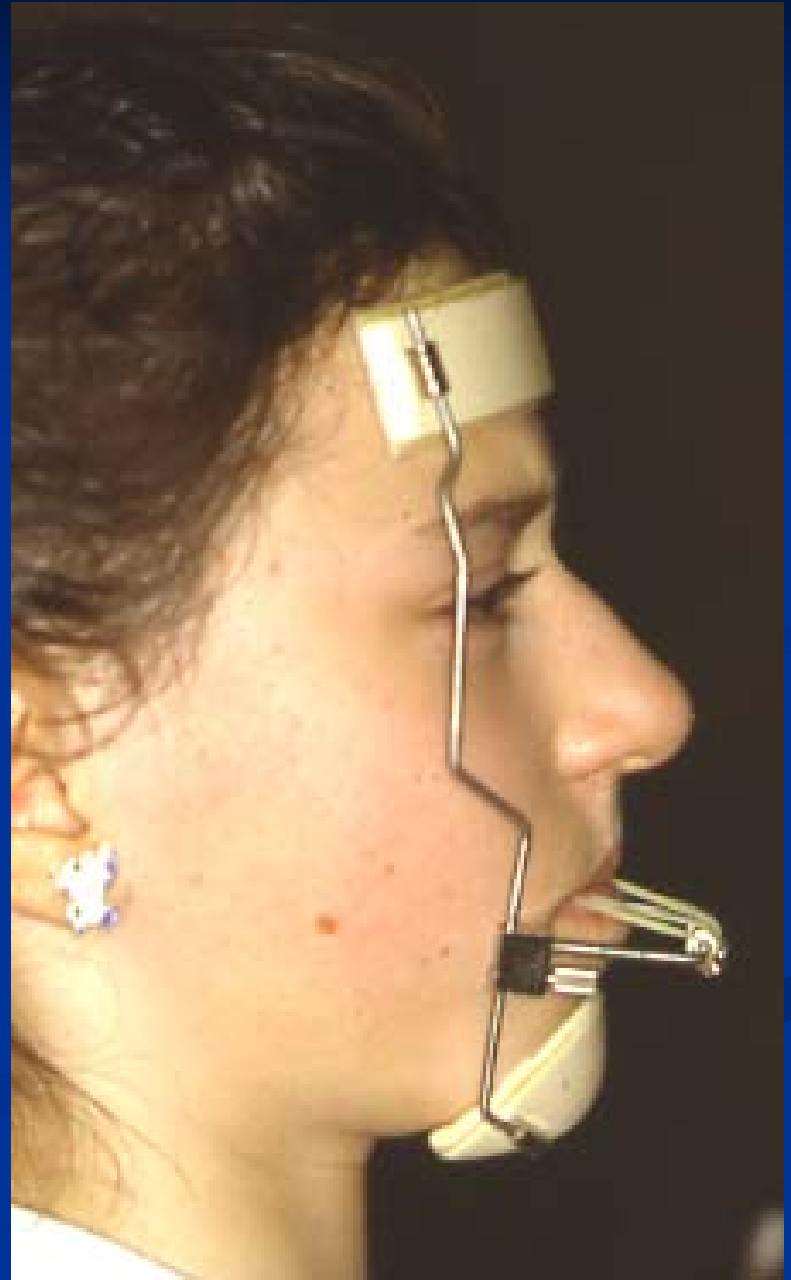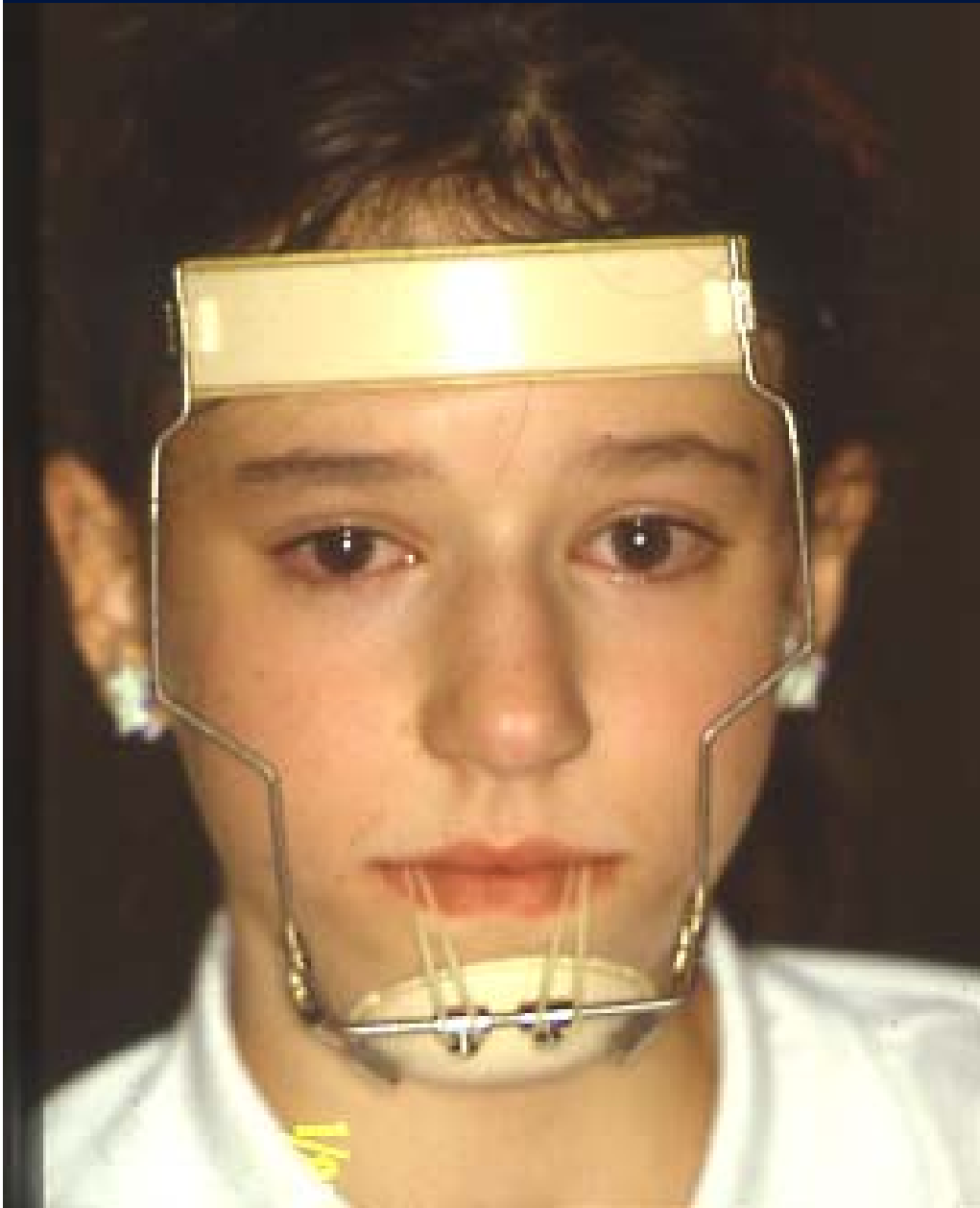












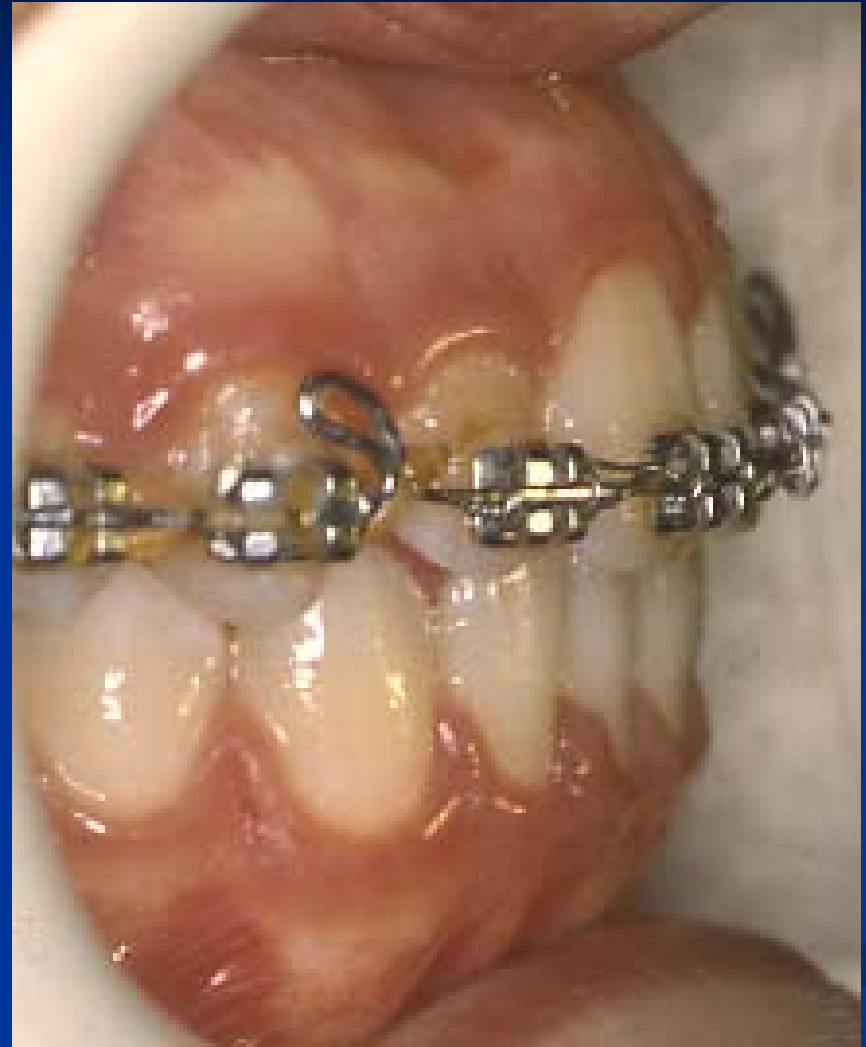
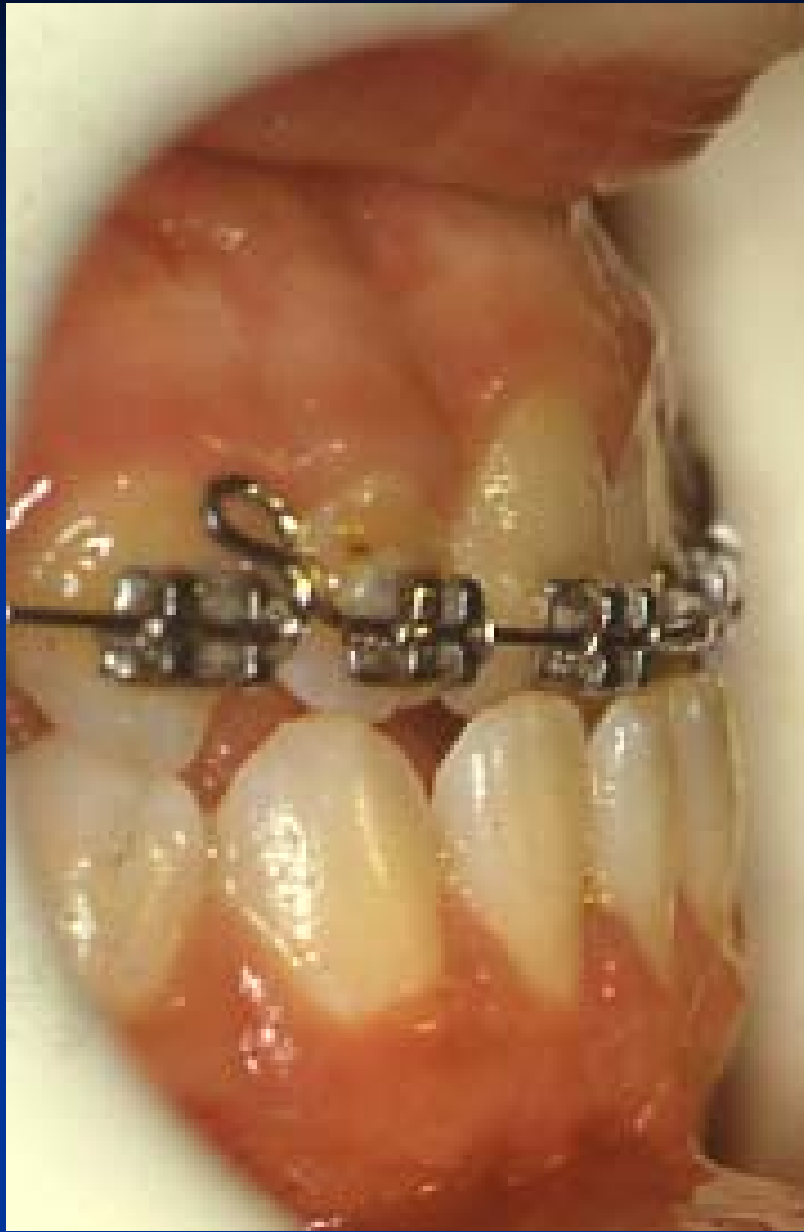


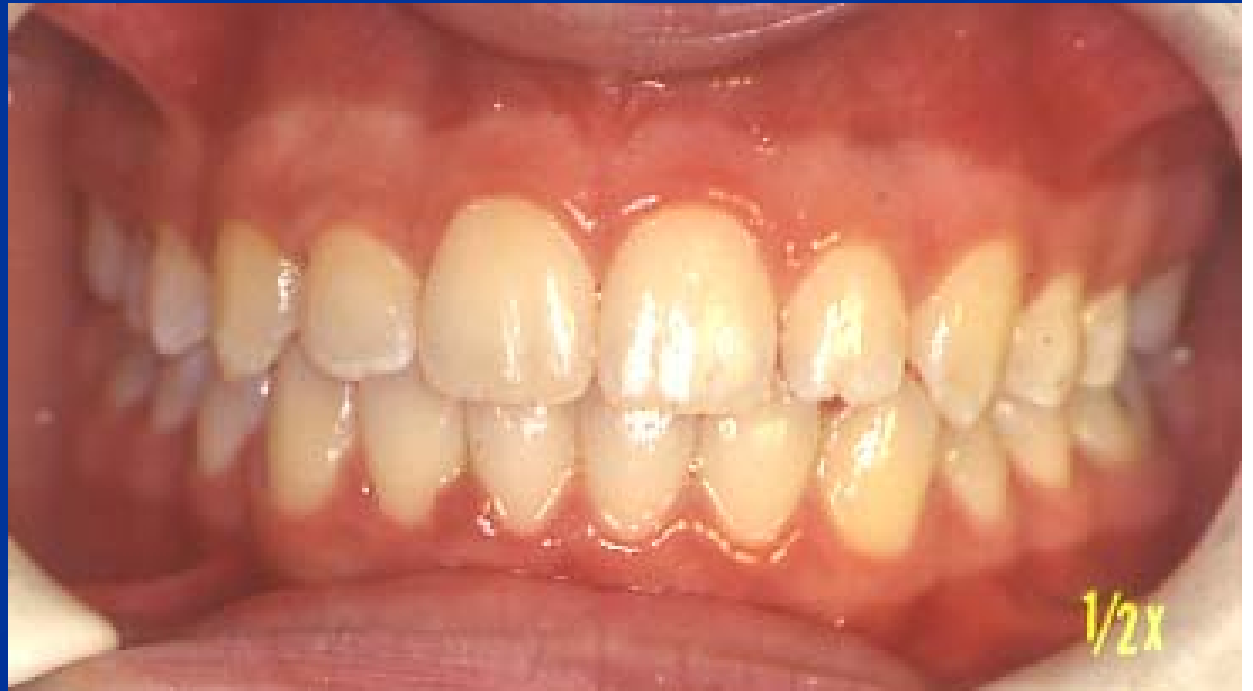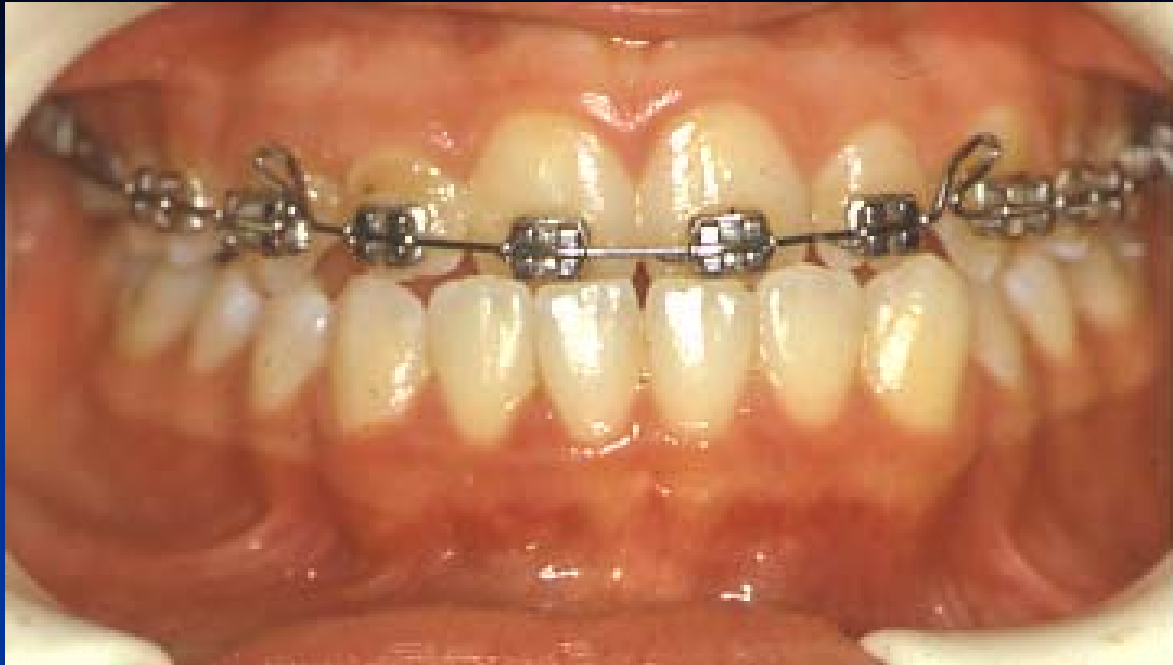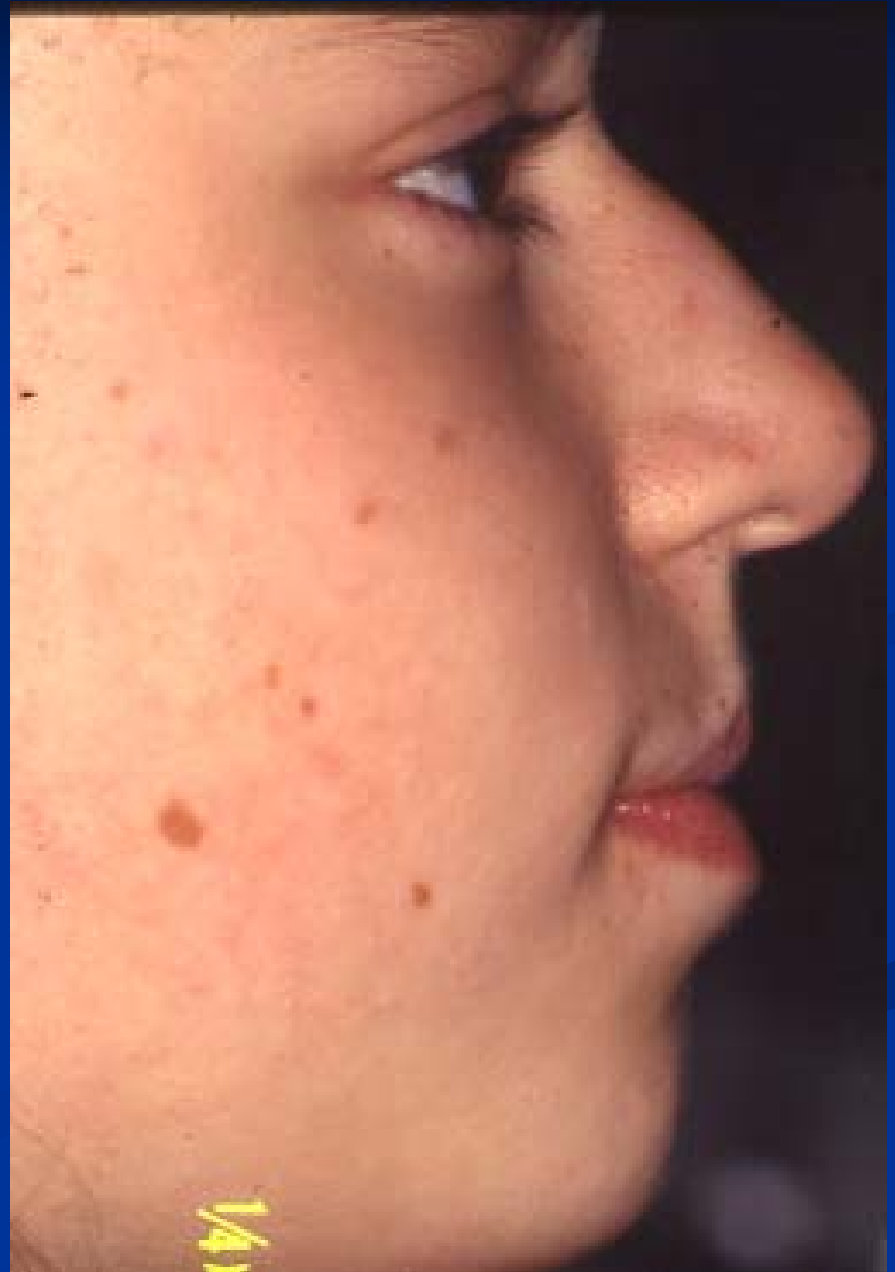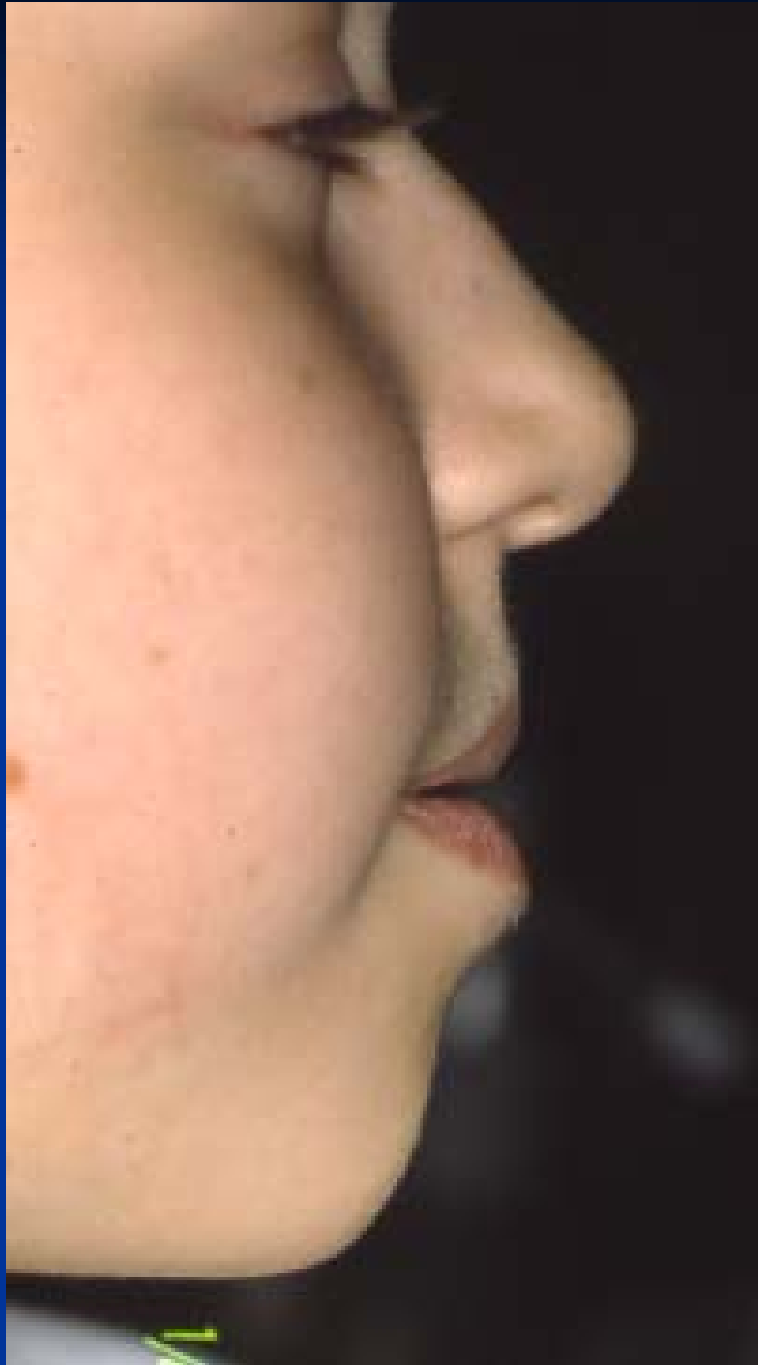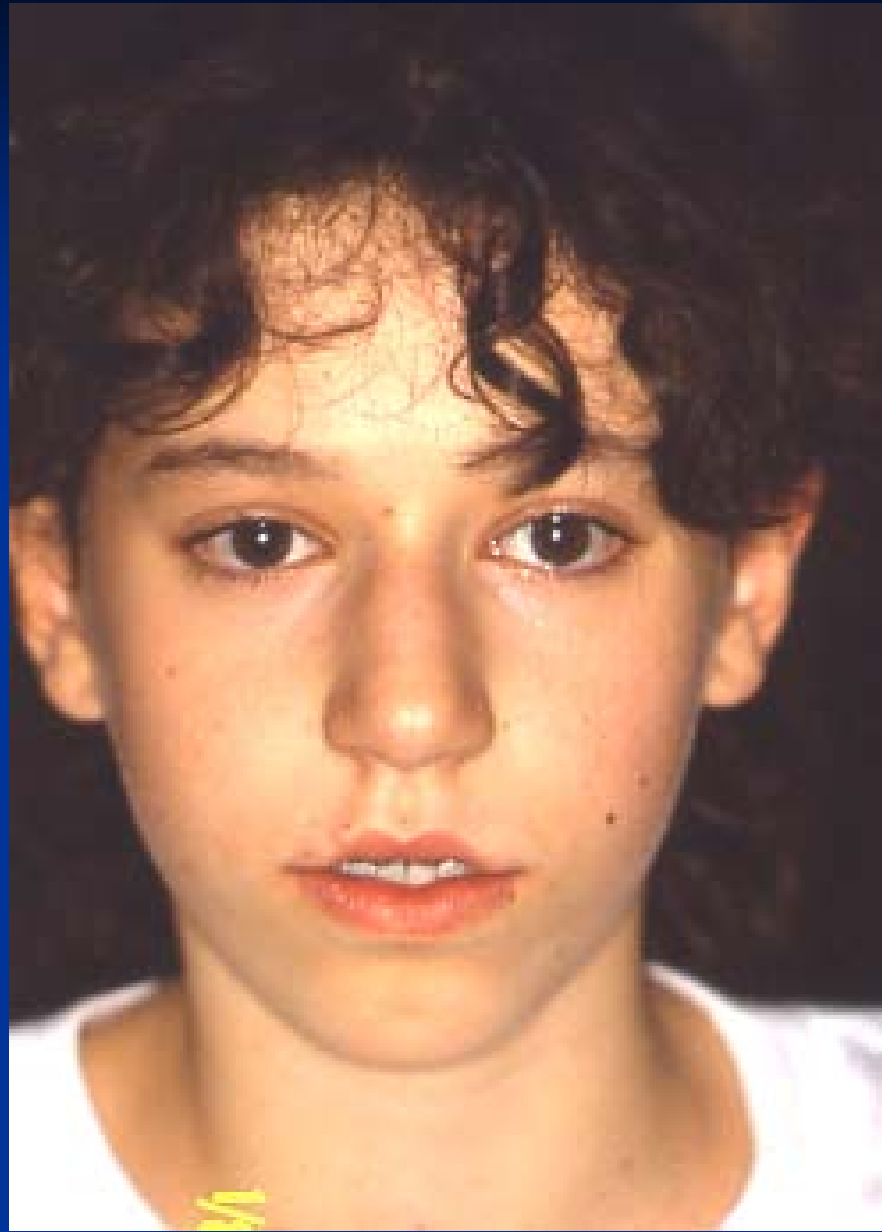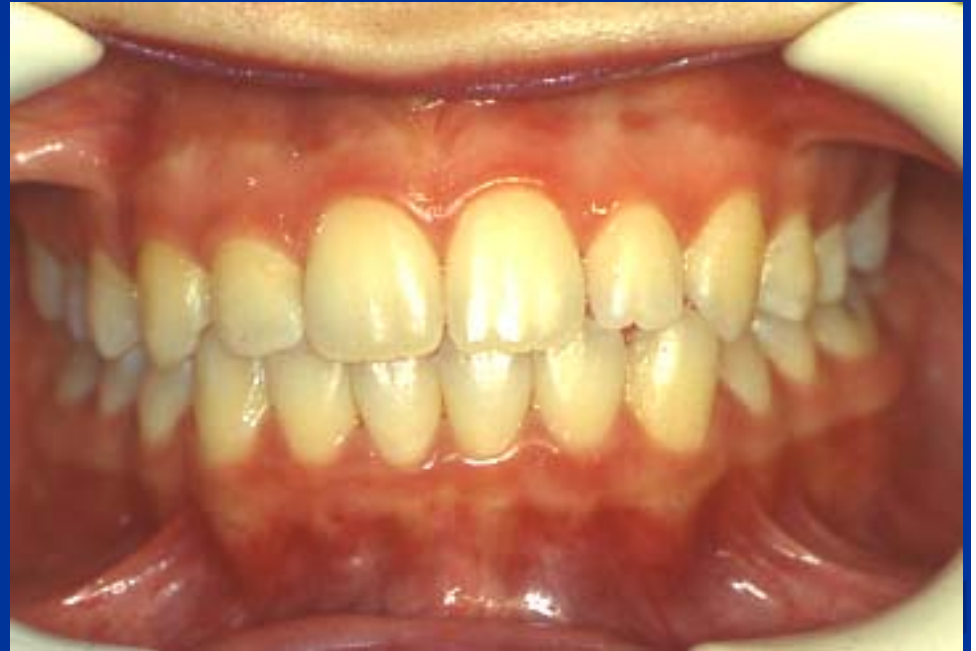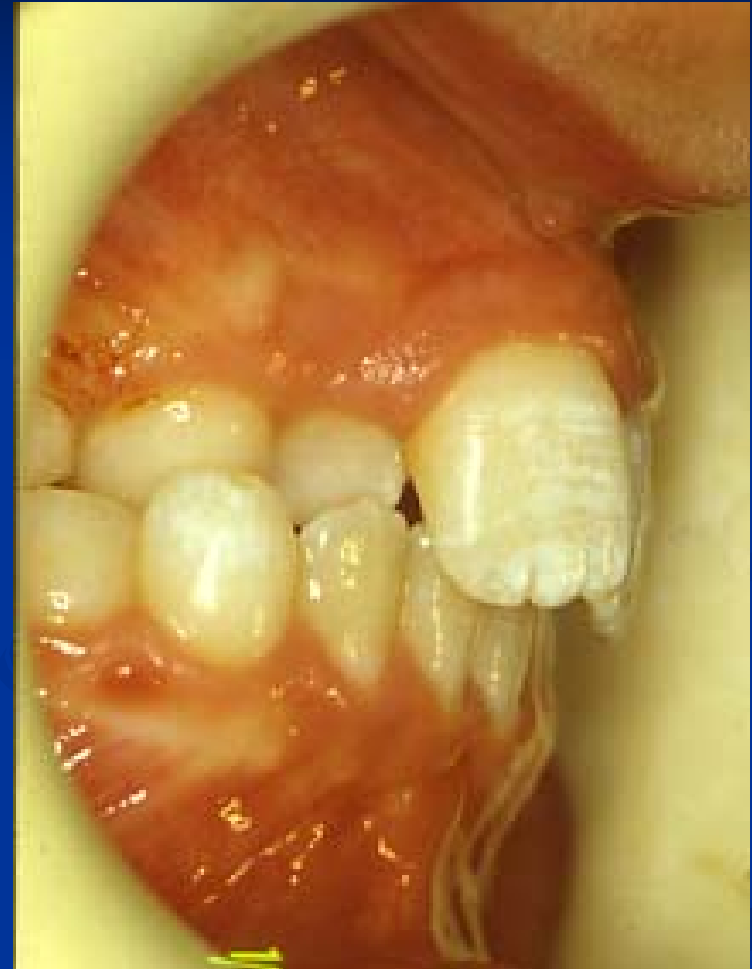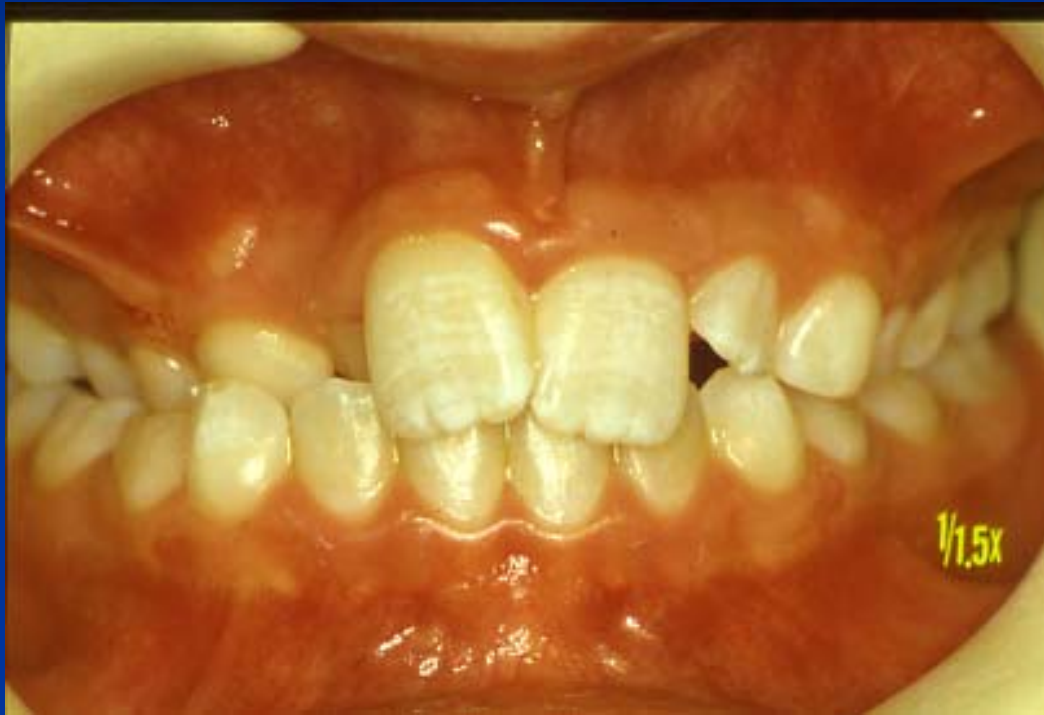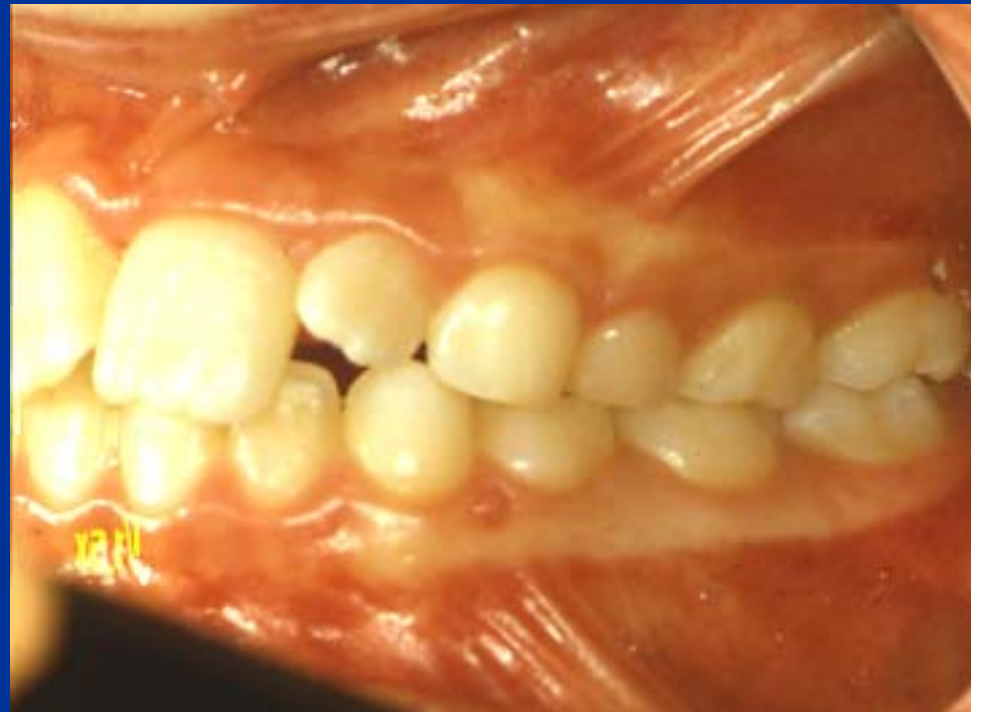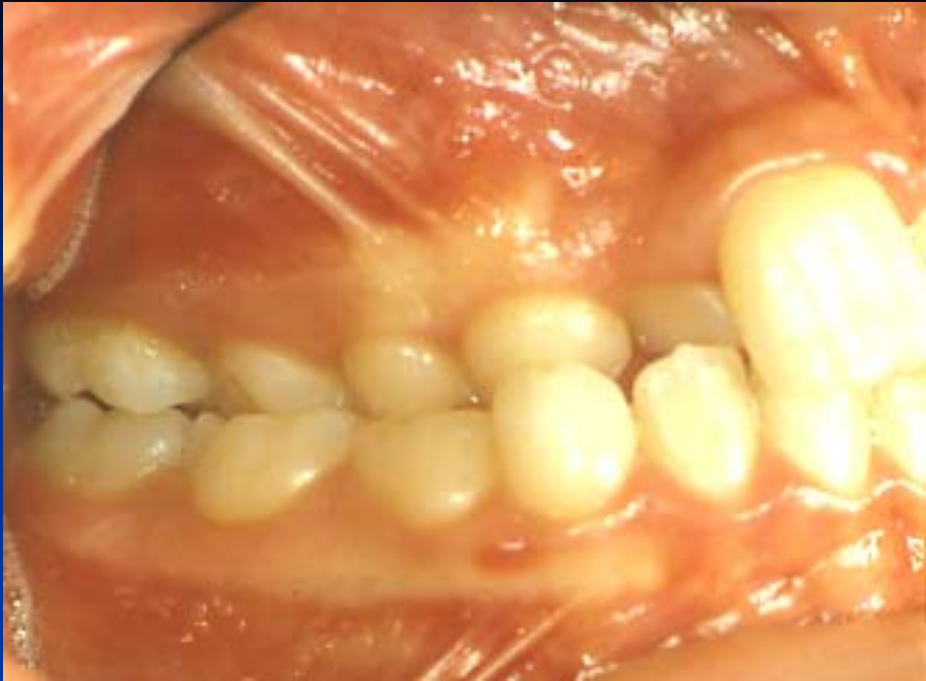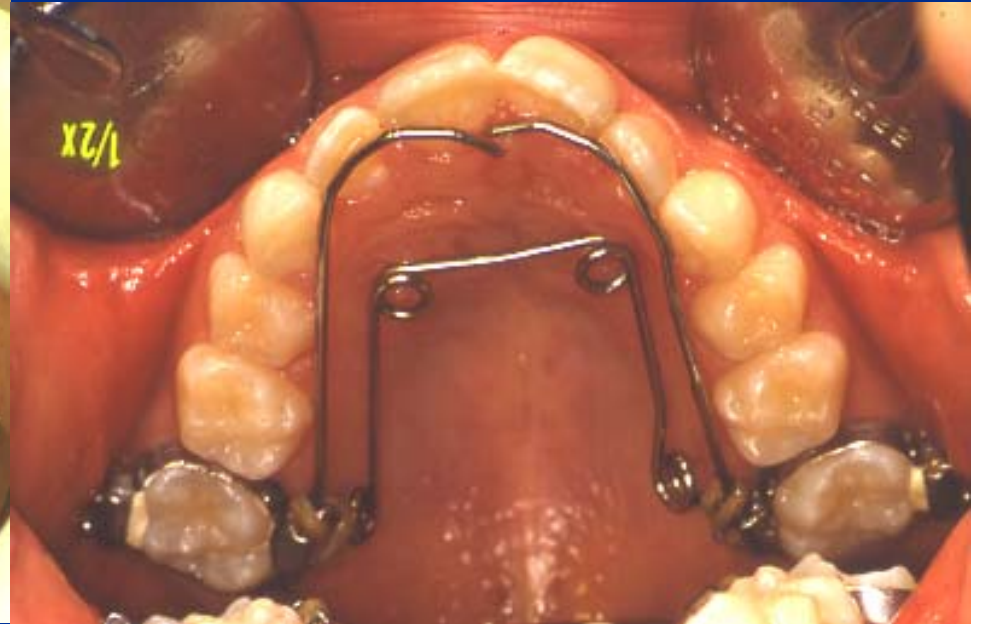
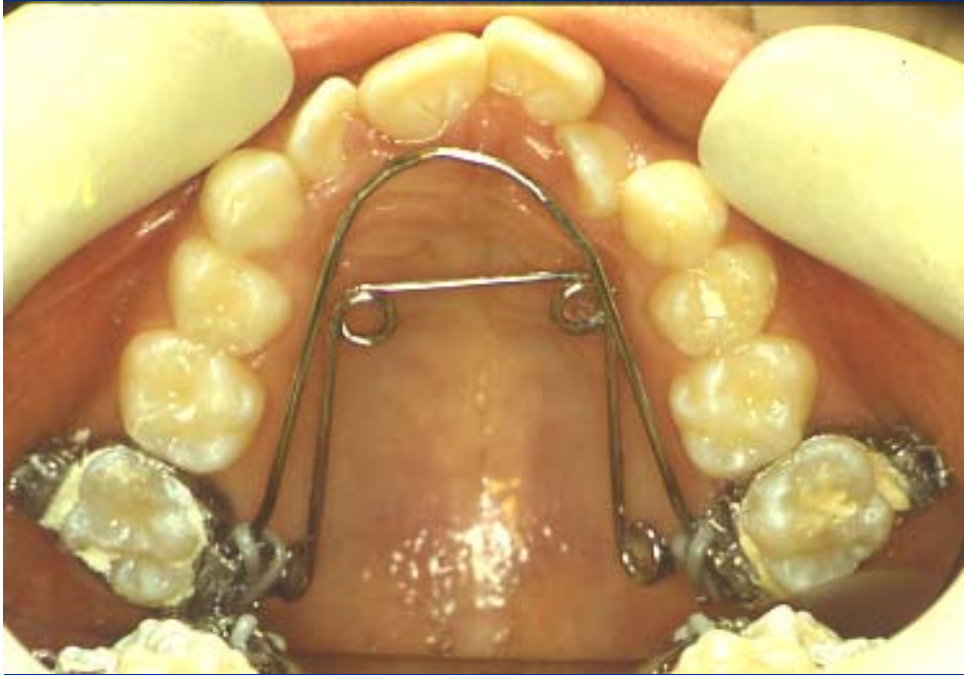
















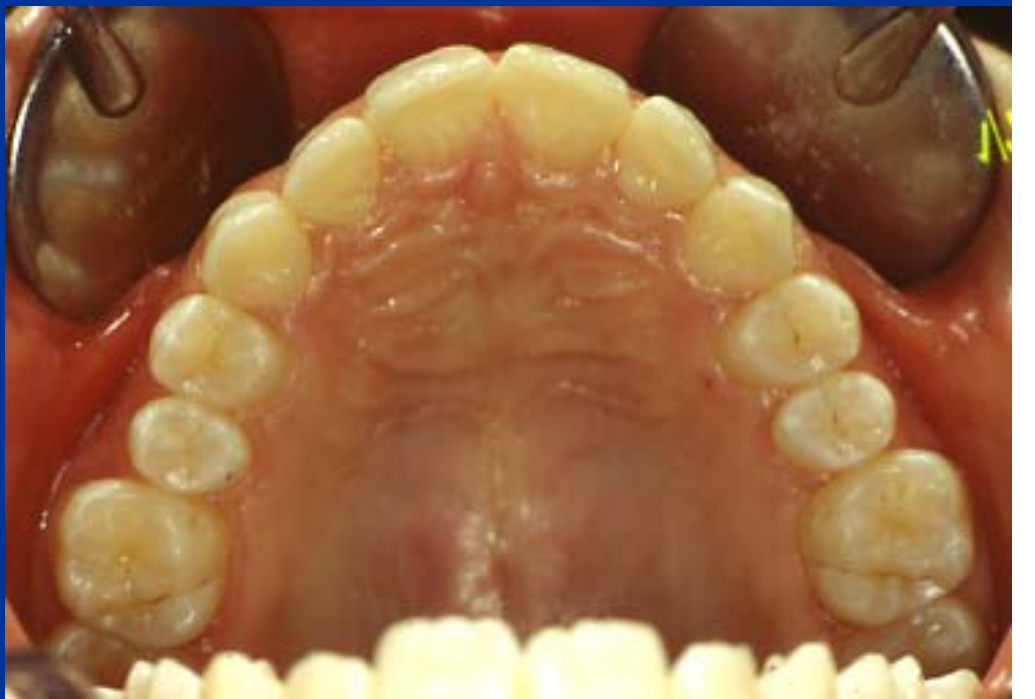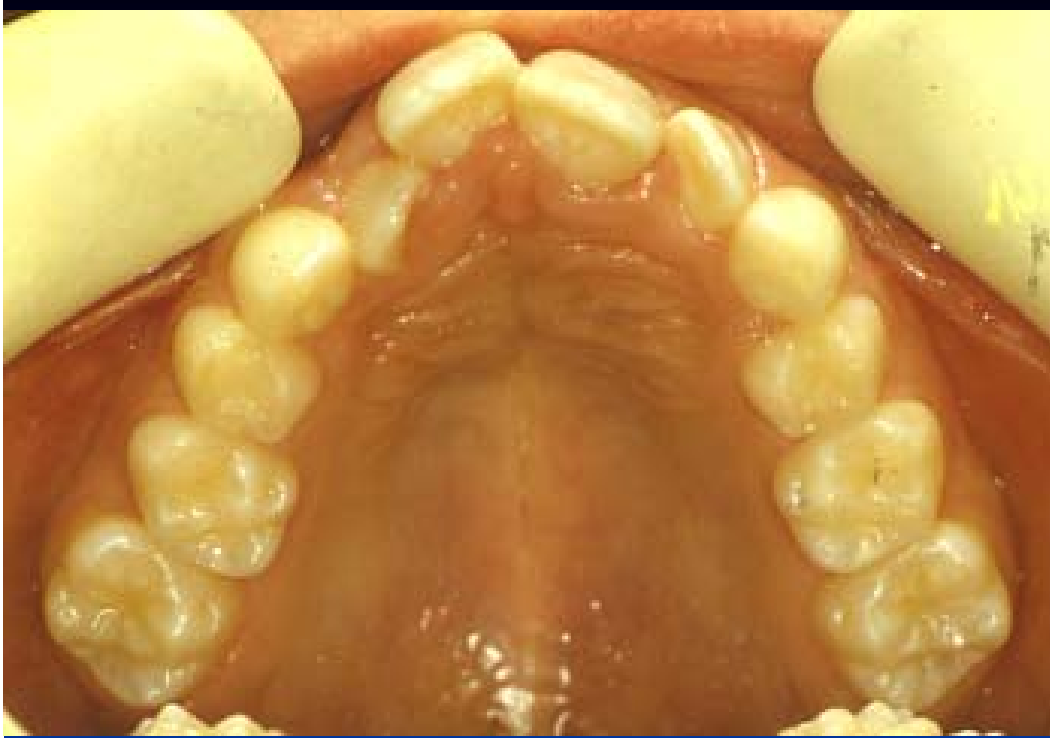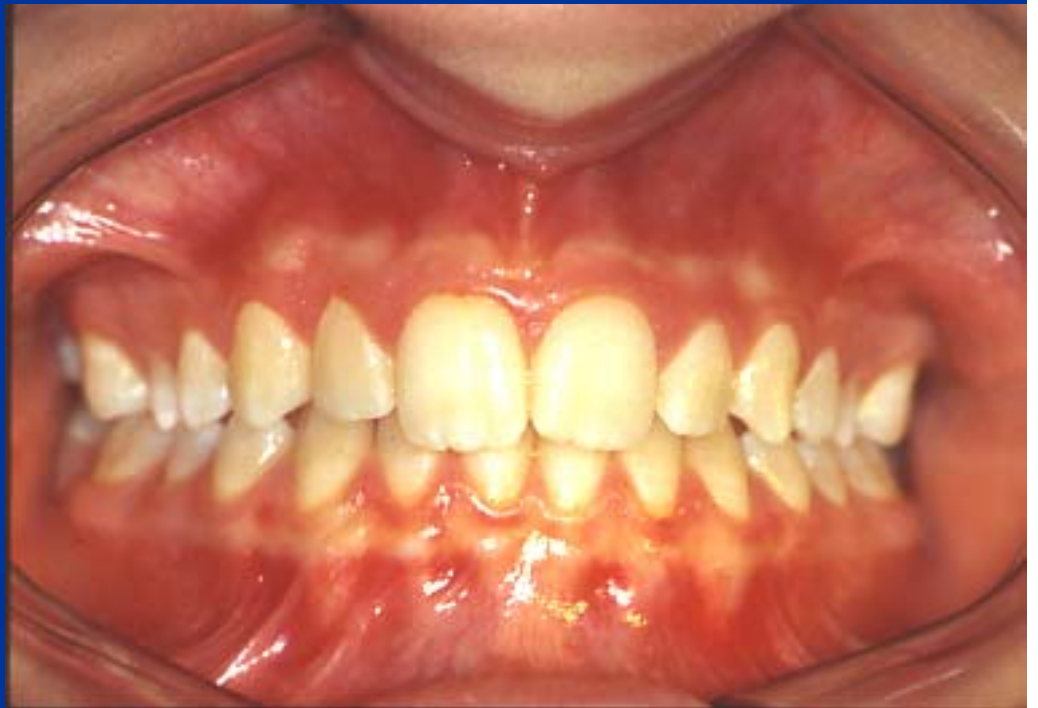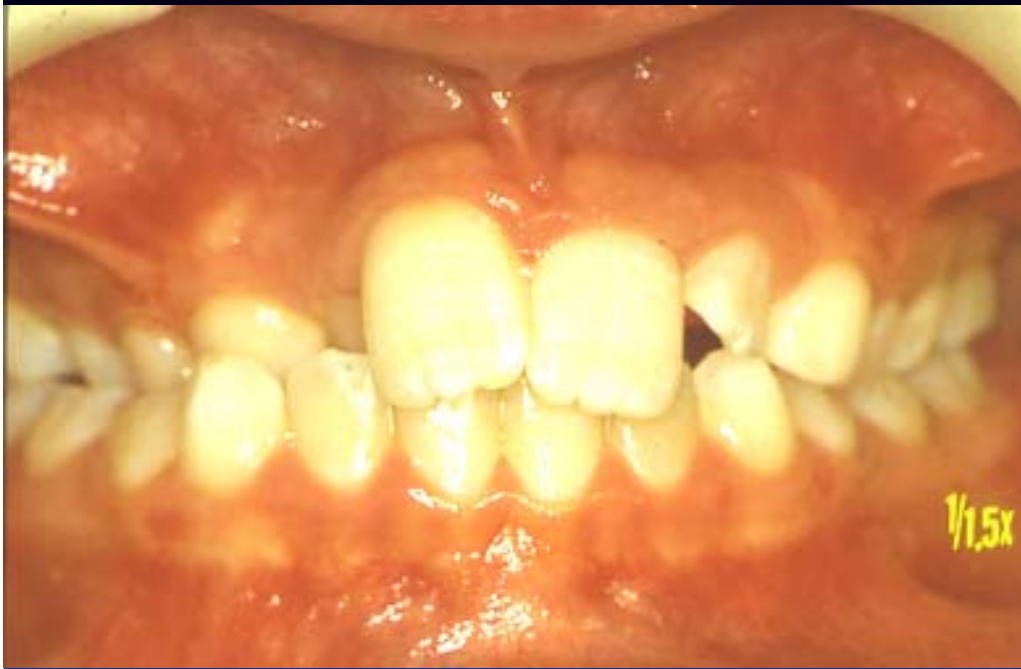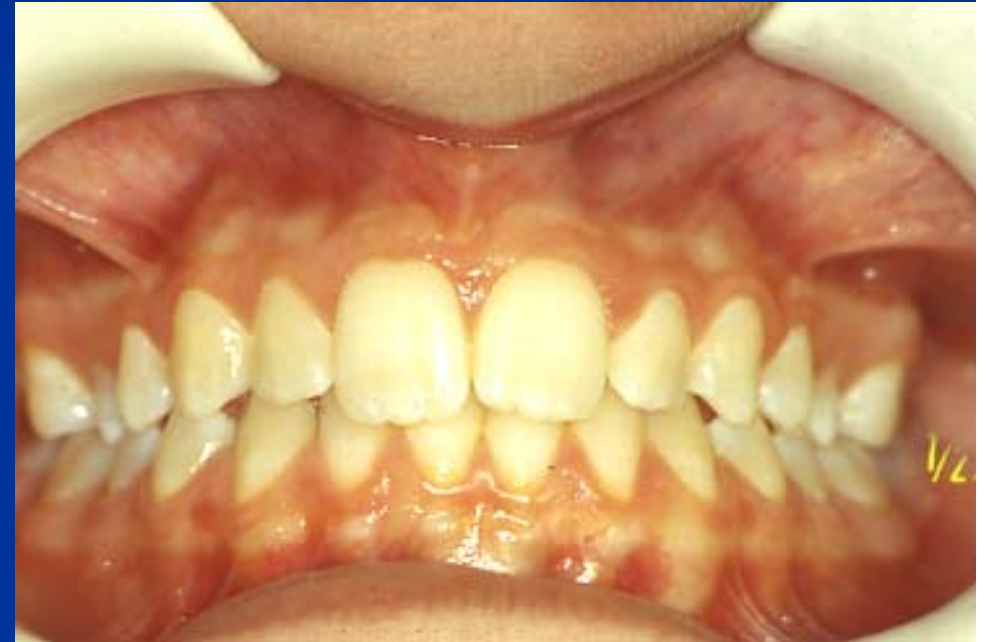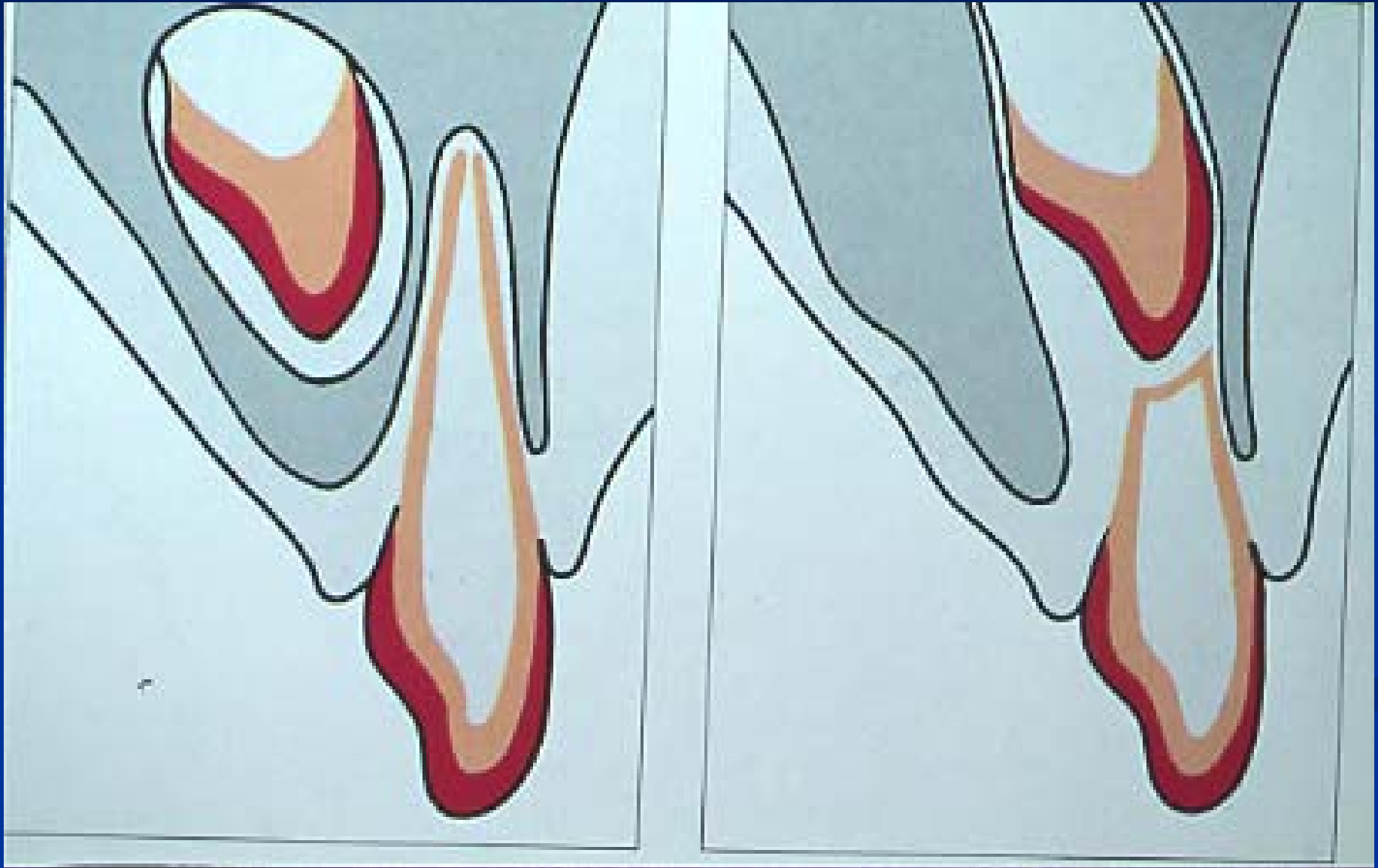


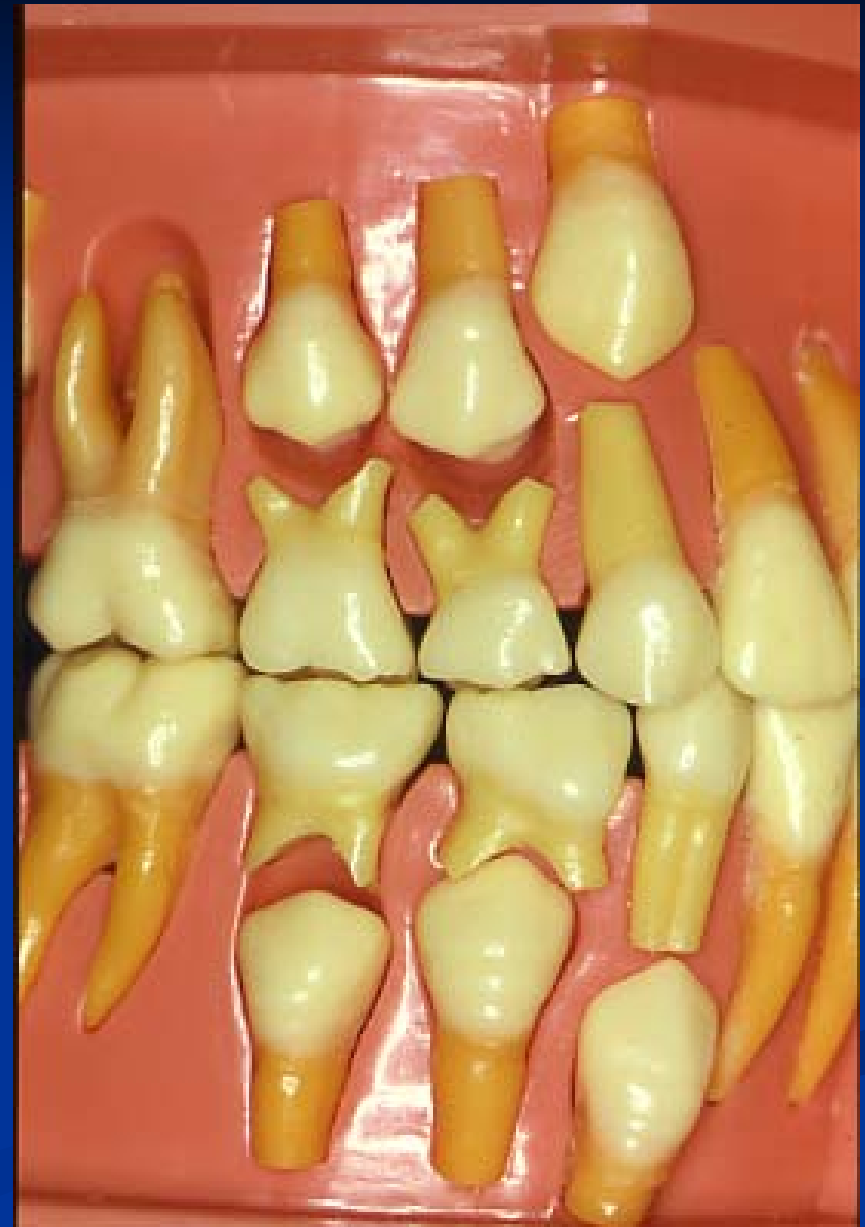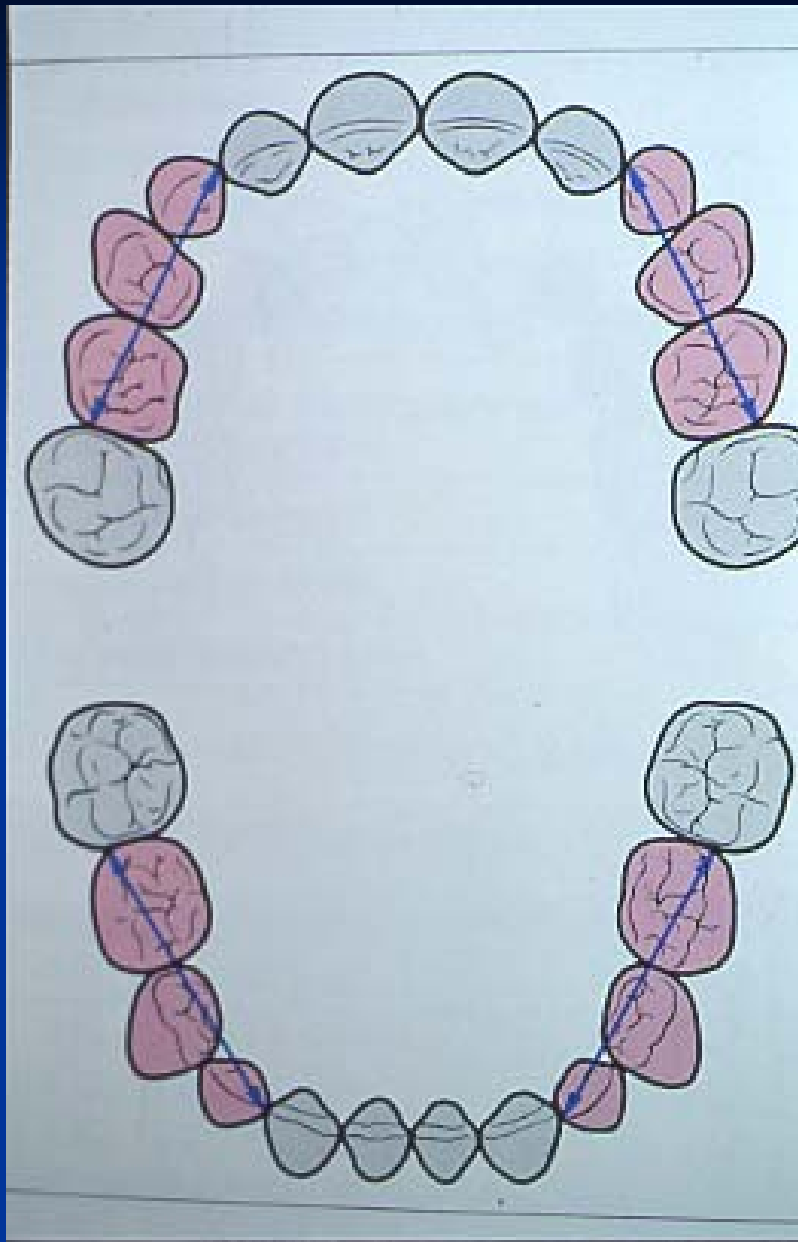


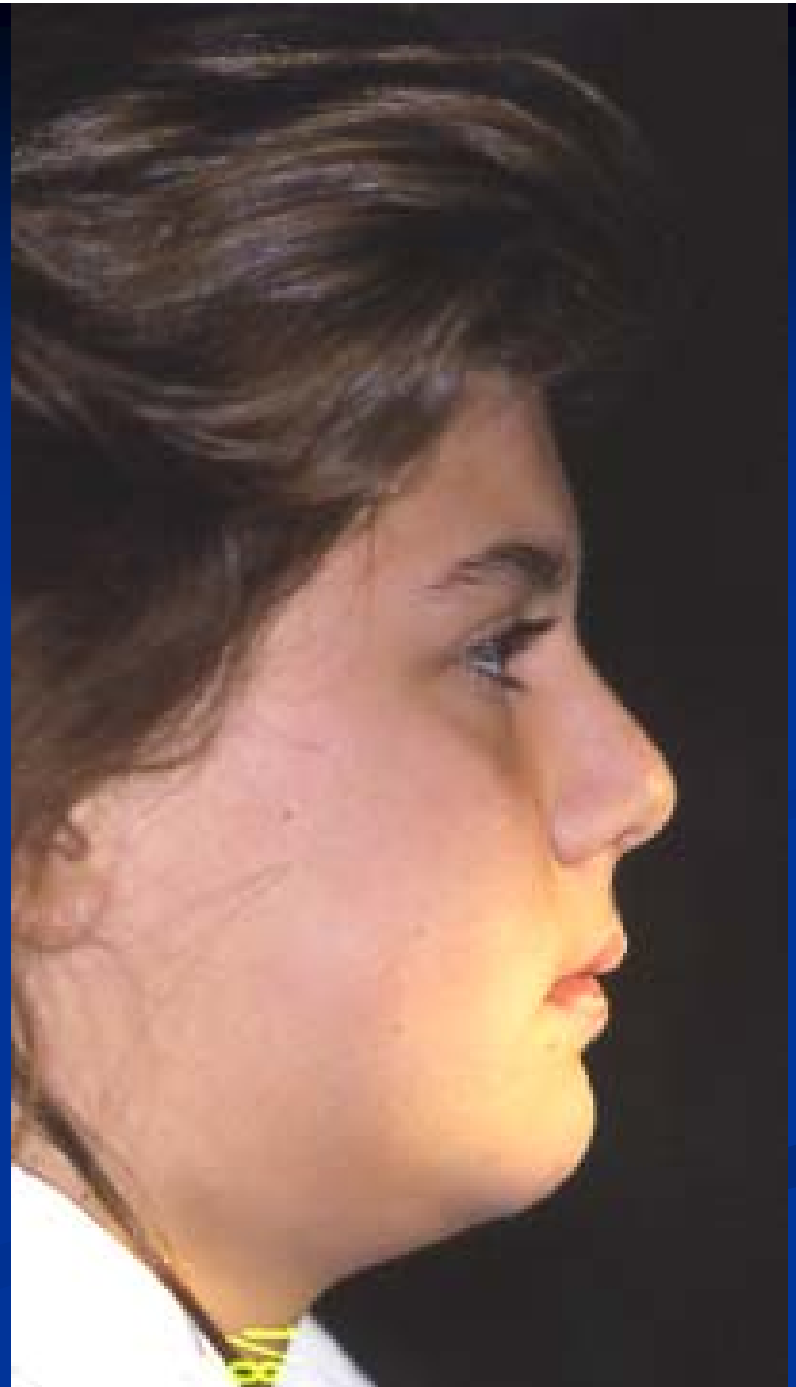# Quando...

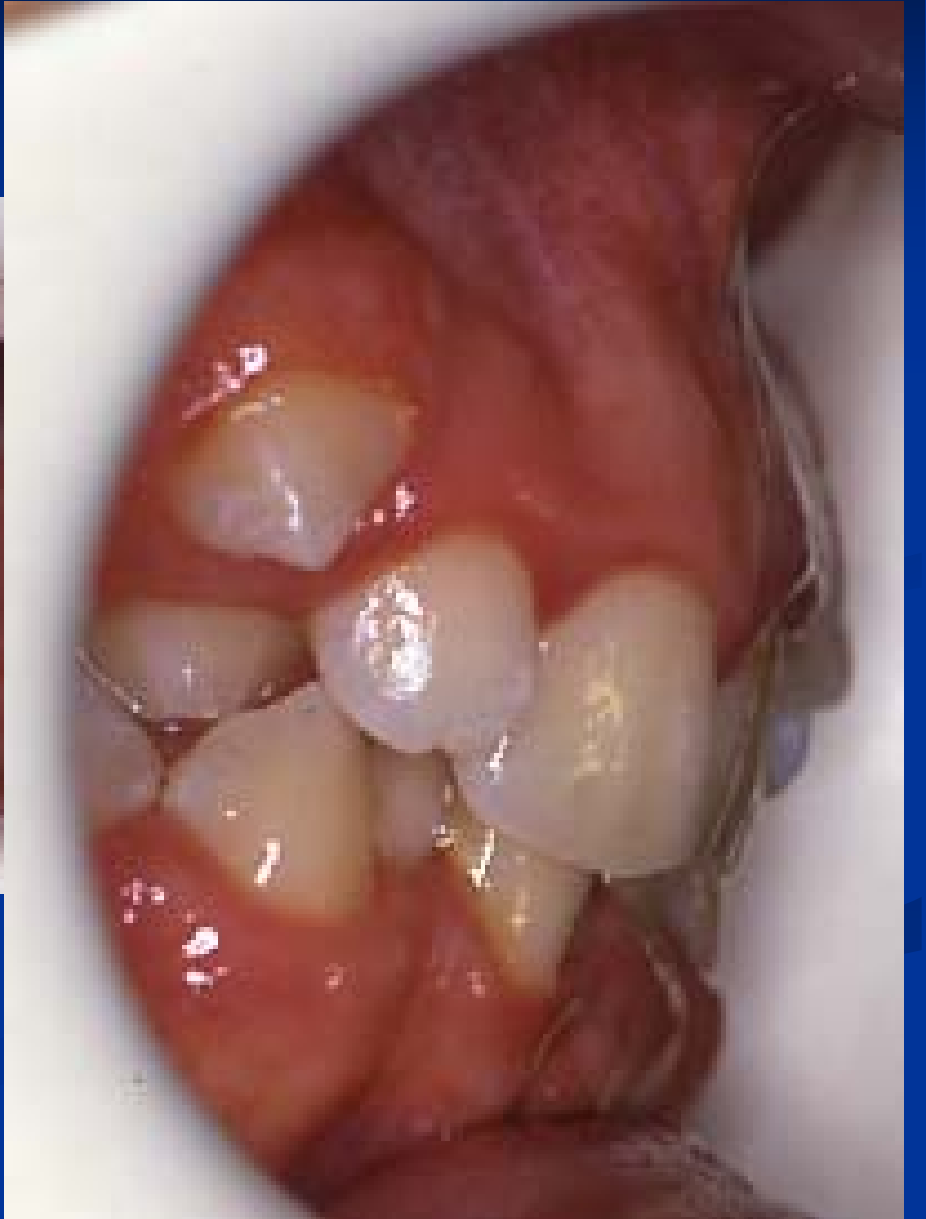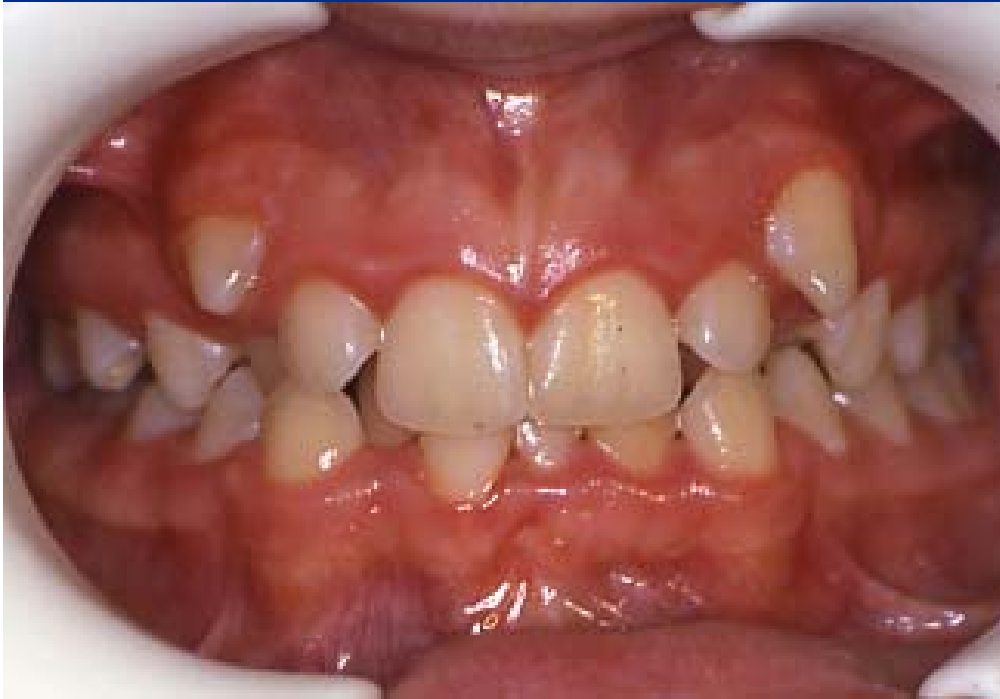## In dentatura mista

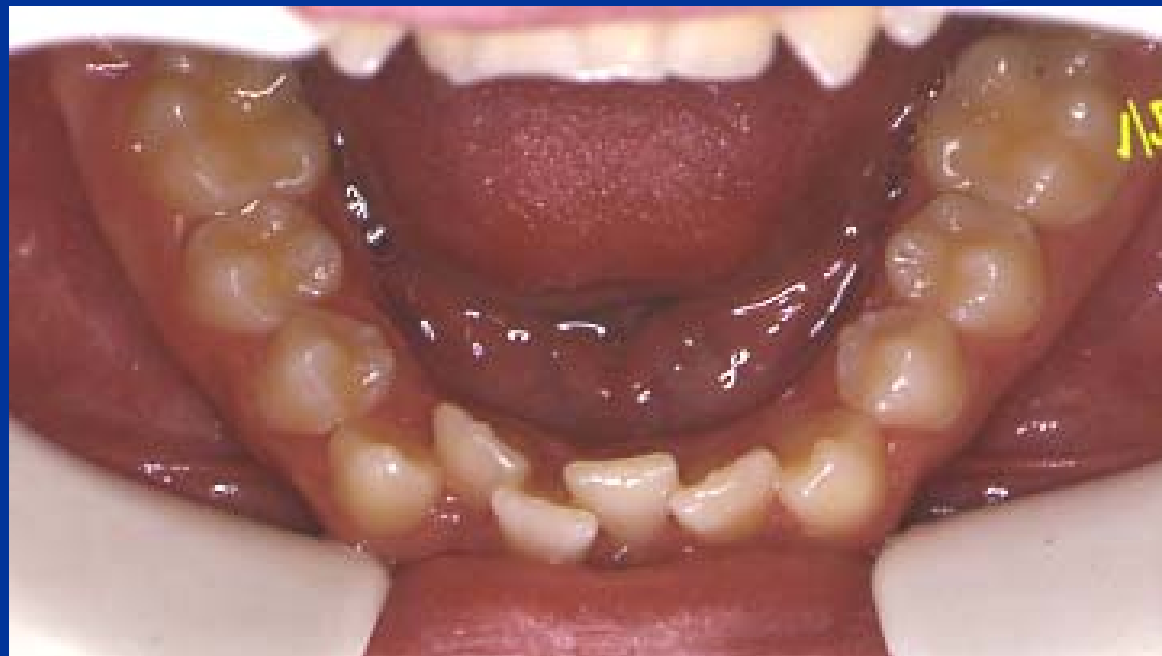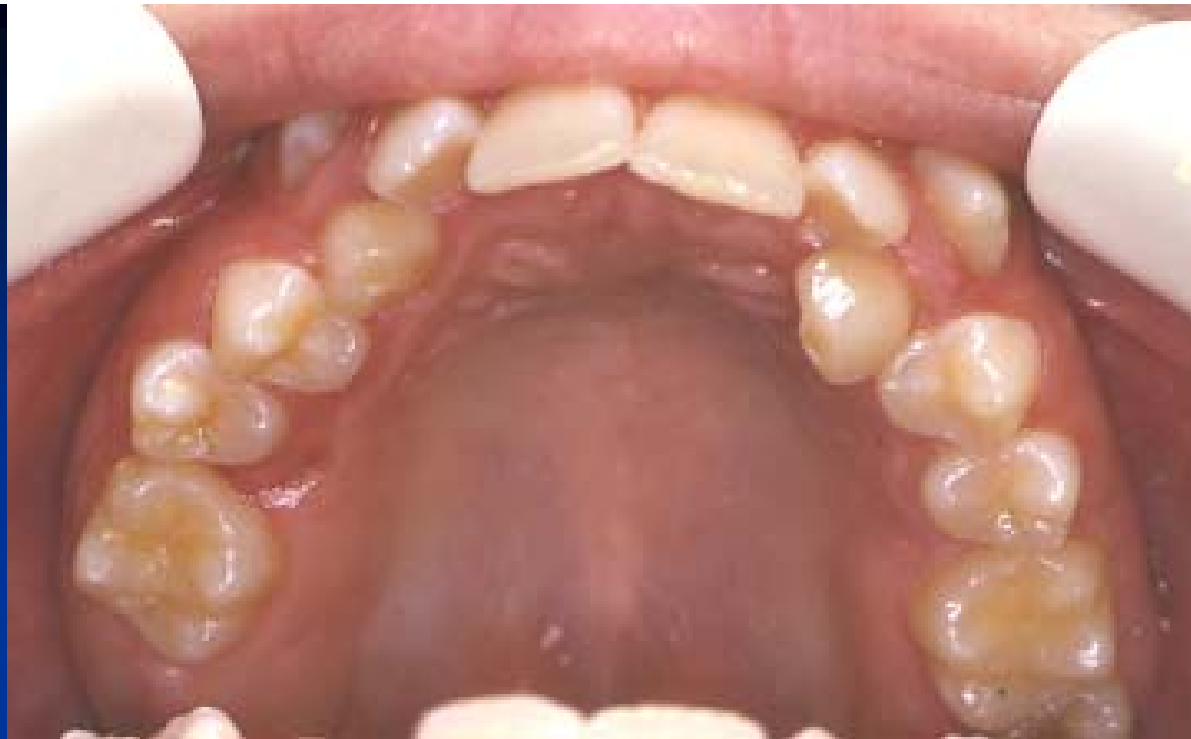- affollamento
- abitudini viziate
- fratture e/o avulsioni traumatiche
- discrepanza nei tre piani dello spazio

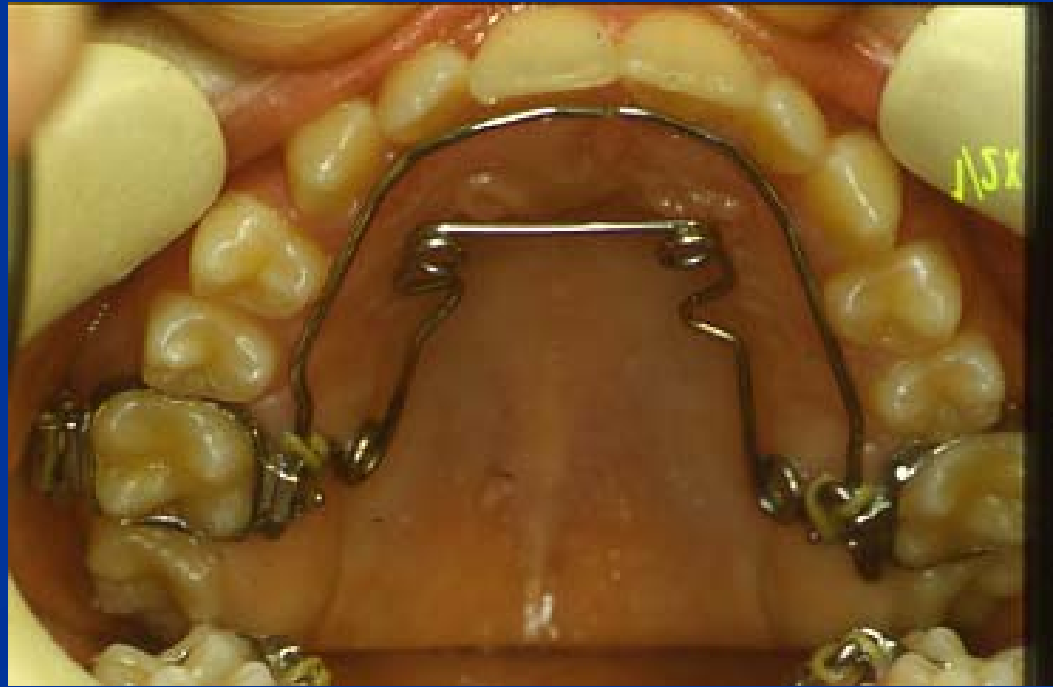
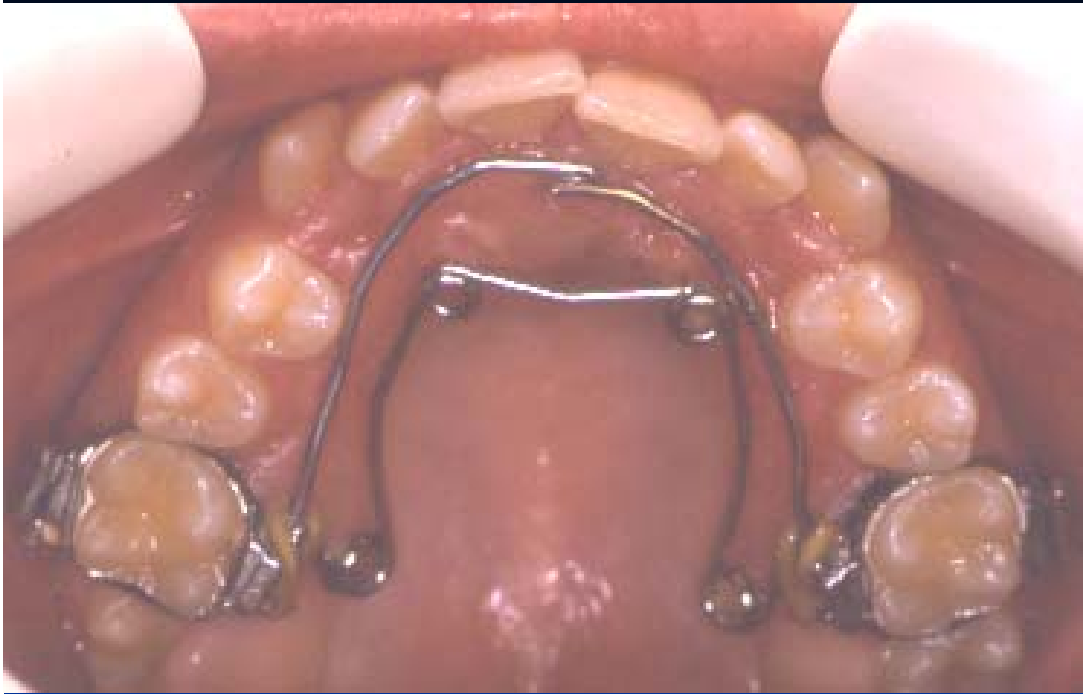


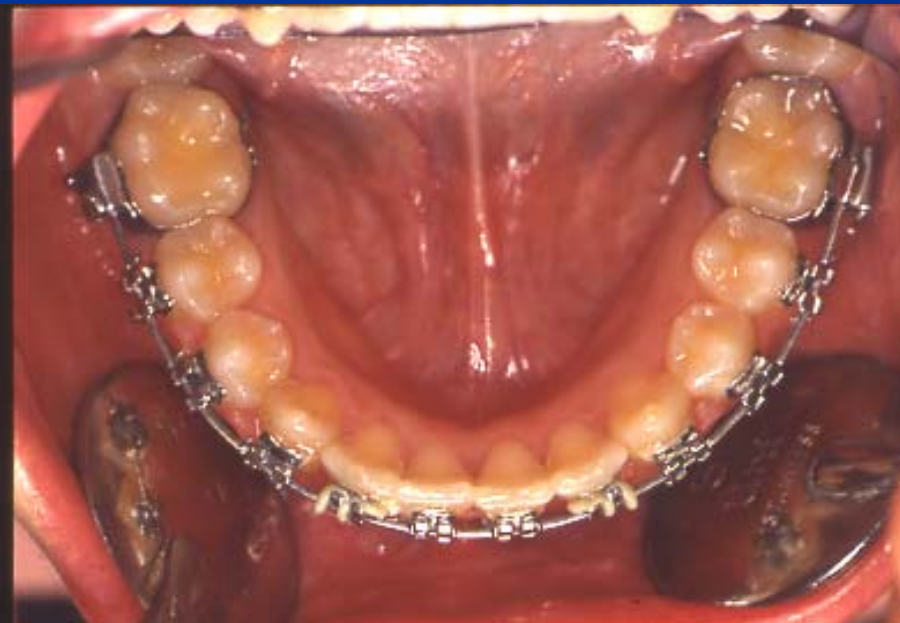
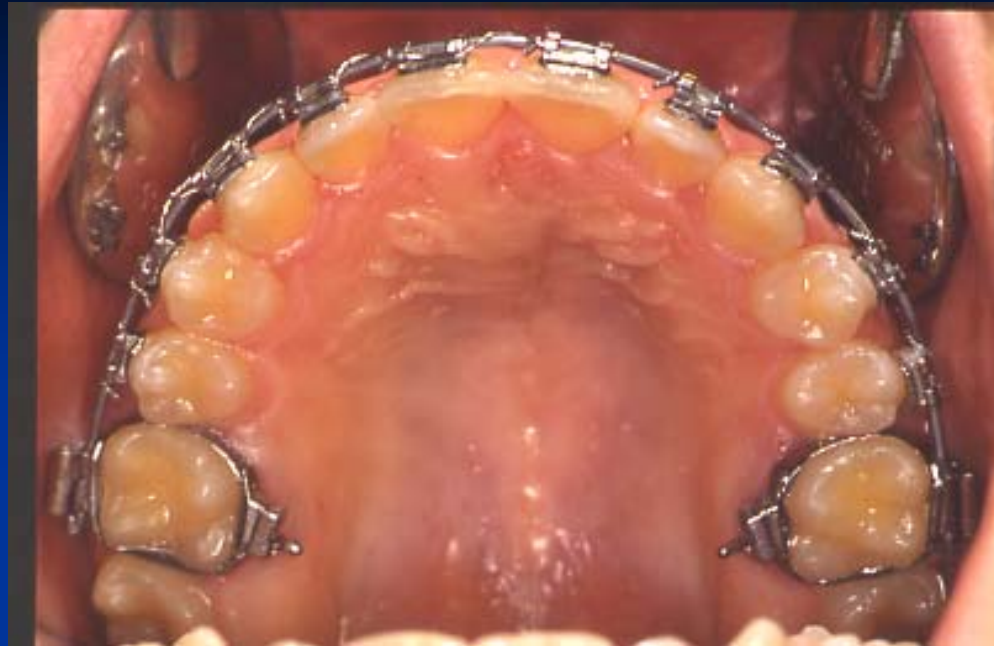


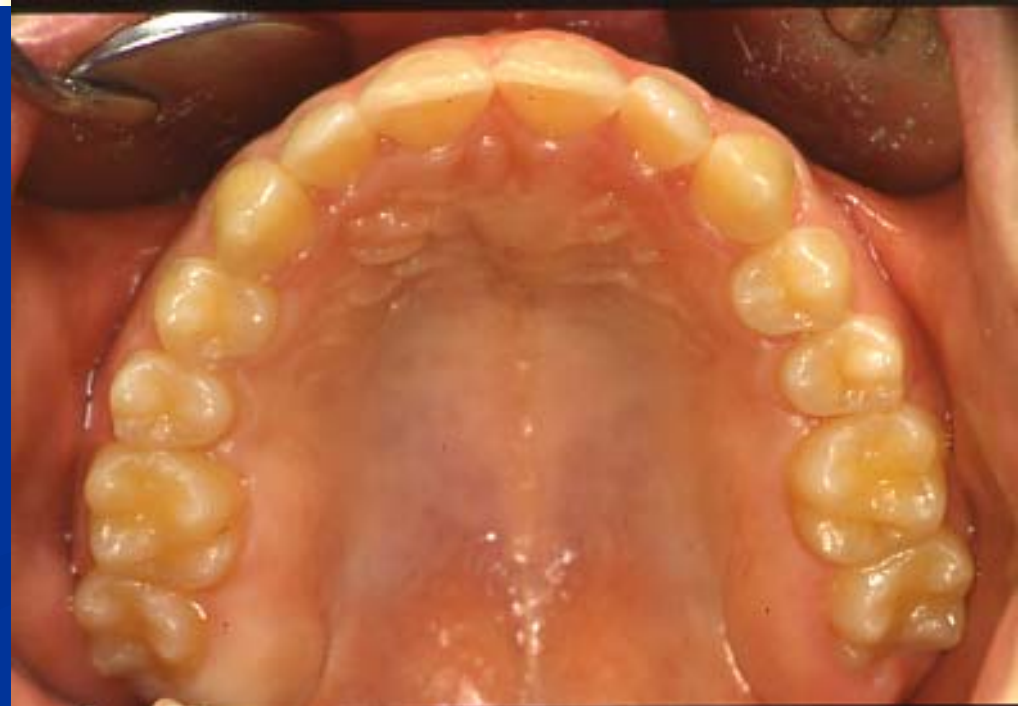
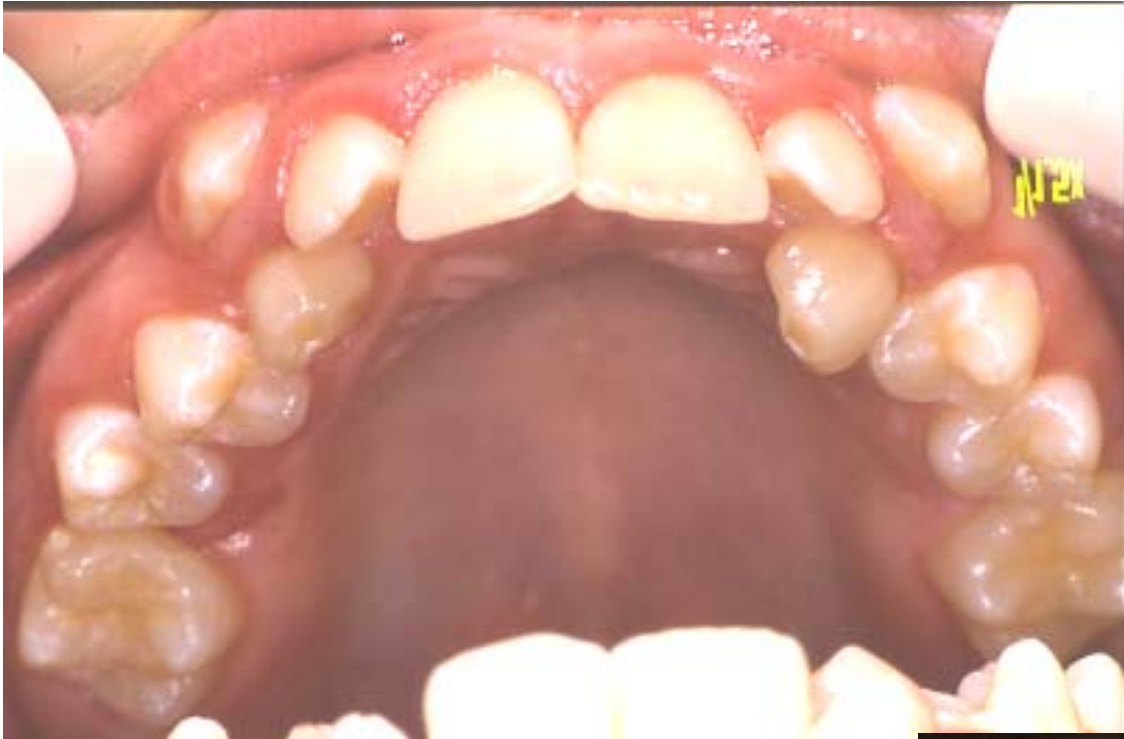


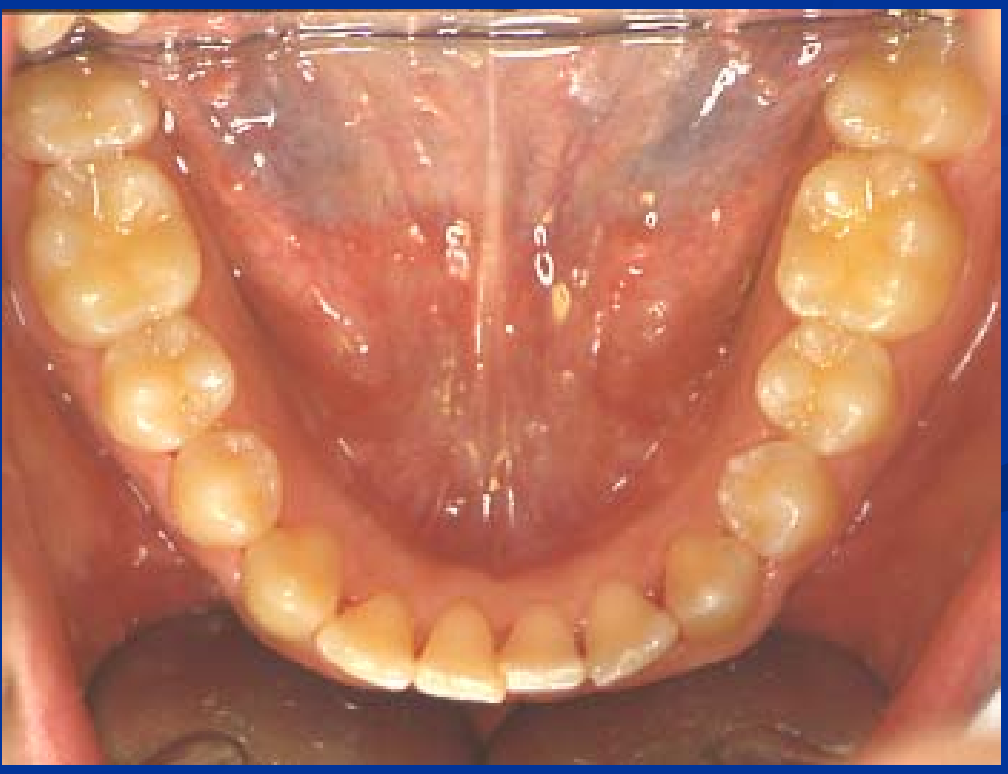
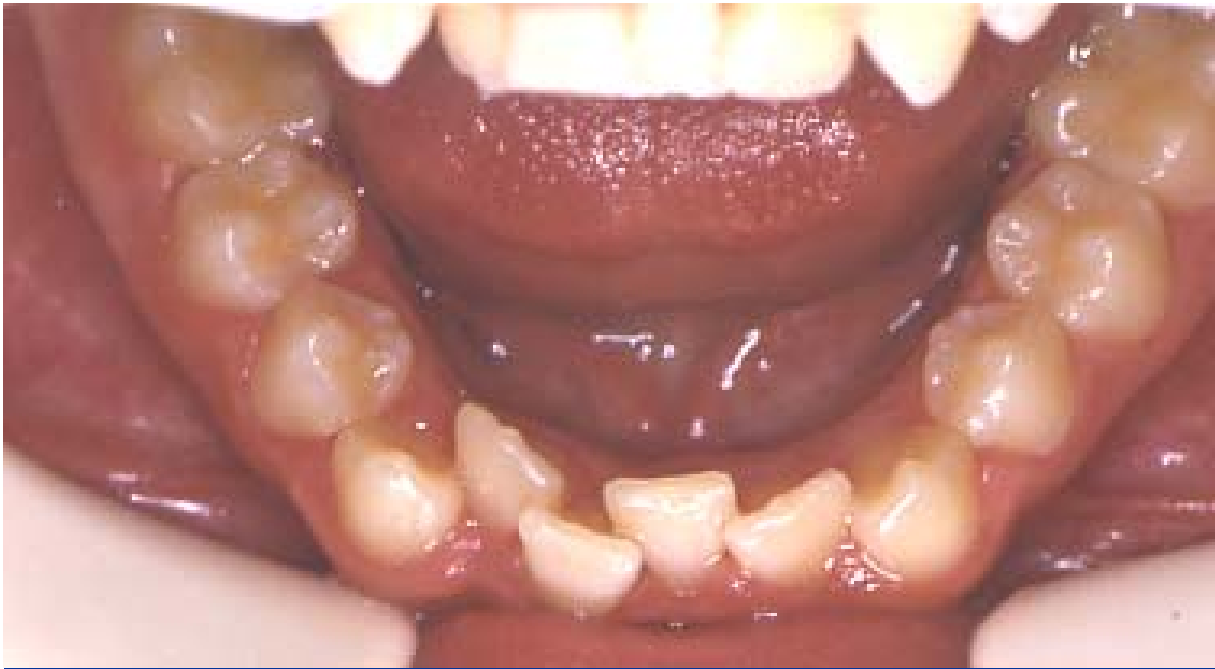


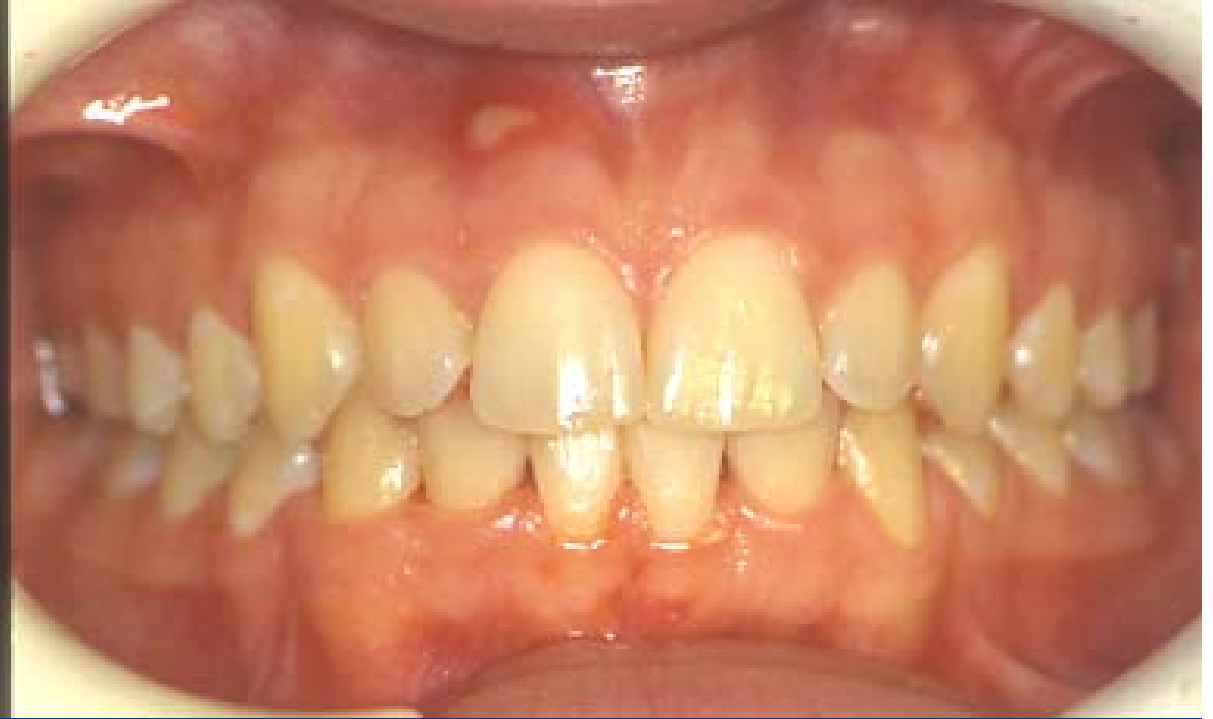
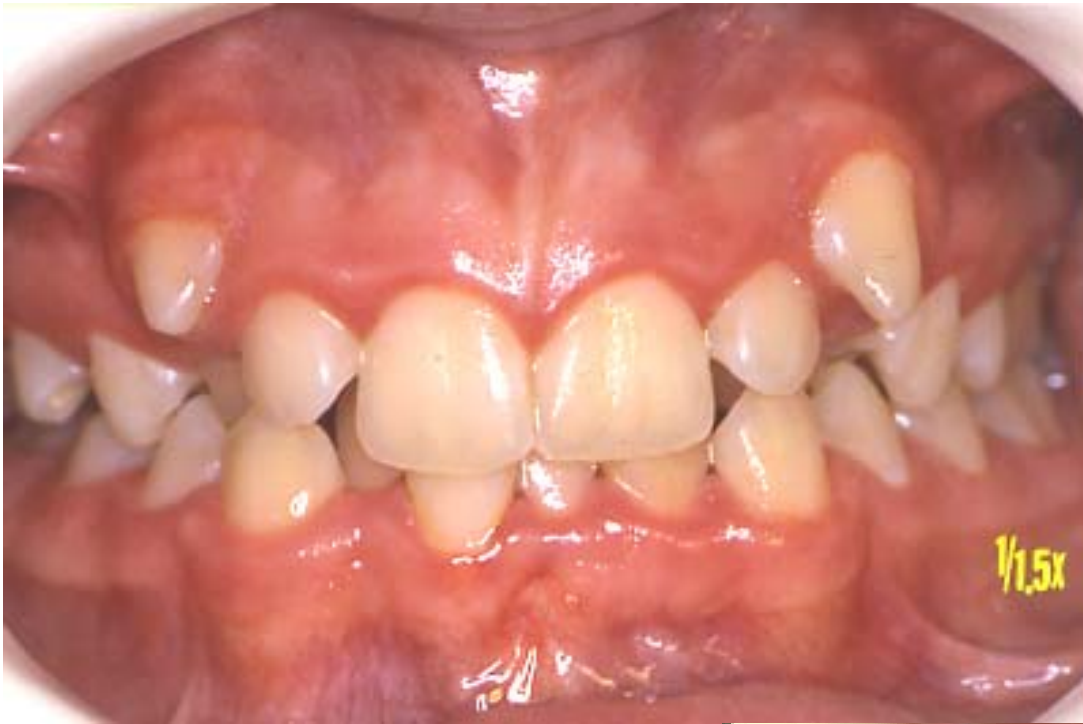






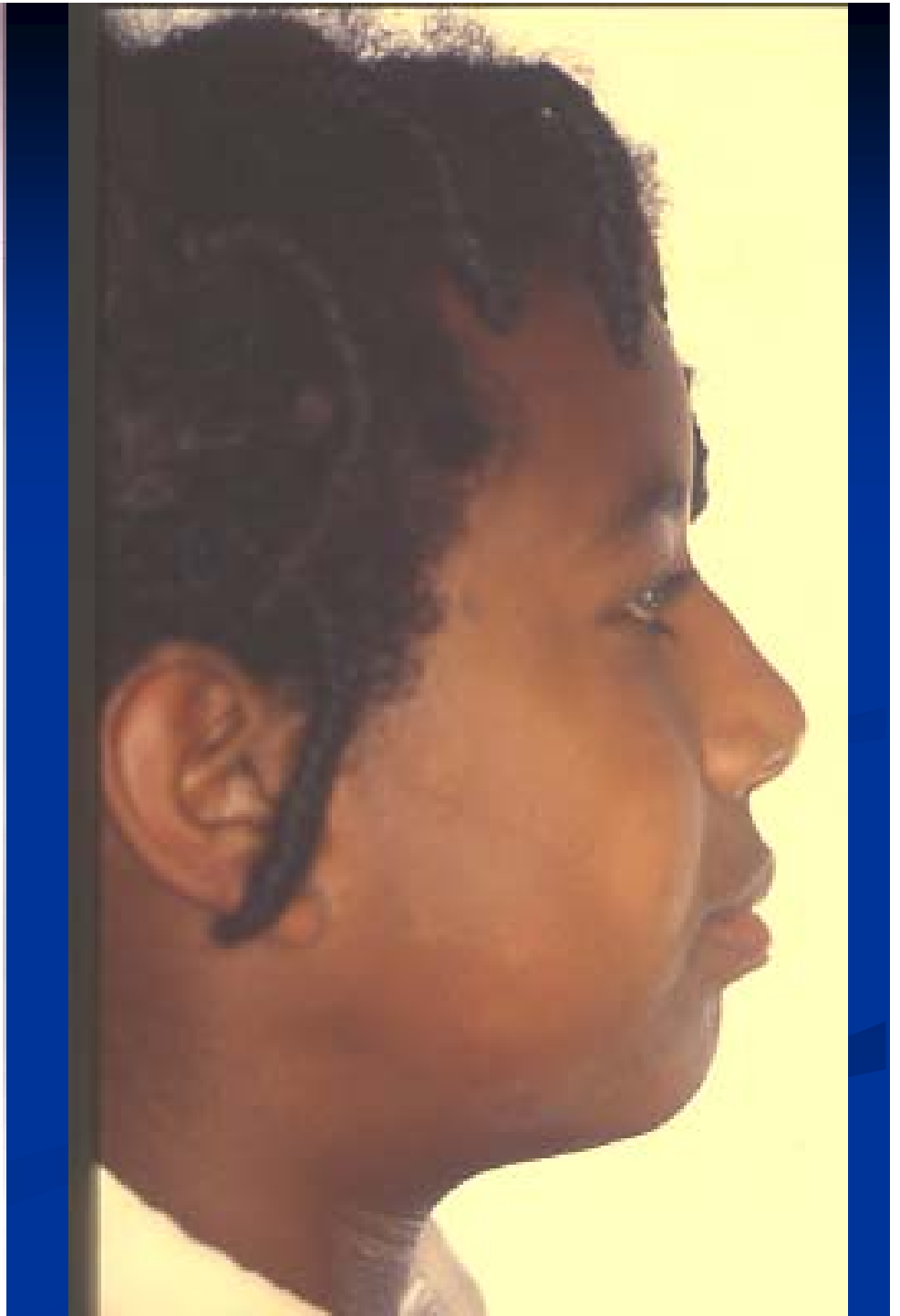
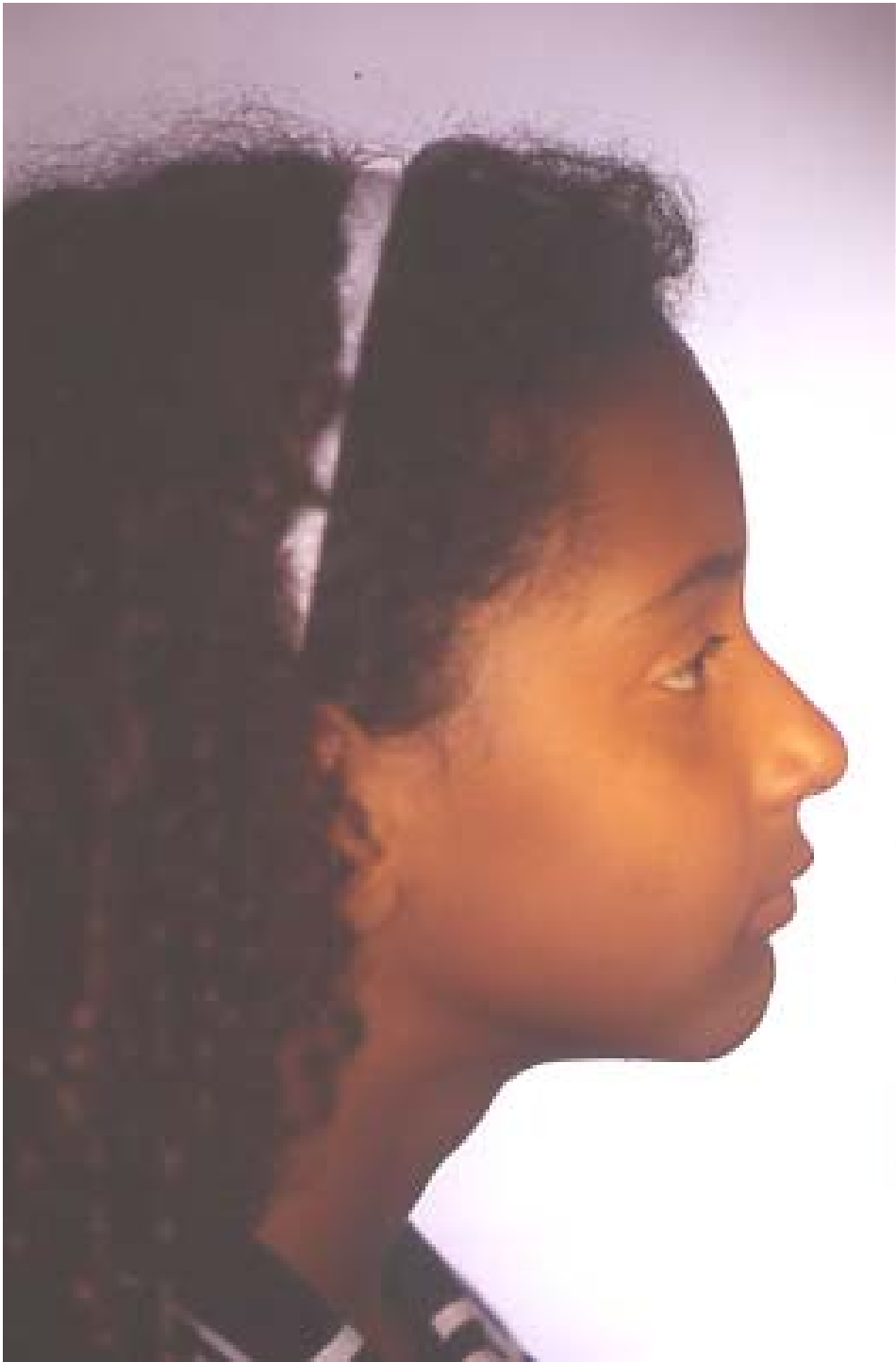


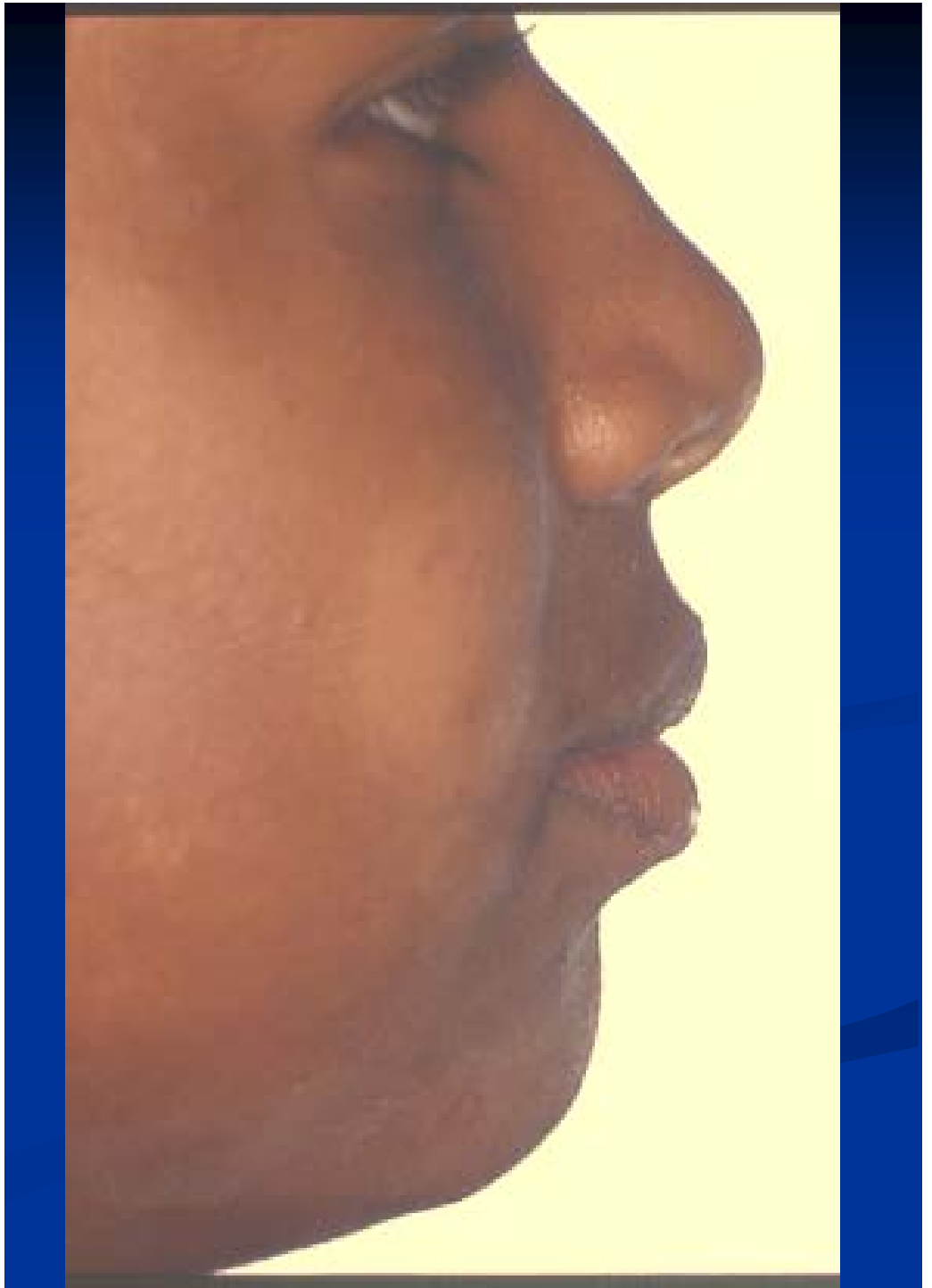
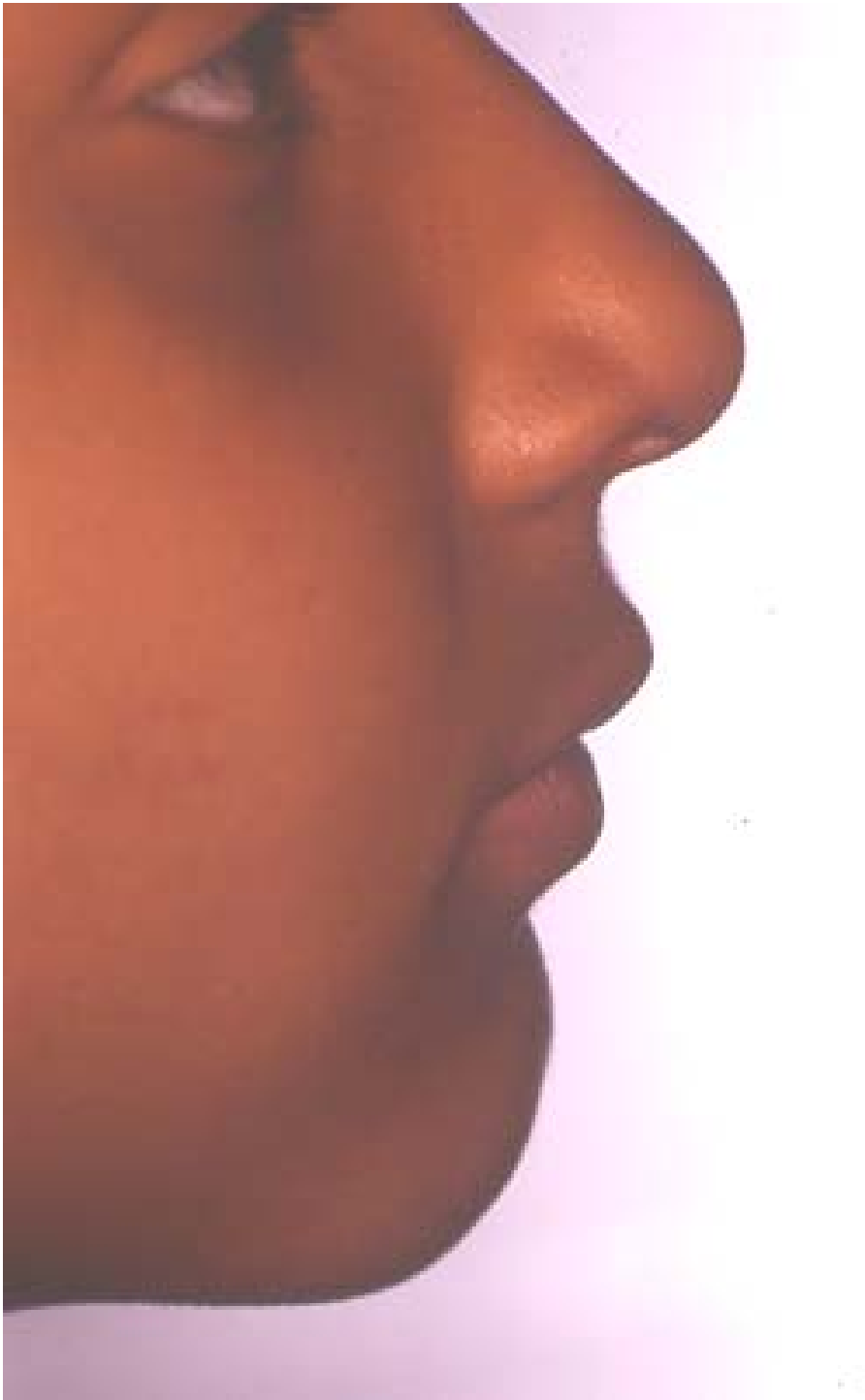
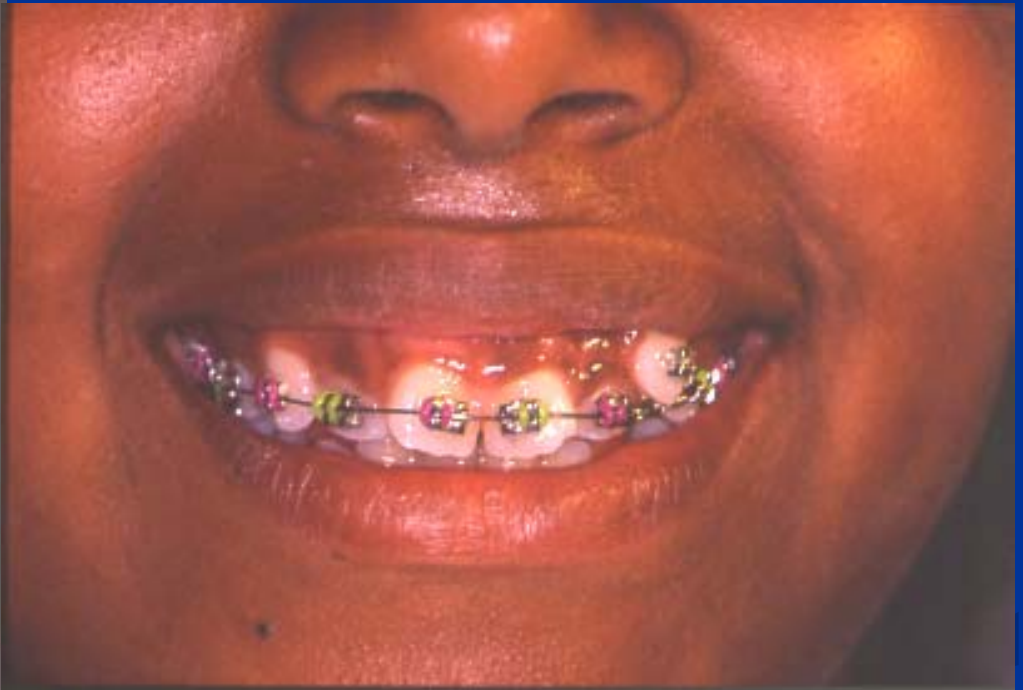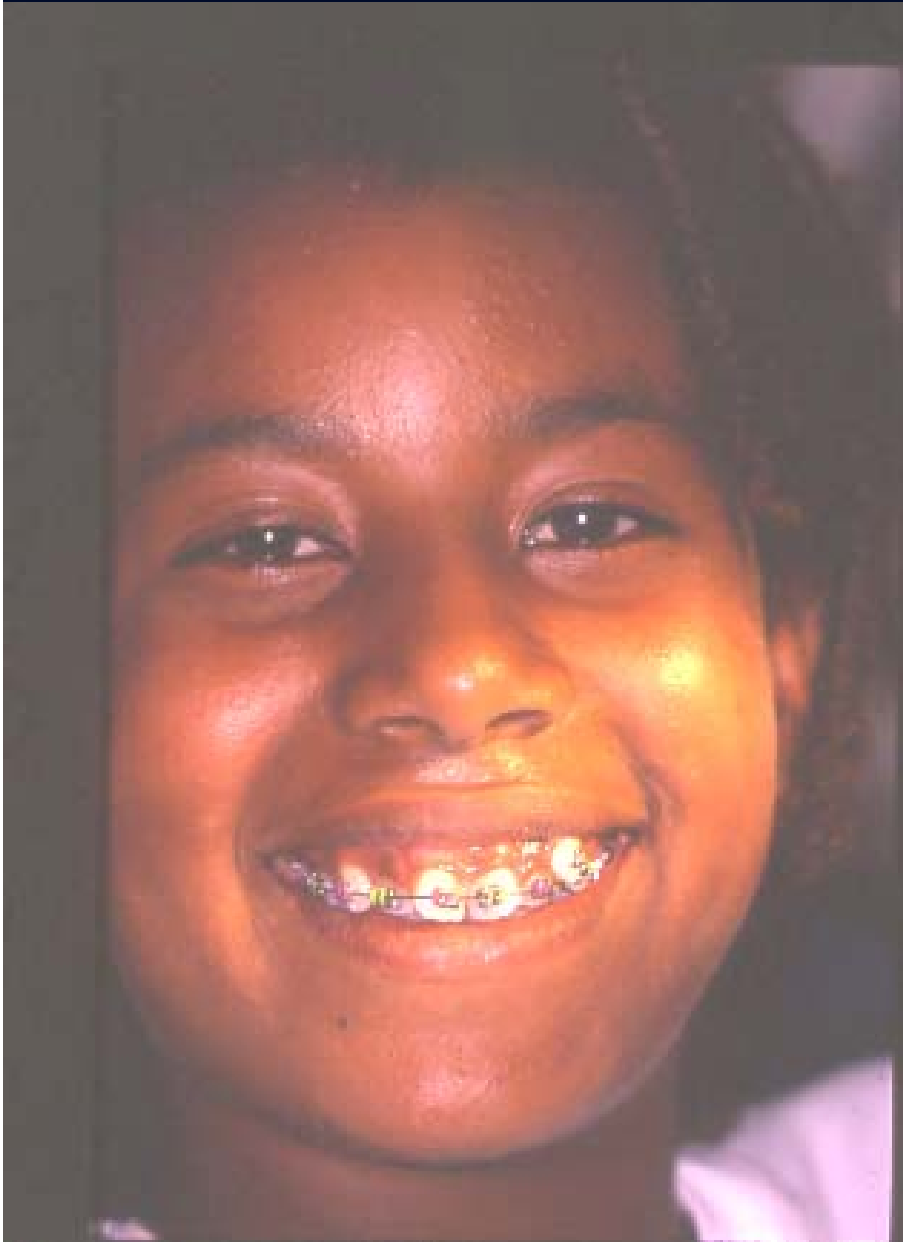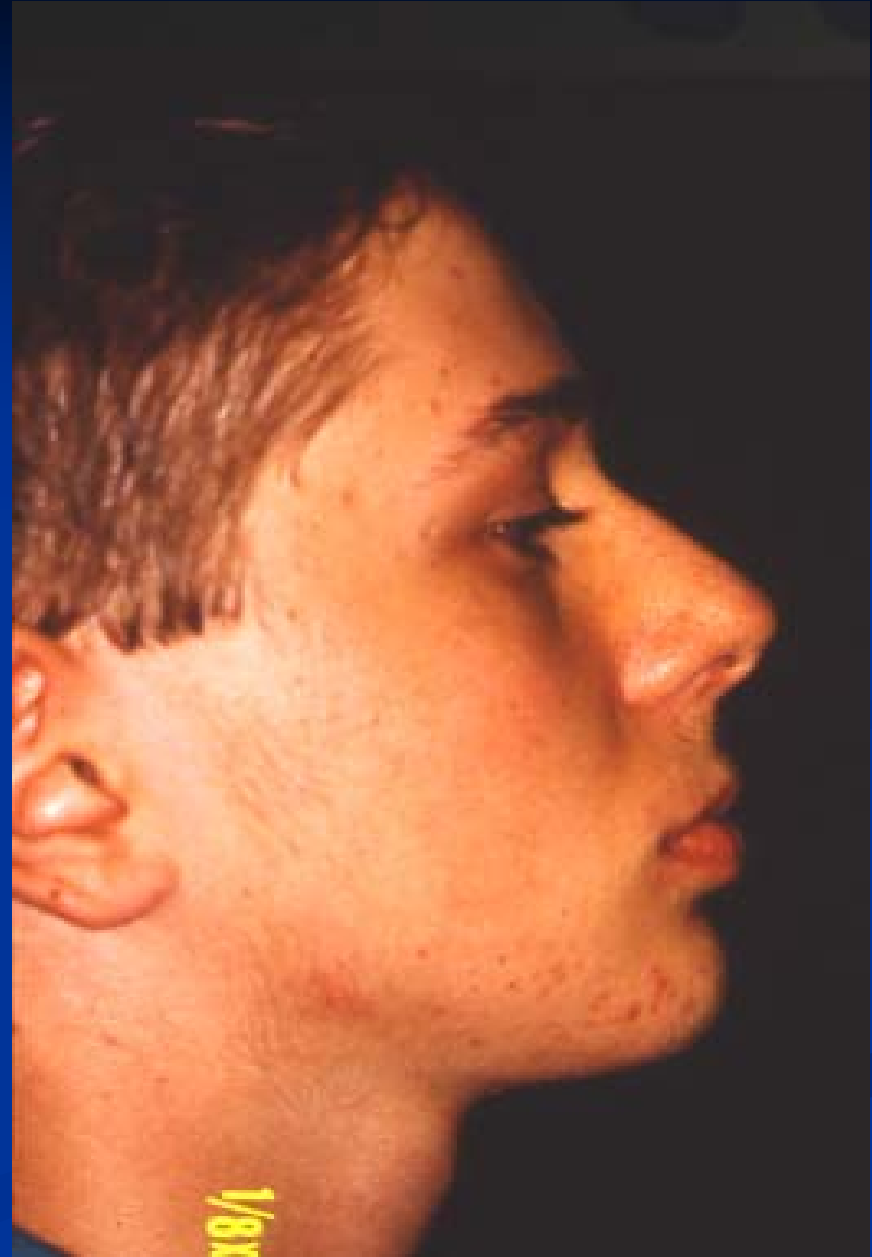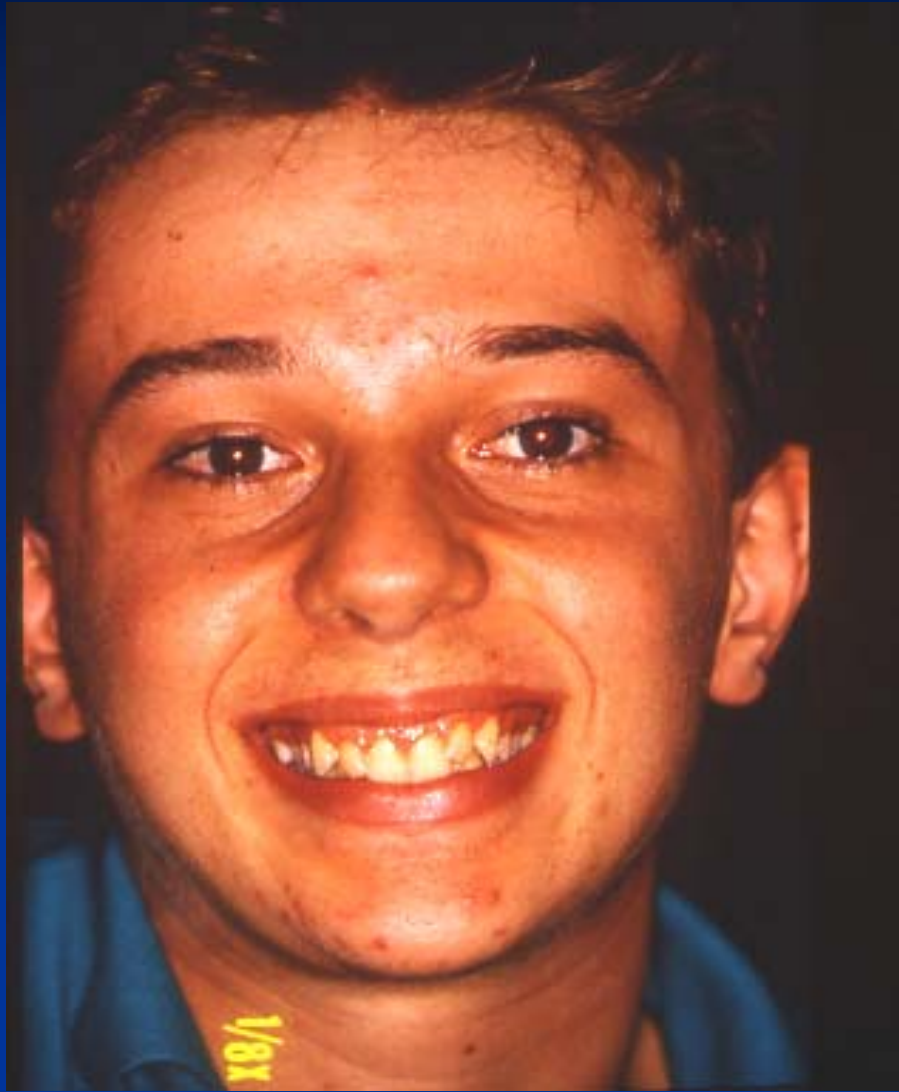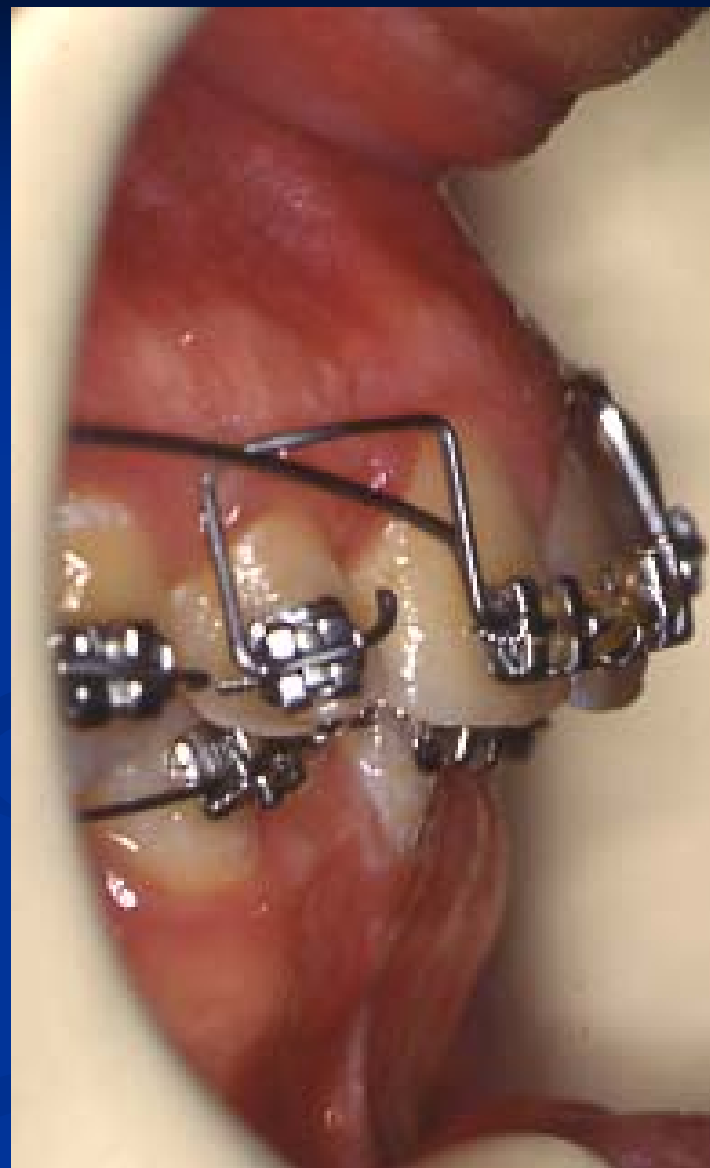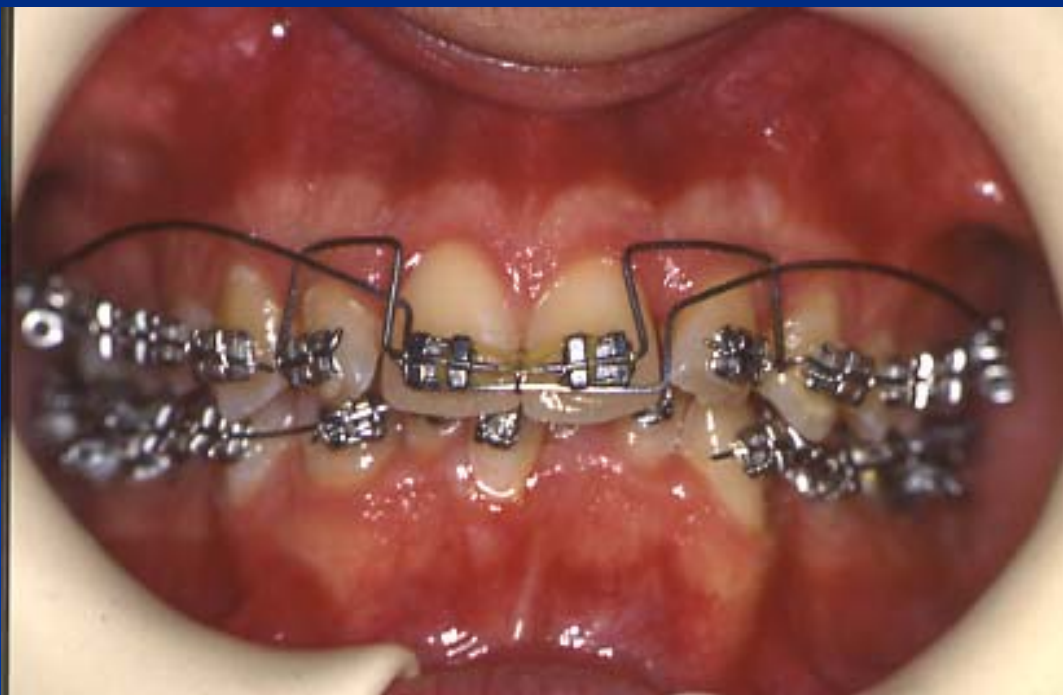# Quando...

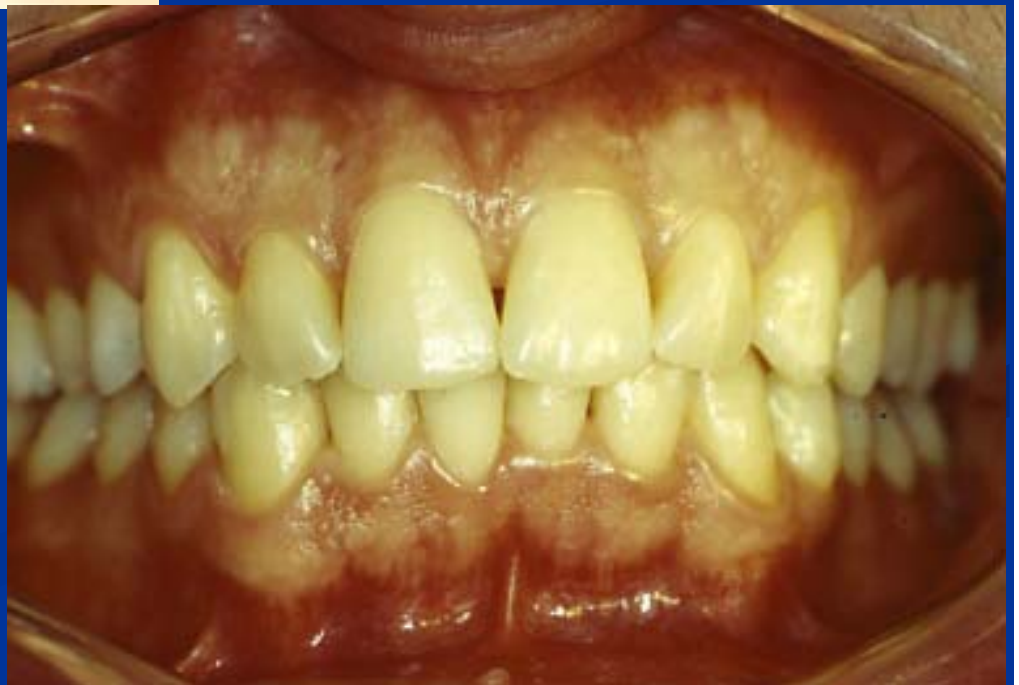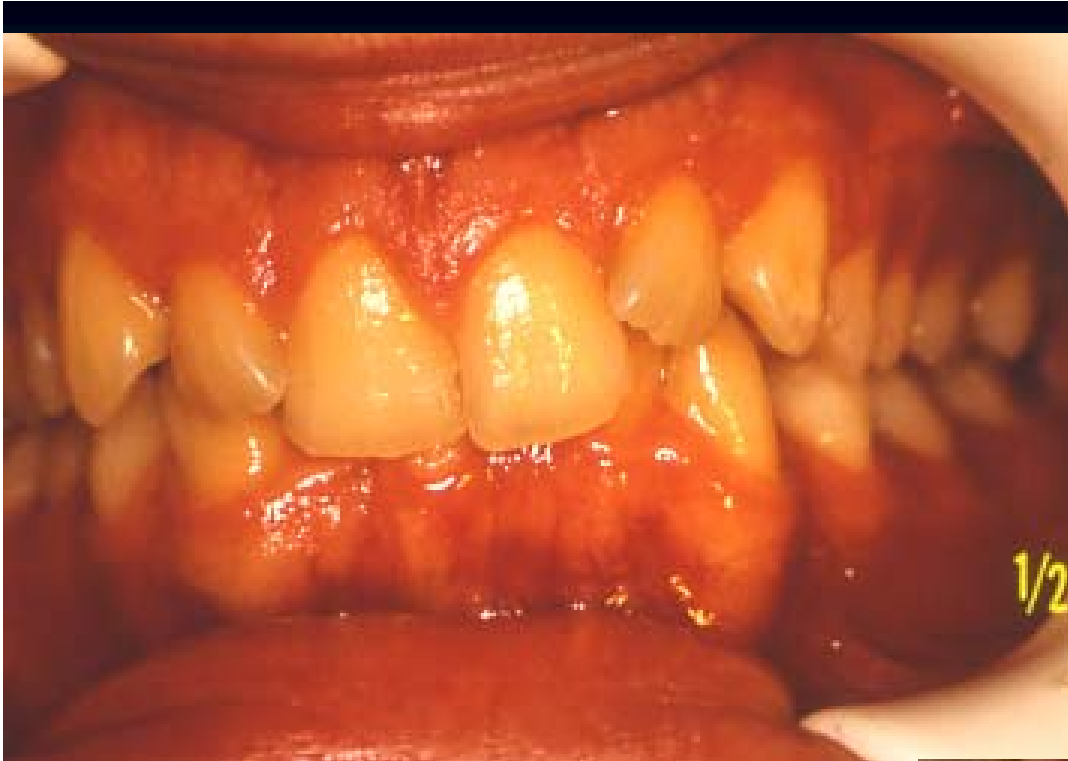## In dentatura permanente

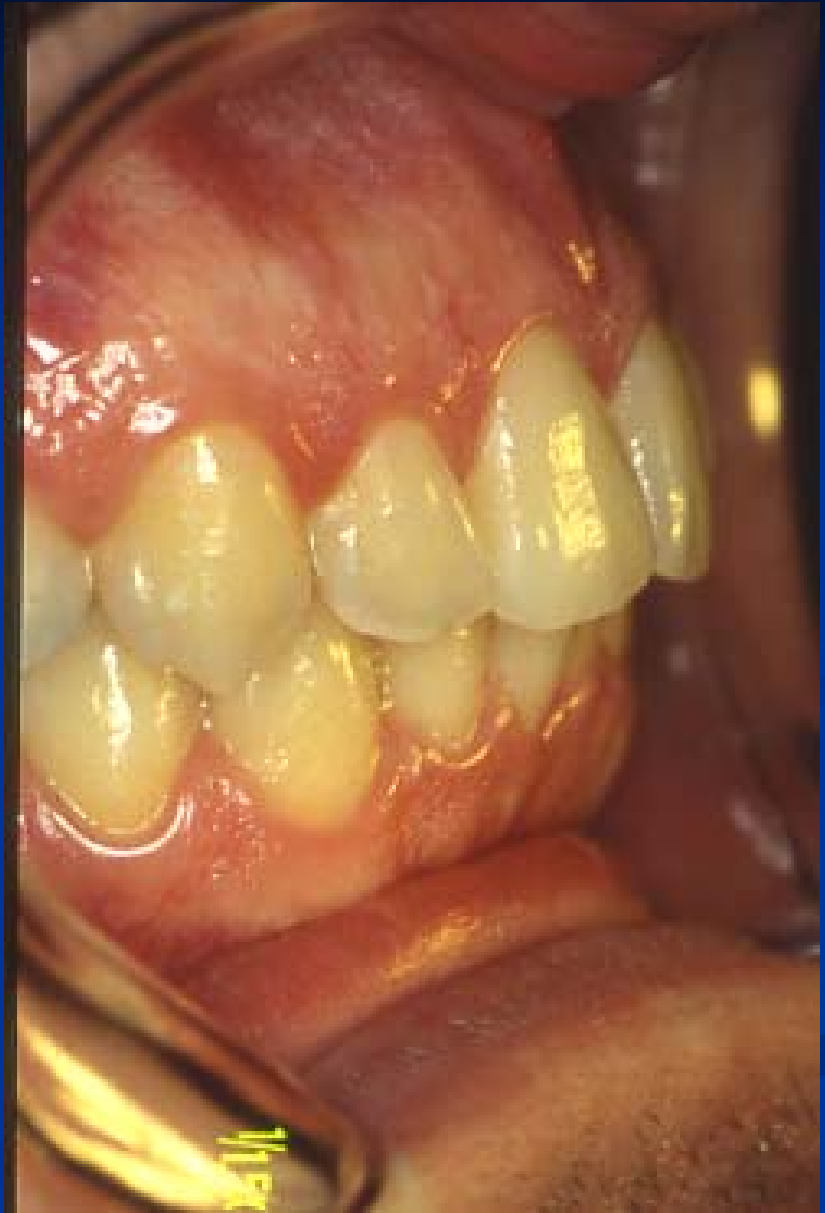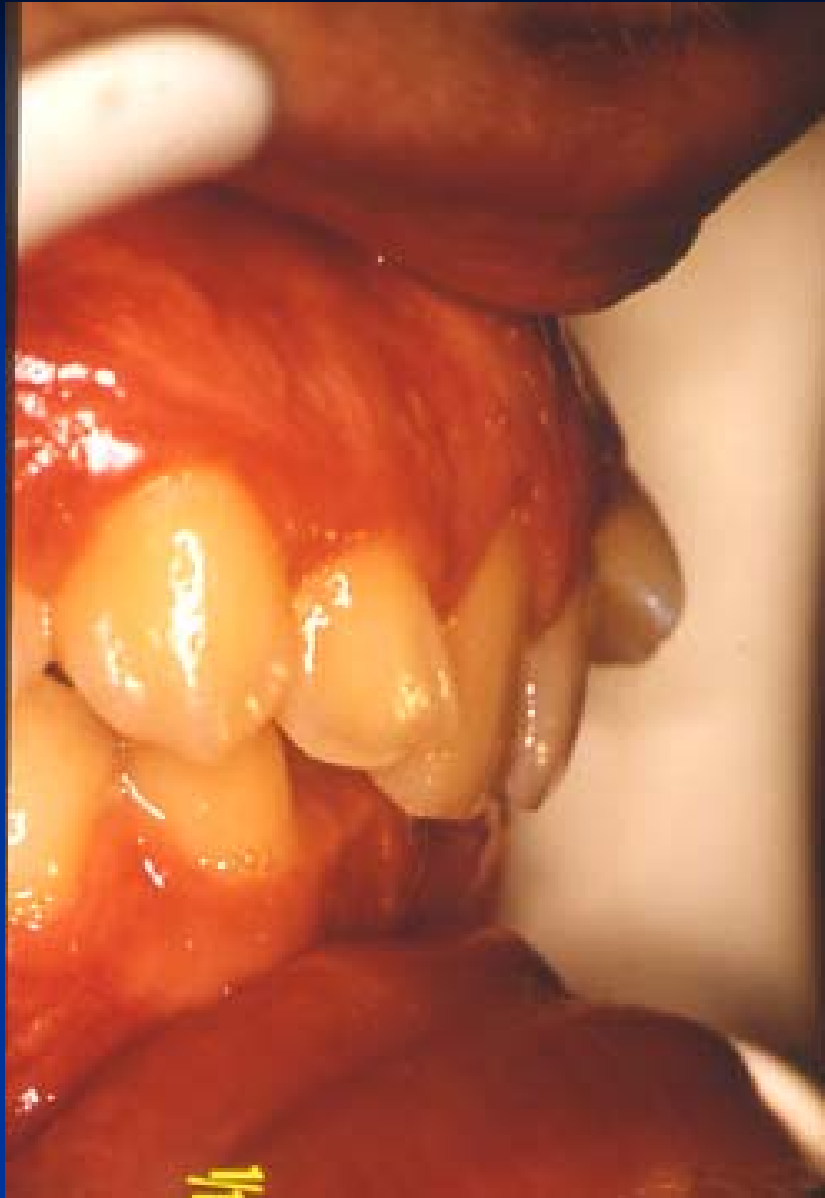- affollamento
- abitudini viziate
- discrepanza nei 3 piani dello spazio

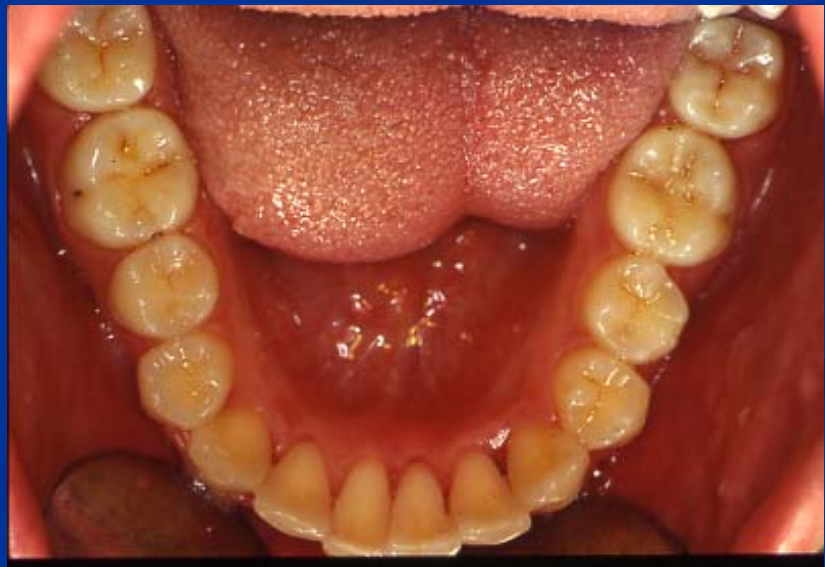
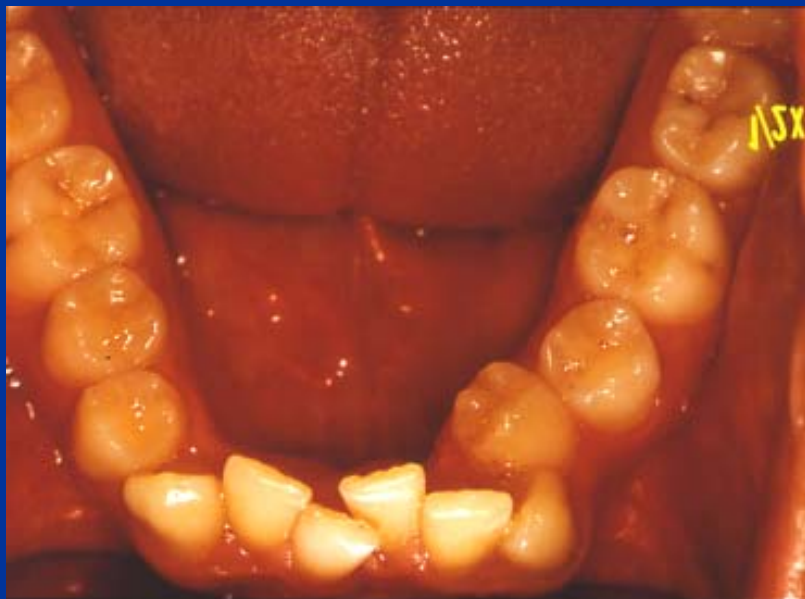
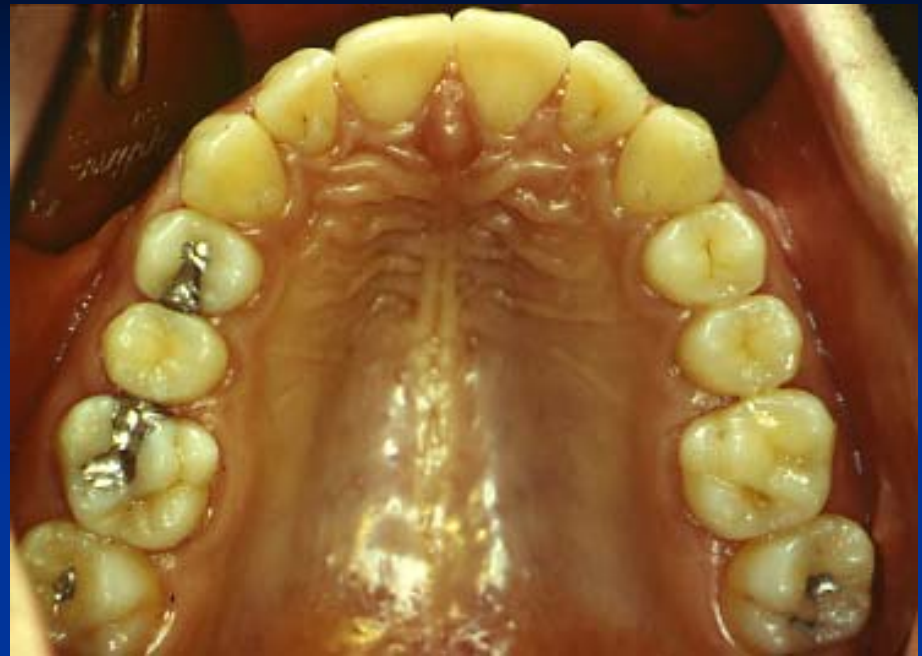
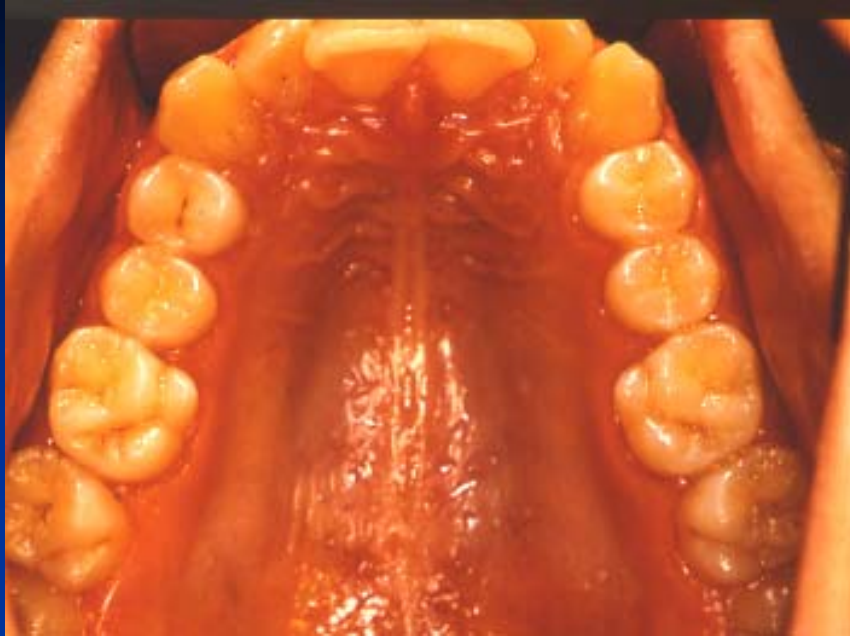


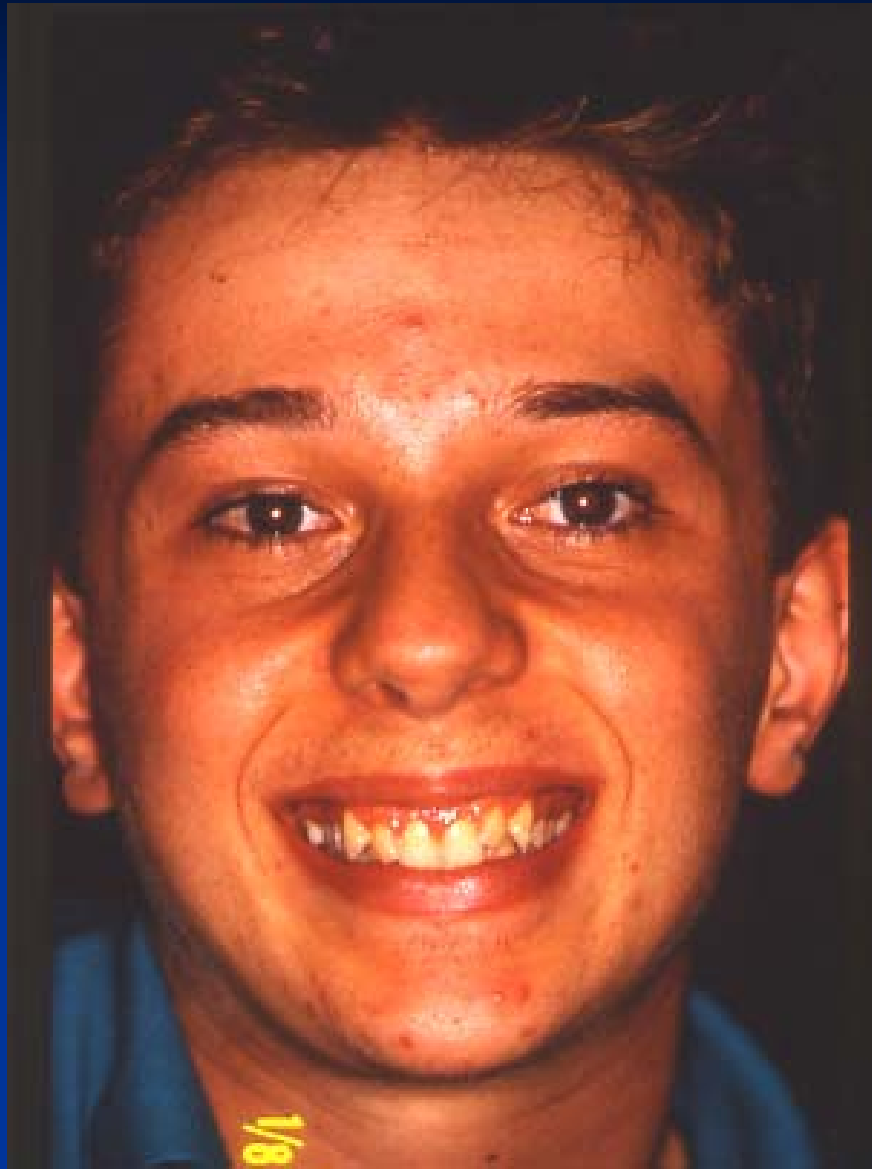




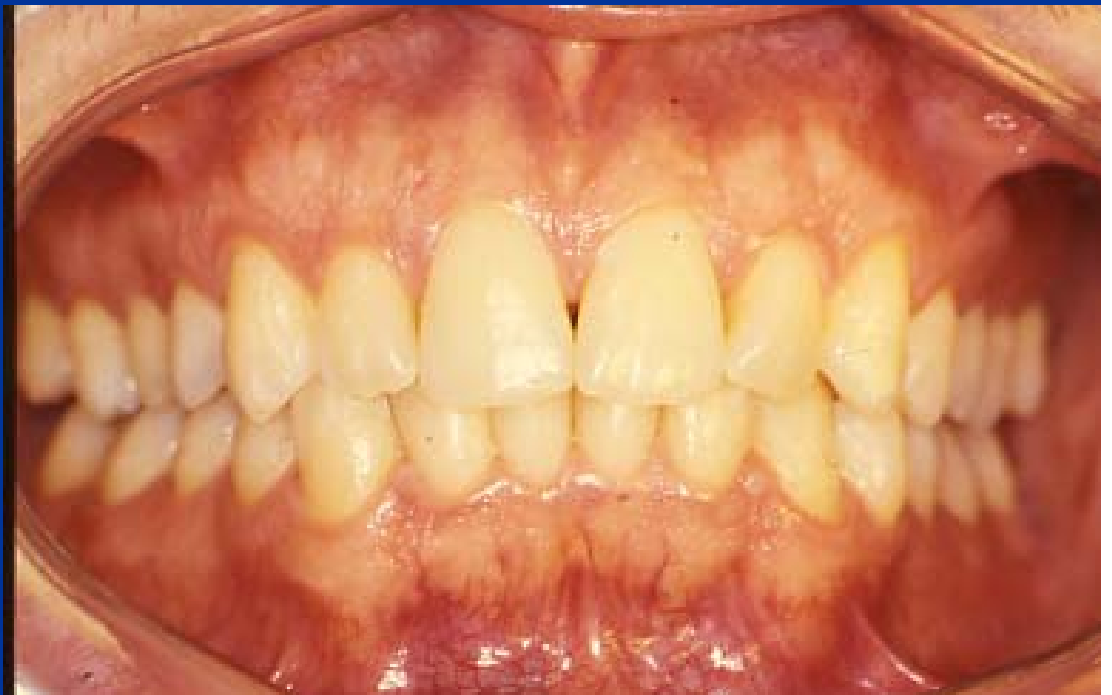
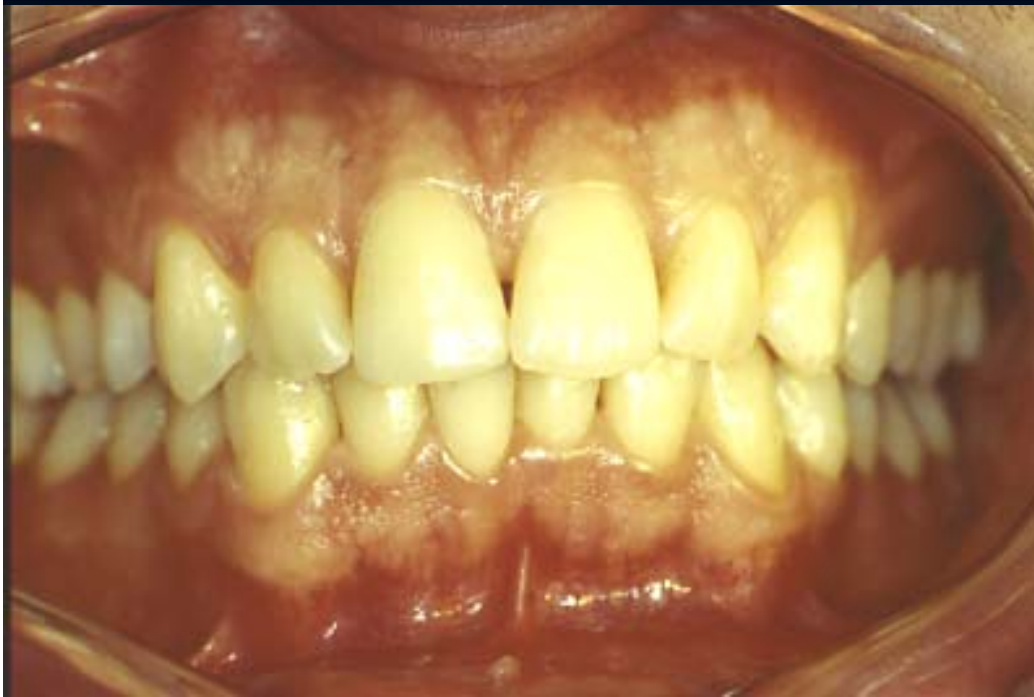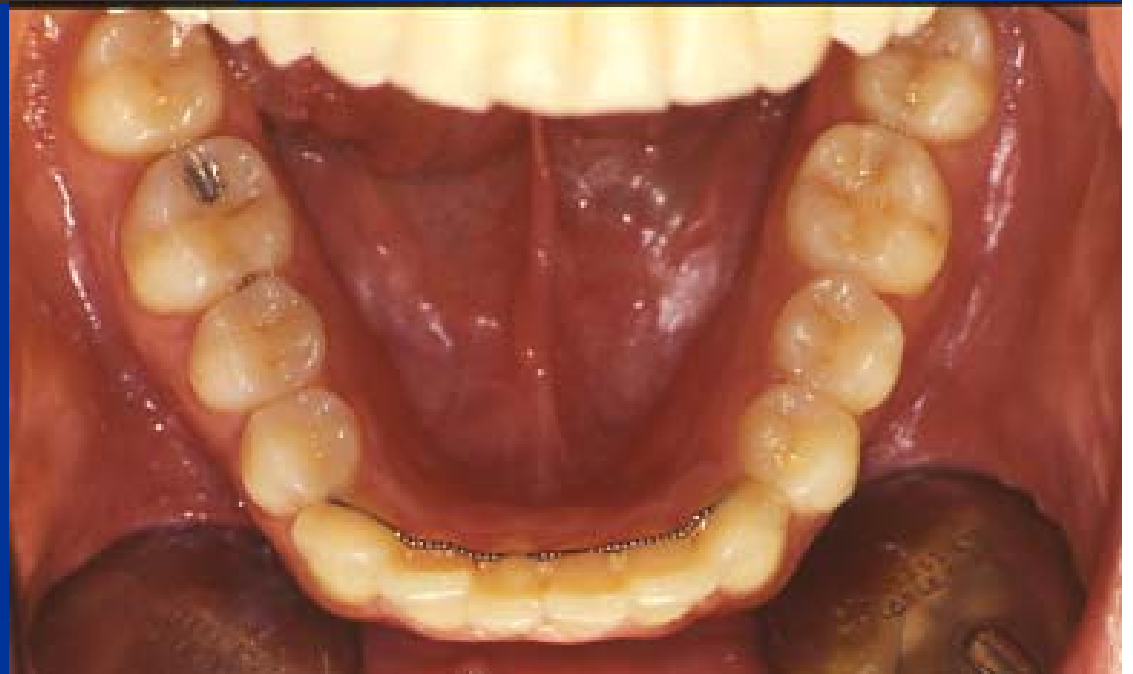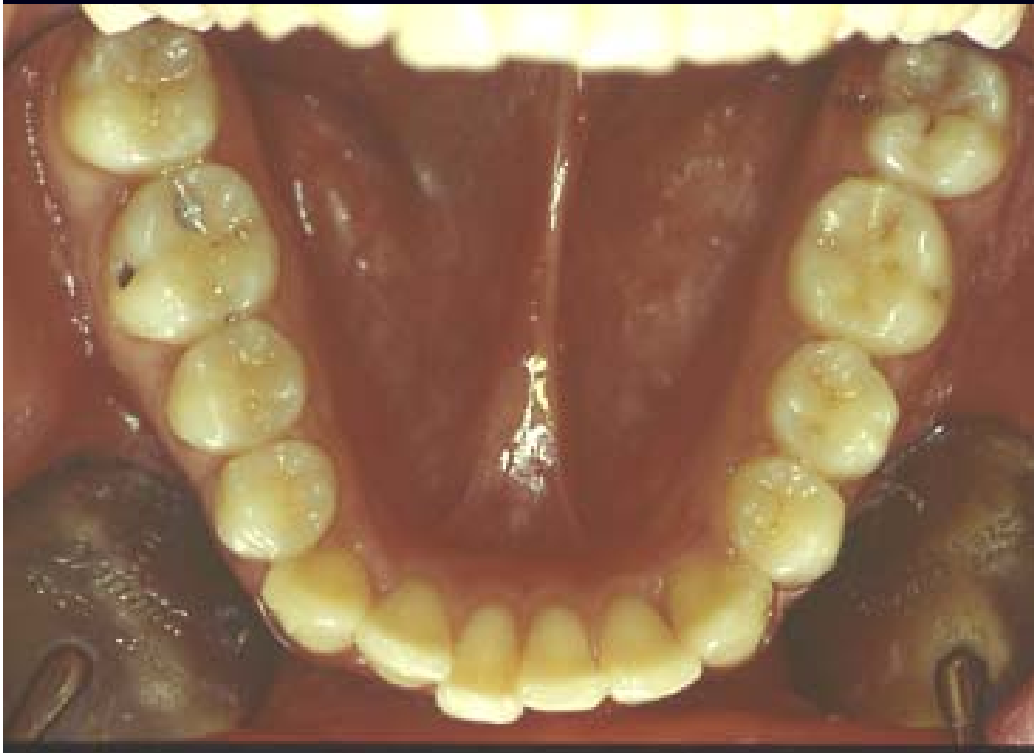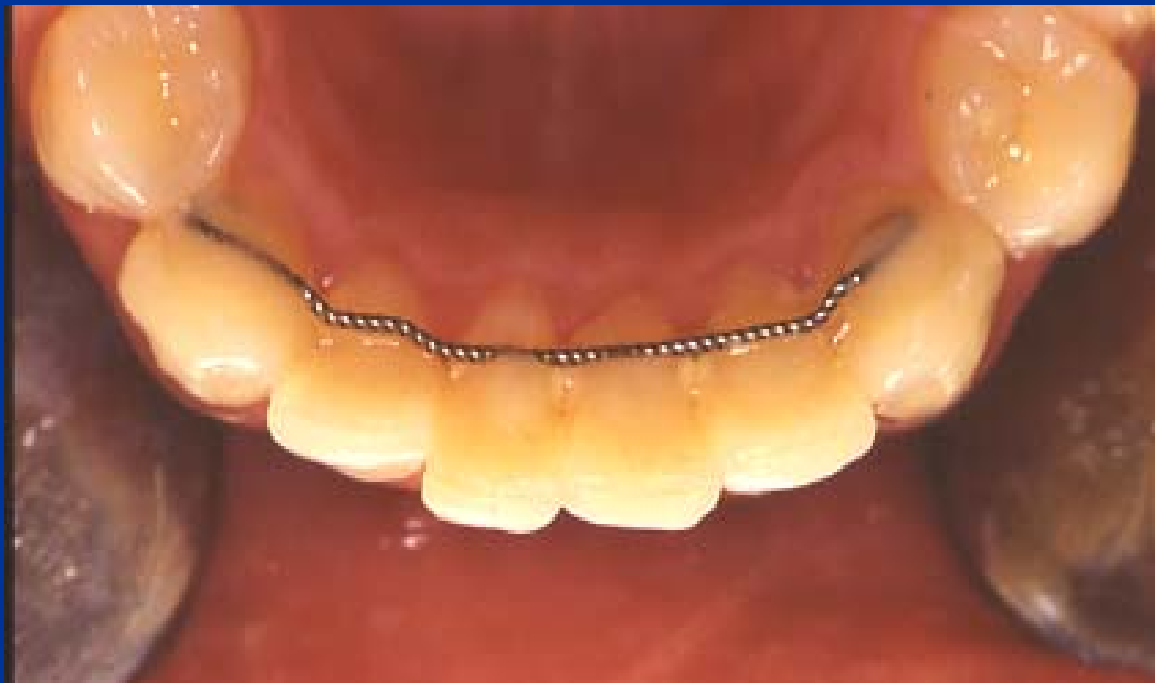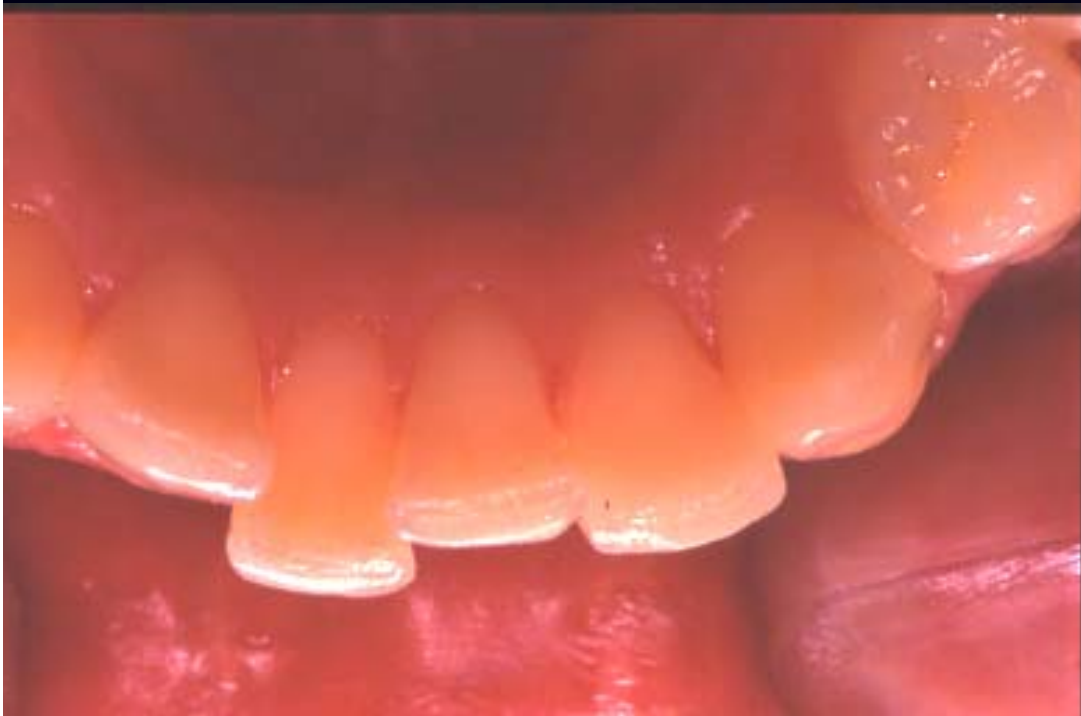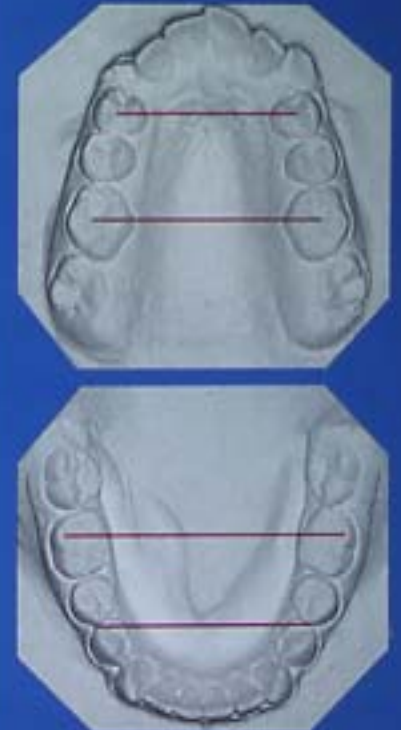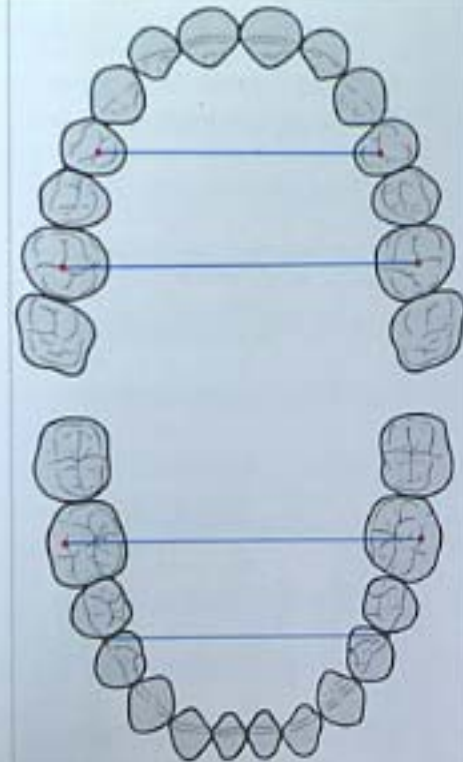












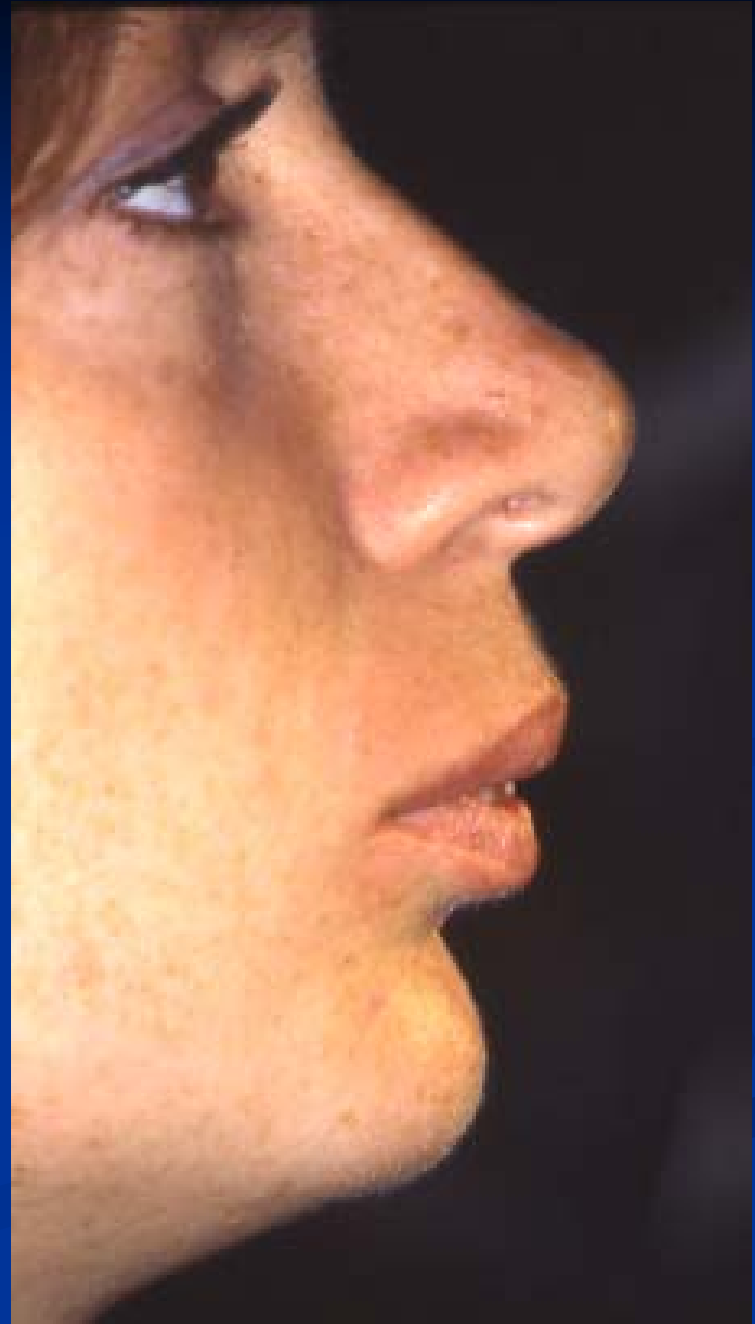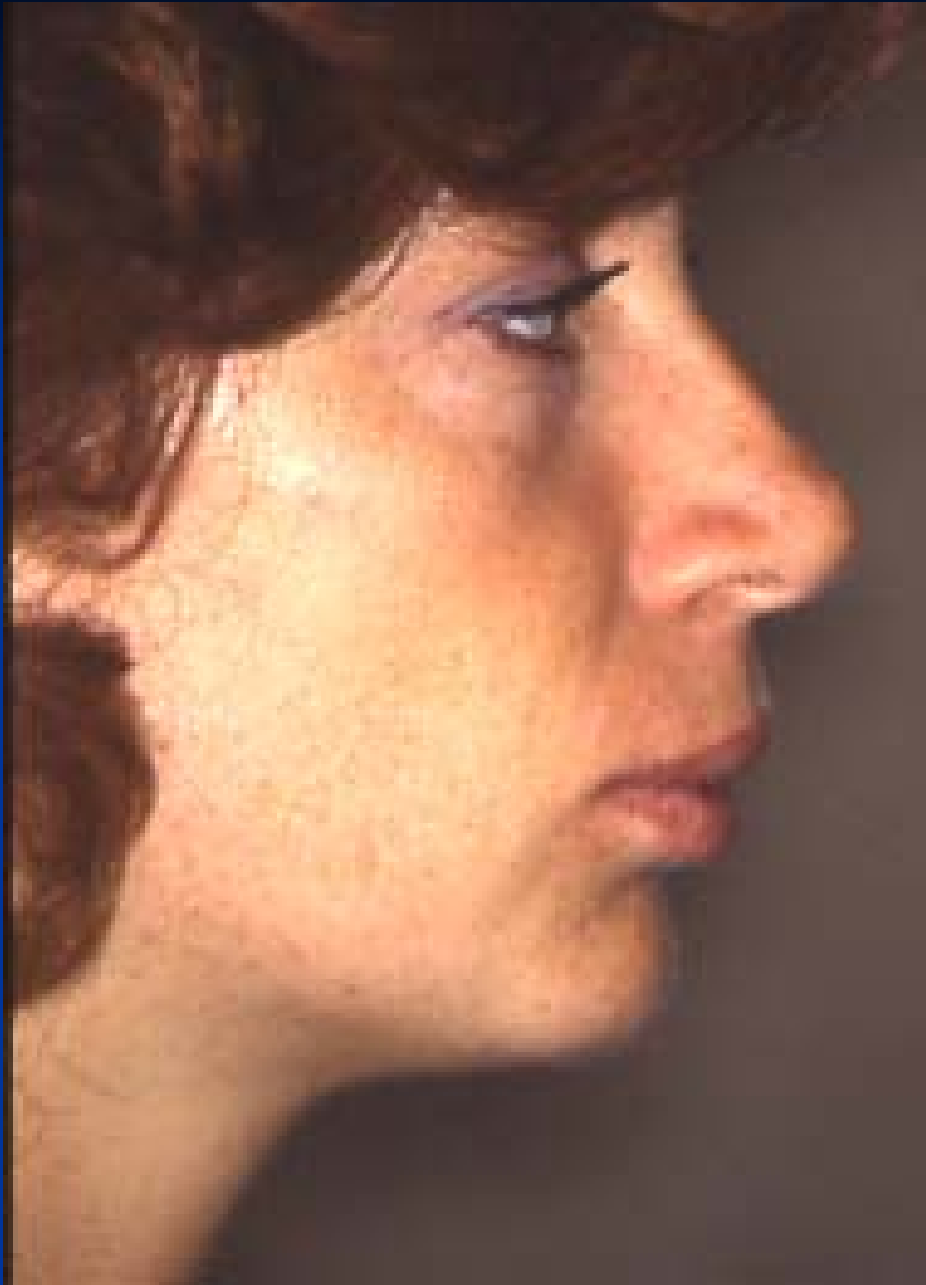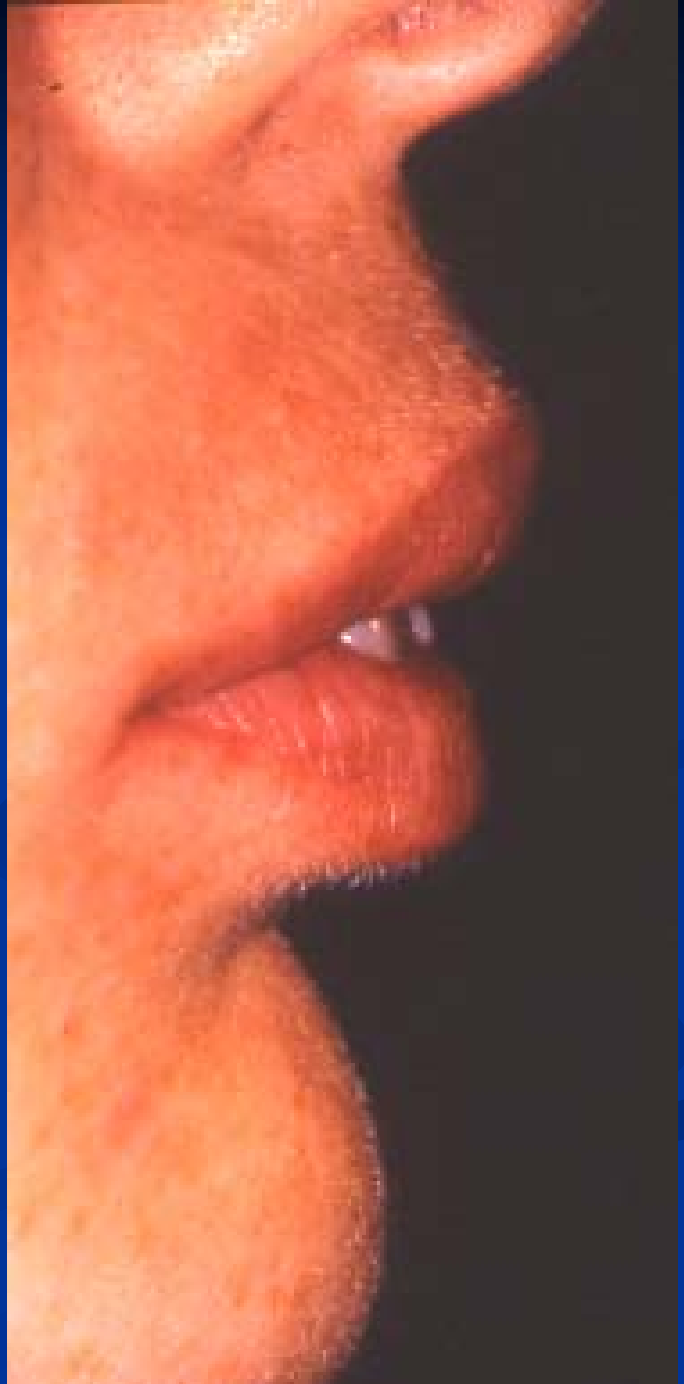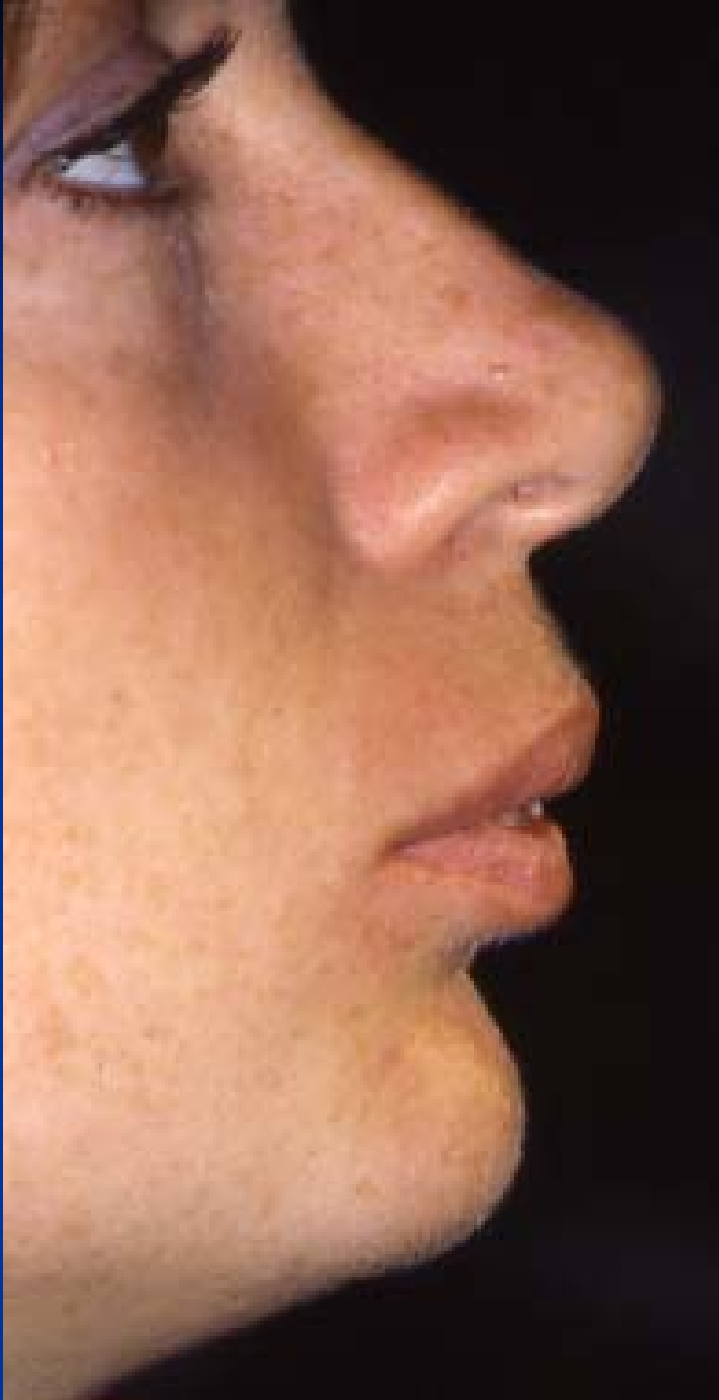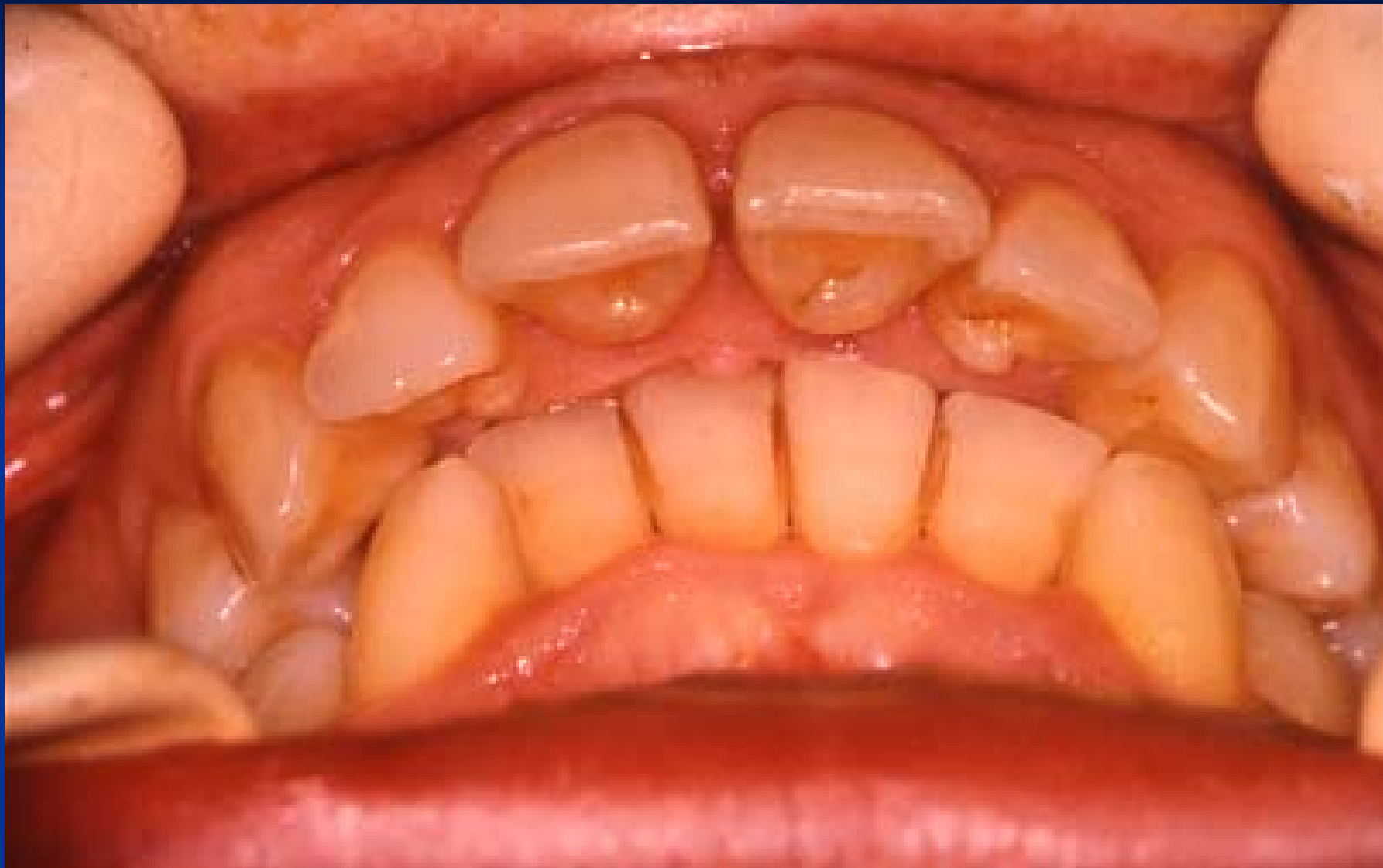# Quando...

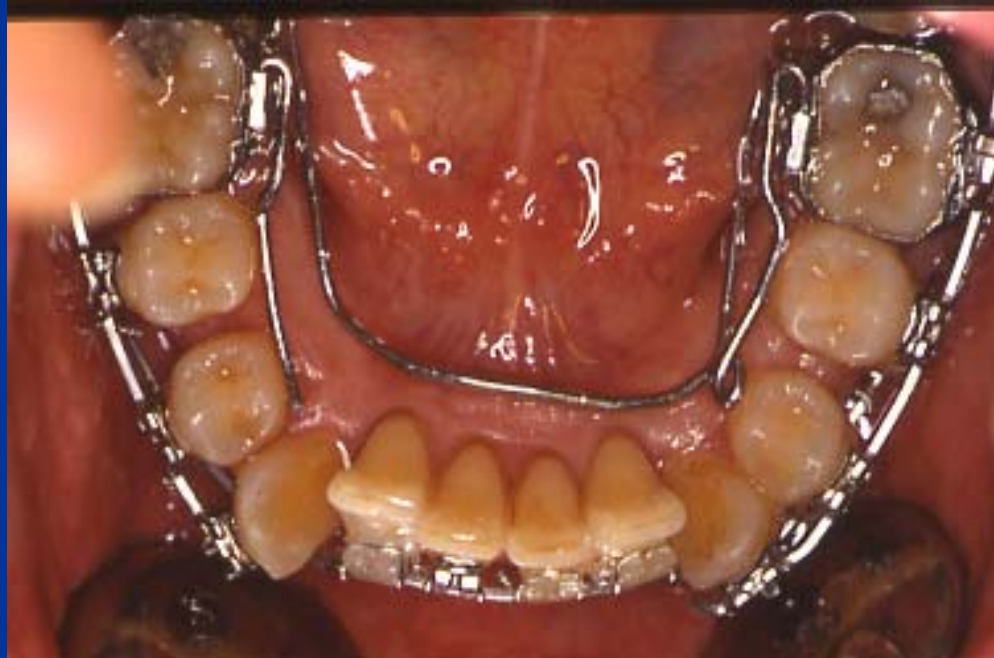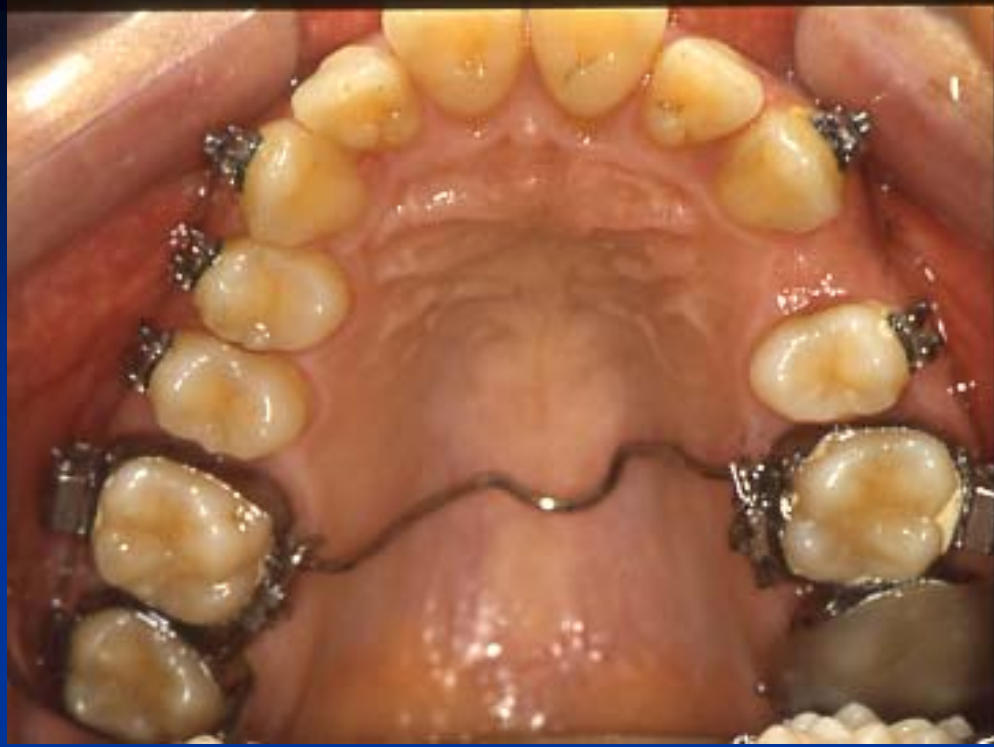## Adulto...e

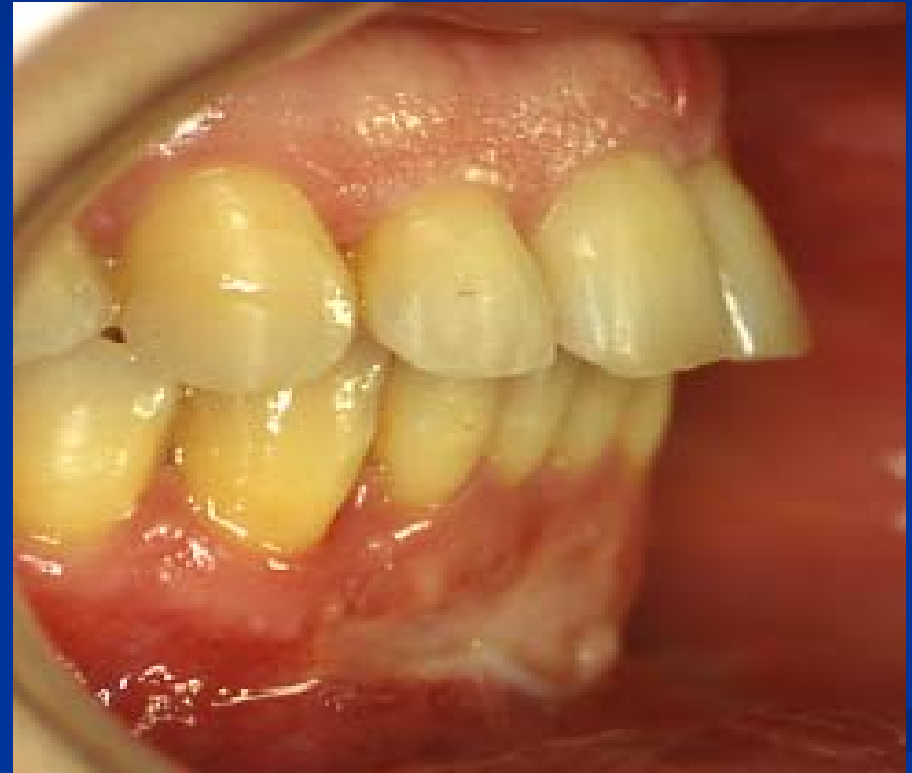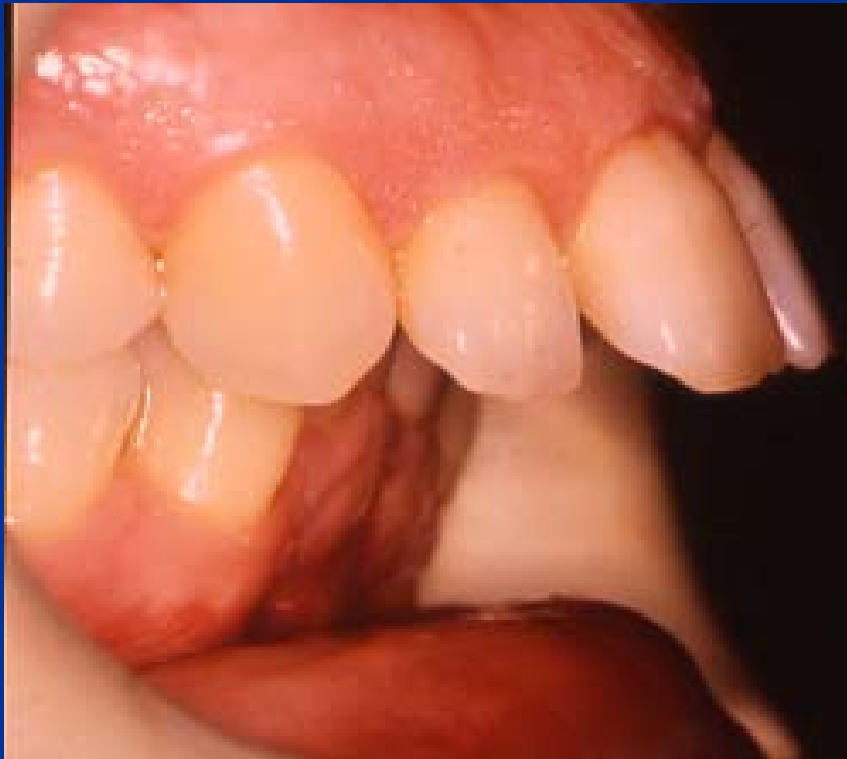- affollamento
  - discrepanza nei tre piani dello spazio
  - deformità dento facciale
- Chirurgia ortodontica
- parodontopatico

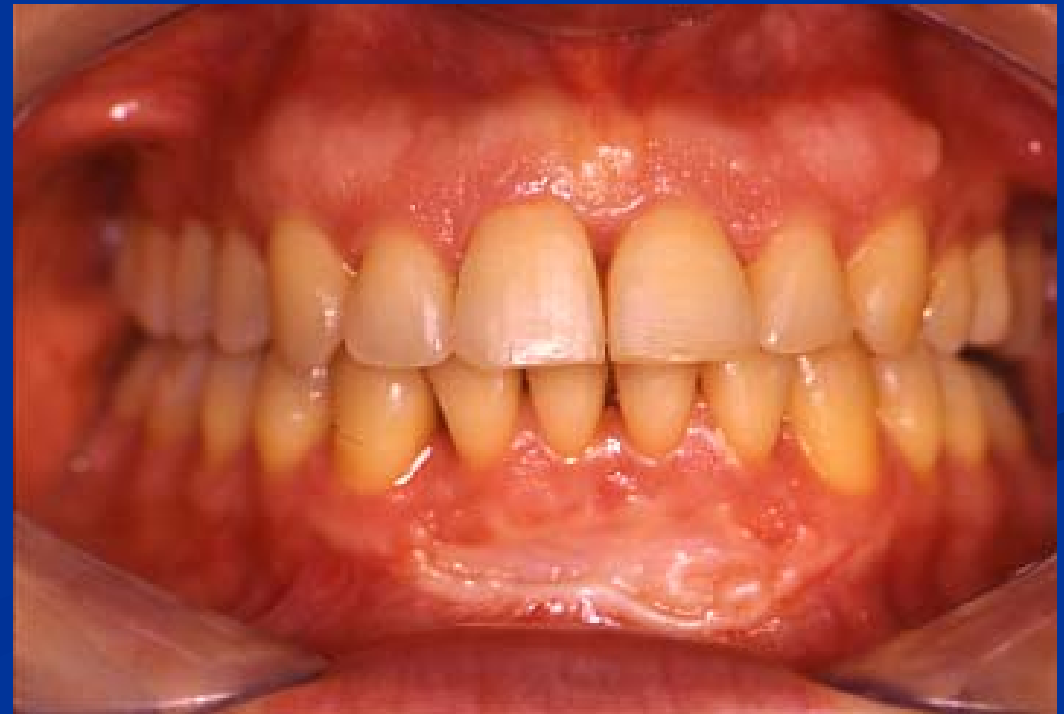
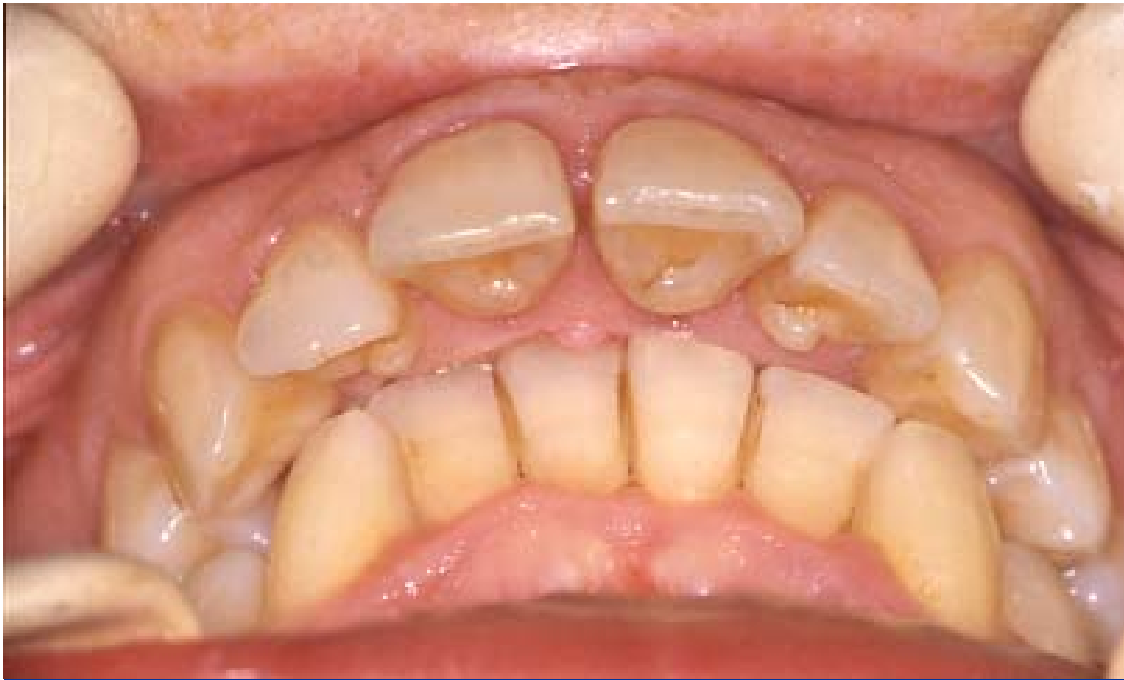


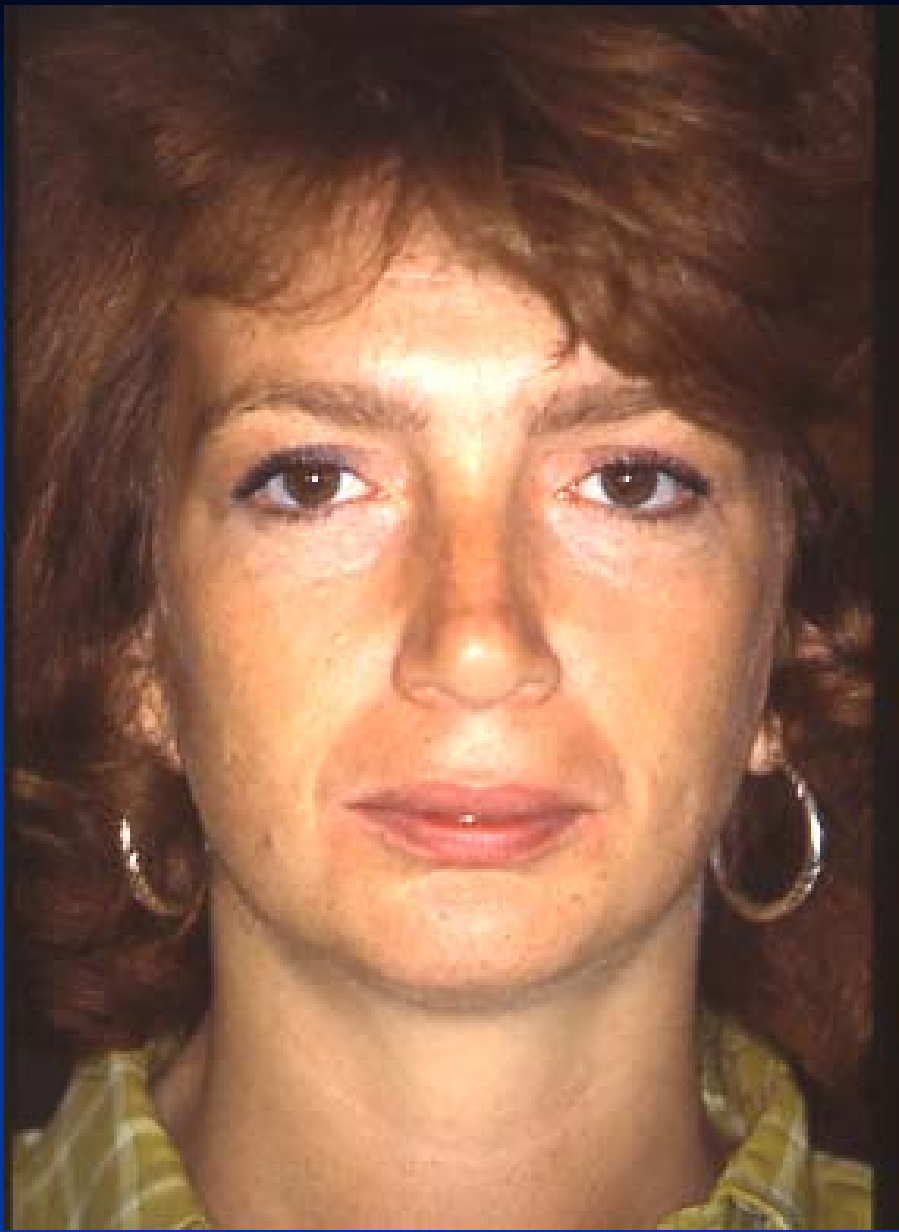

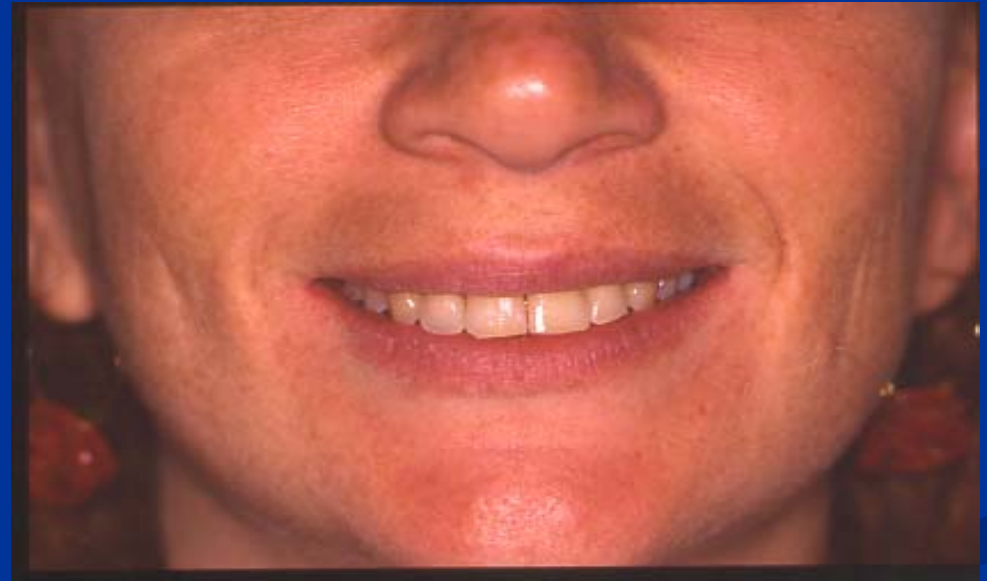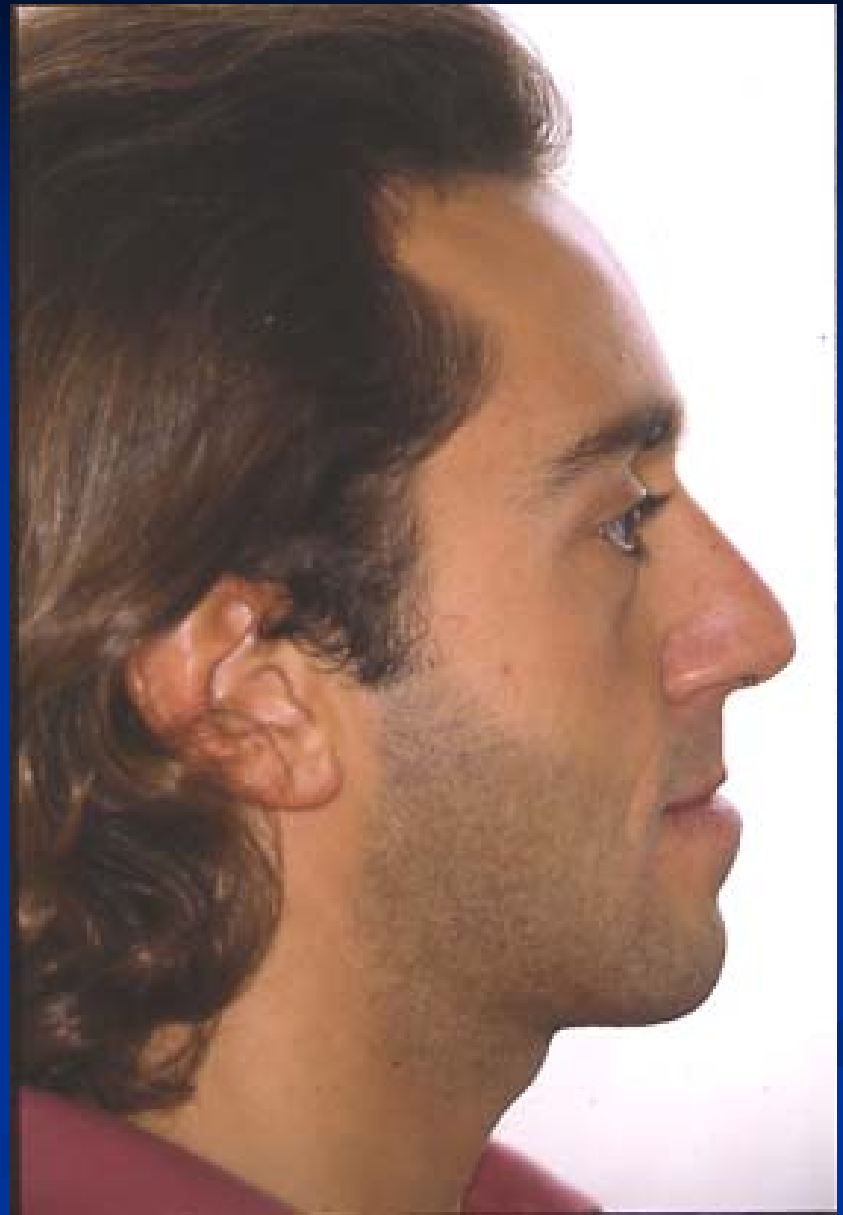




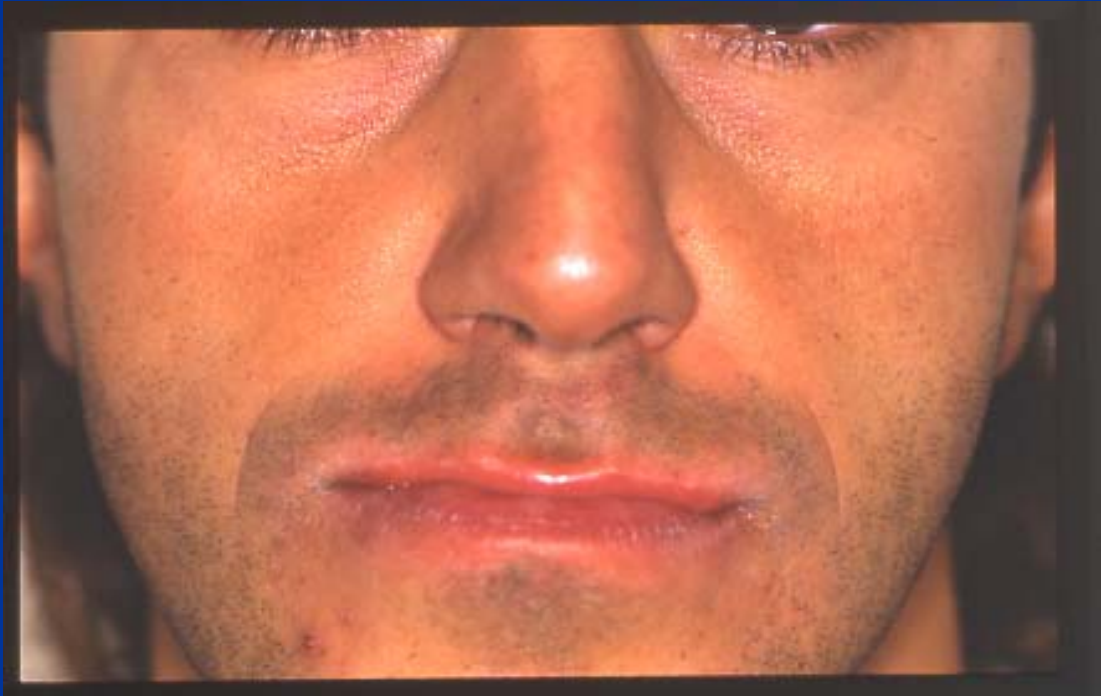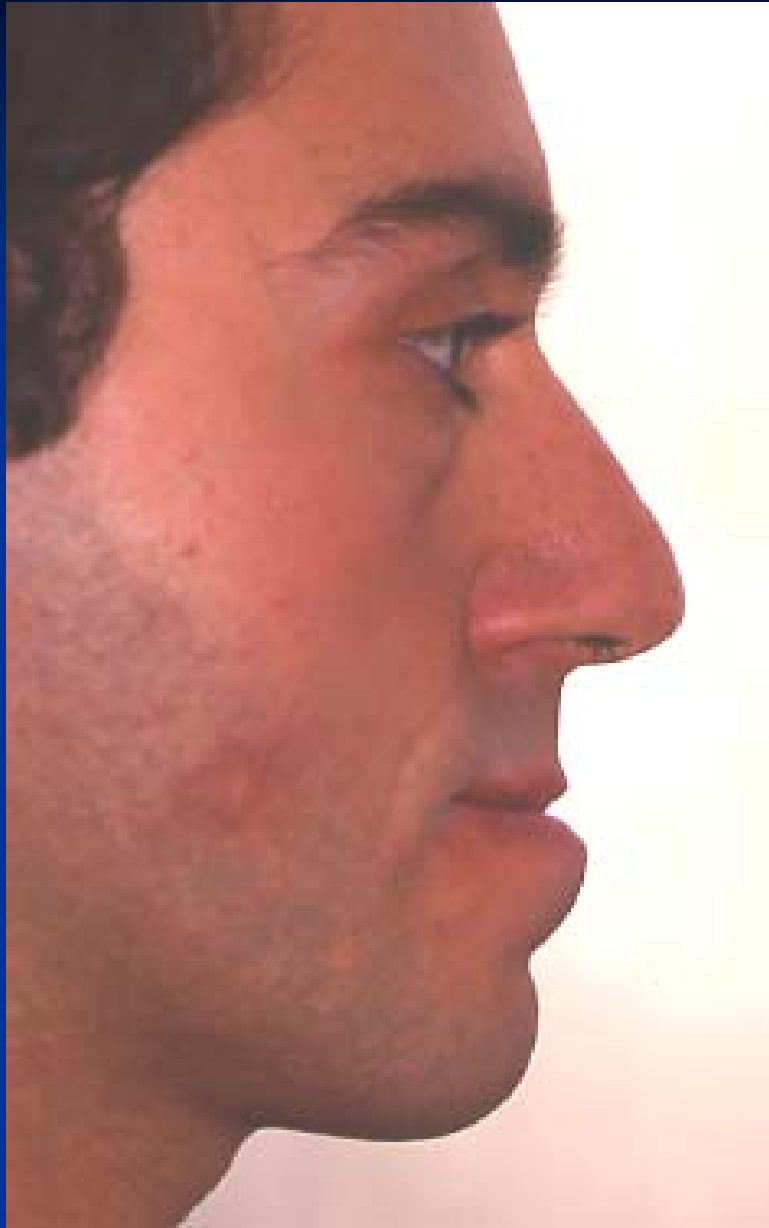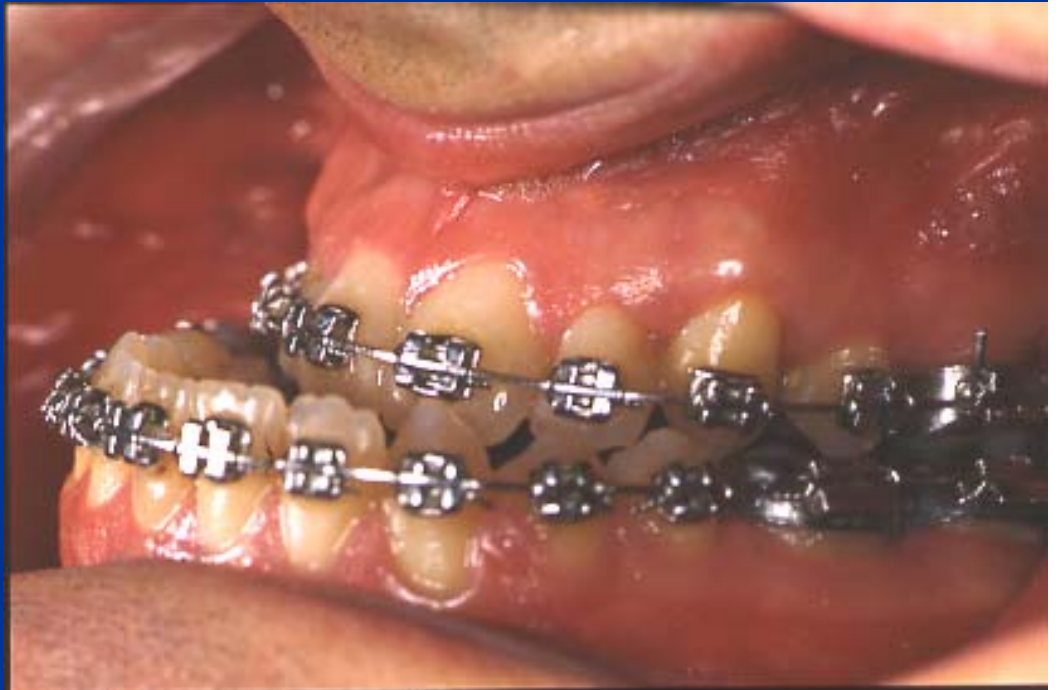




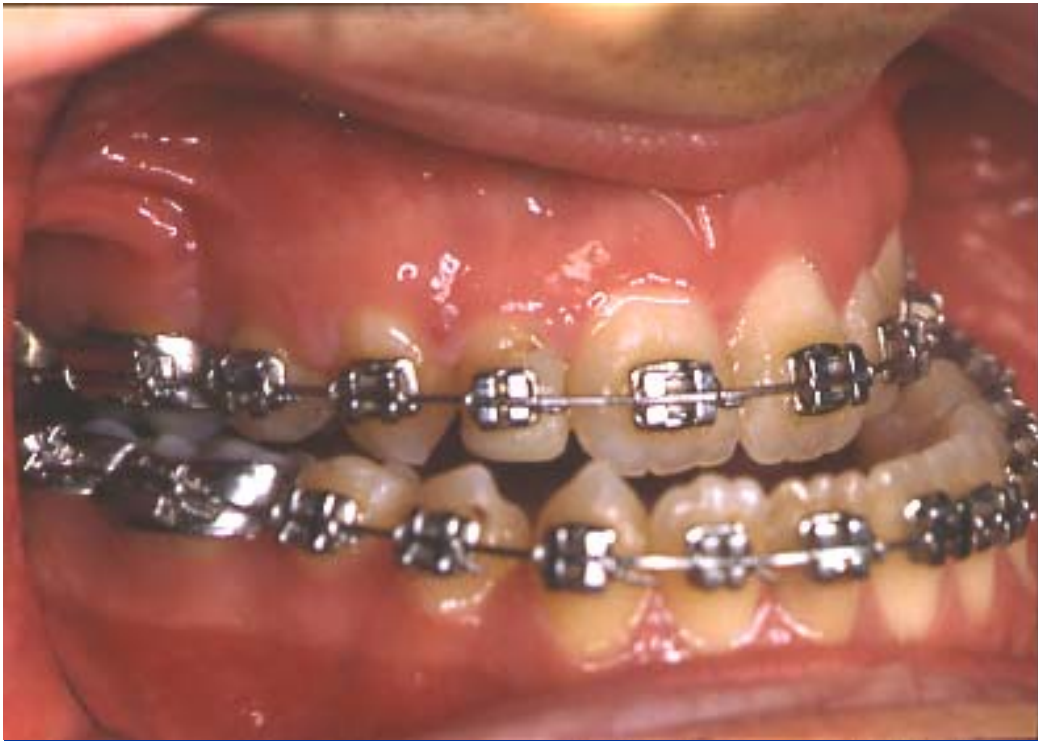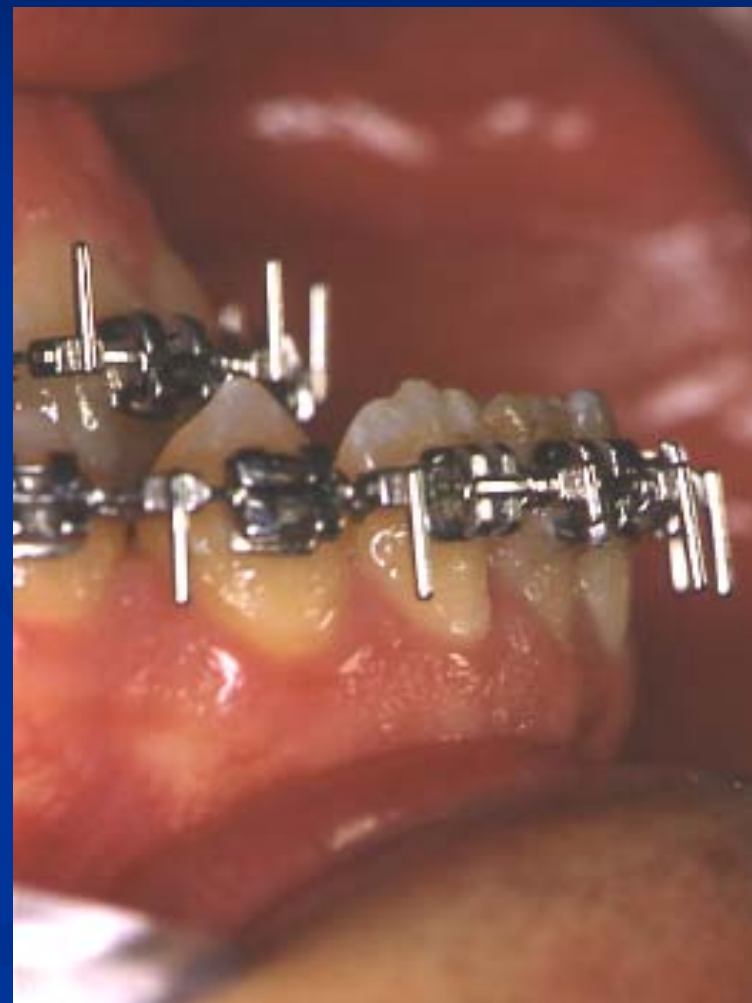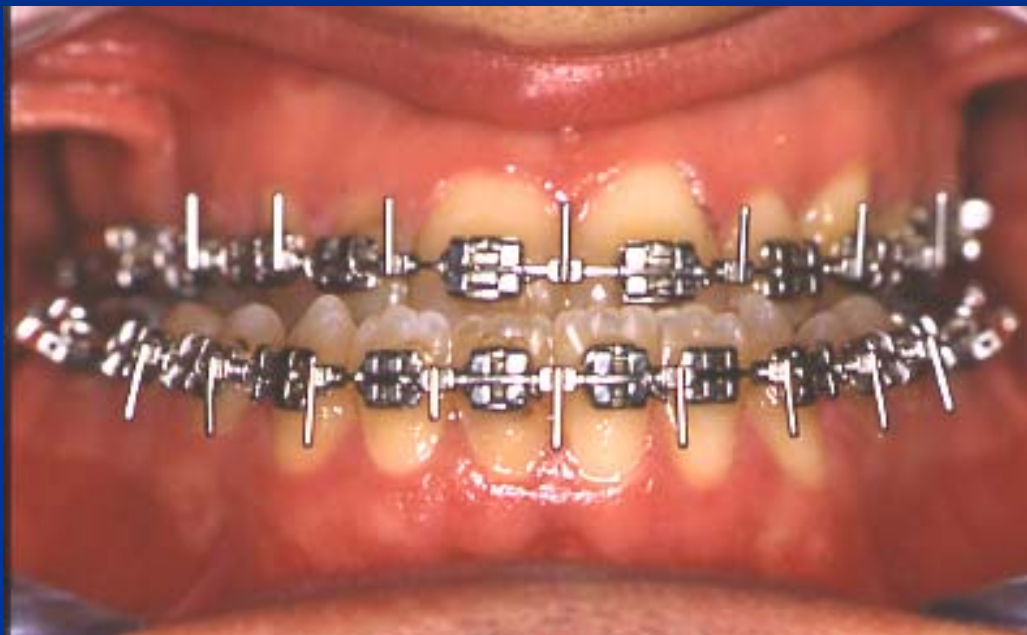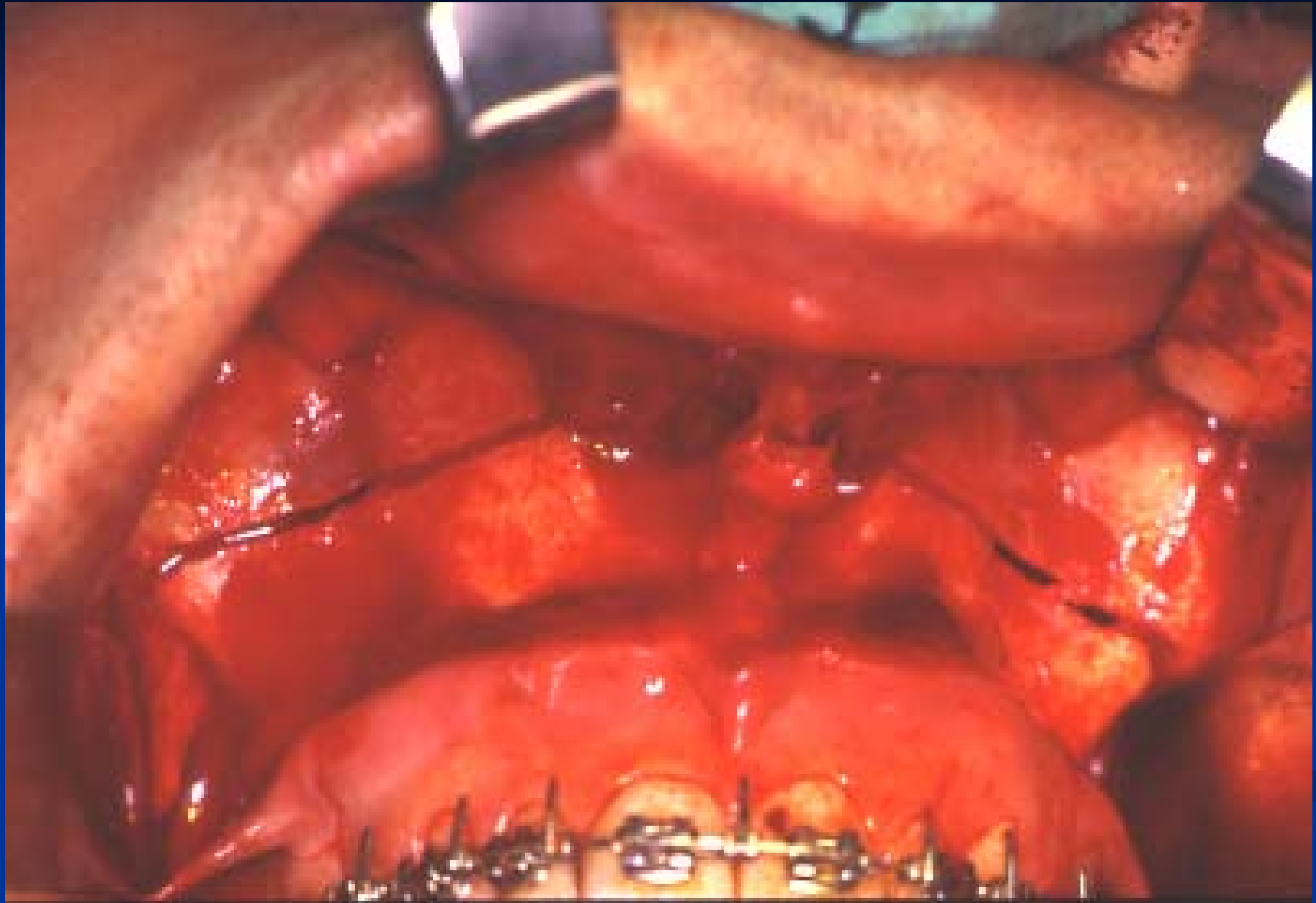











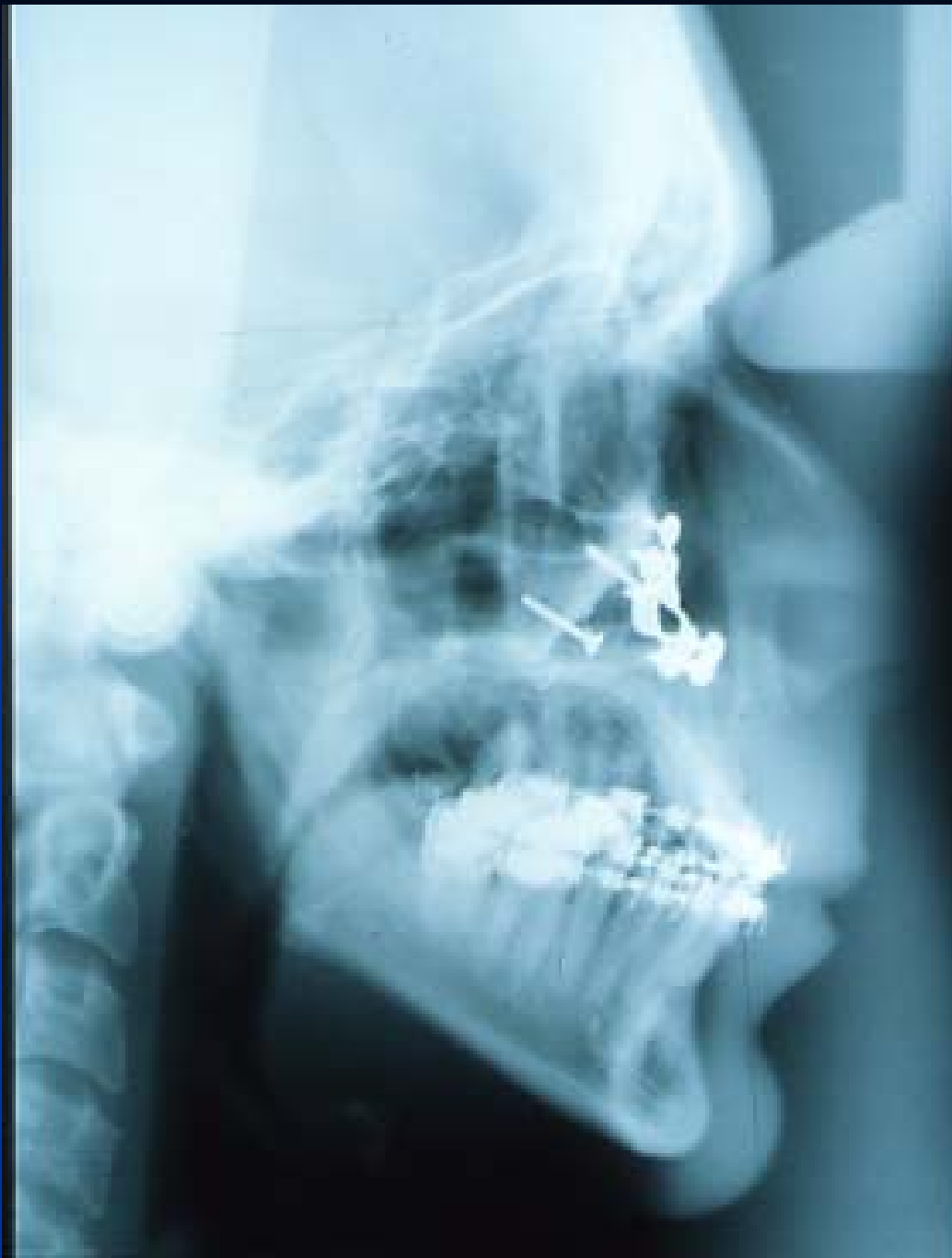


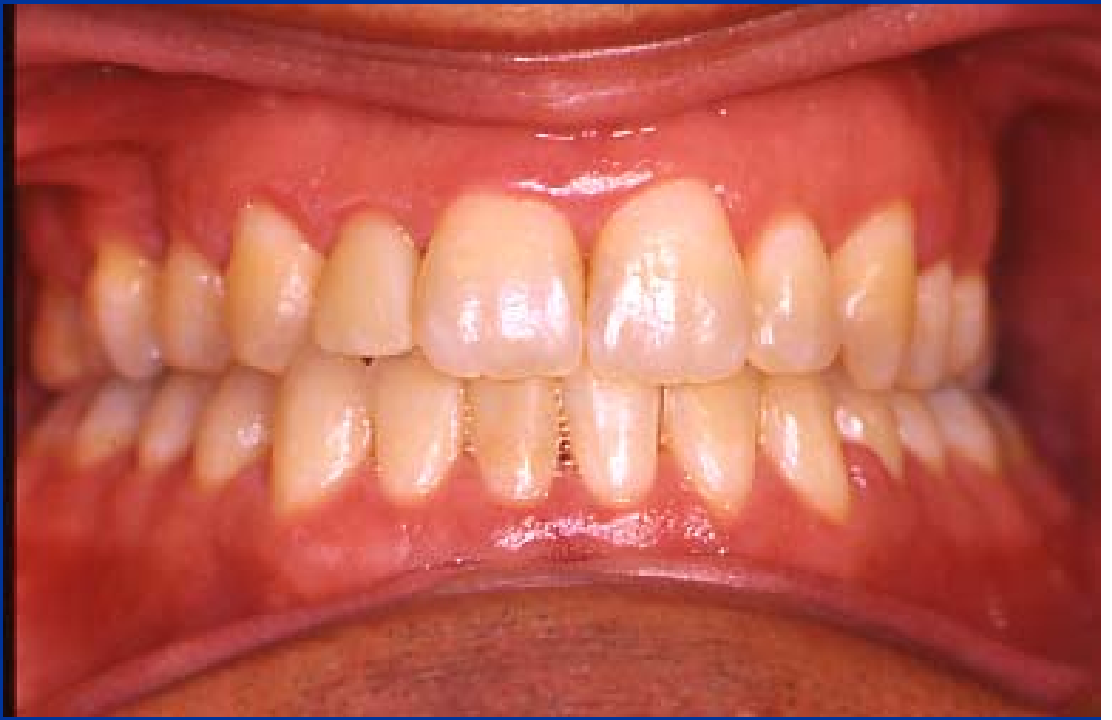
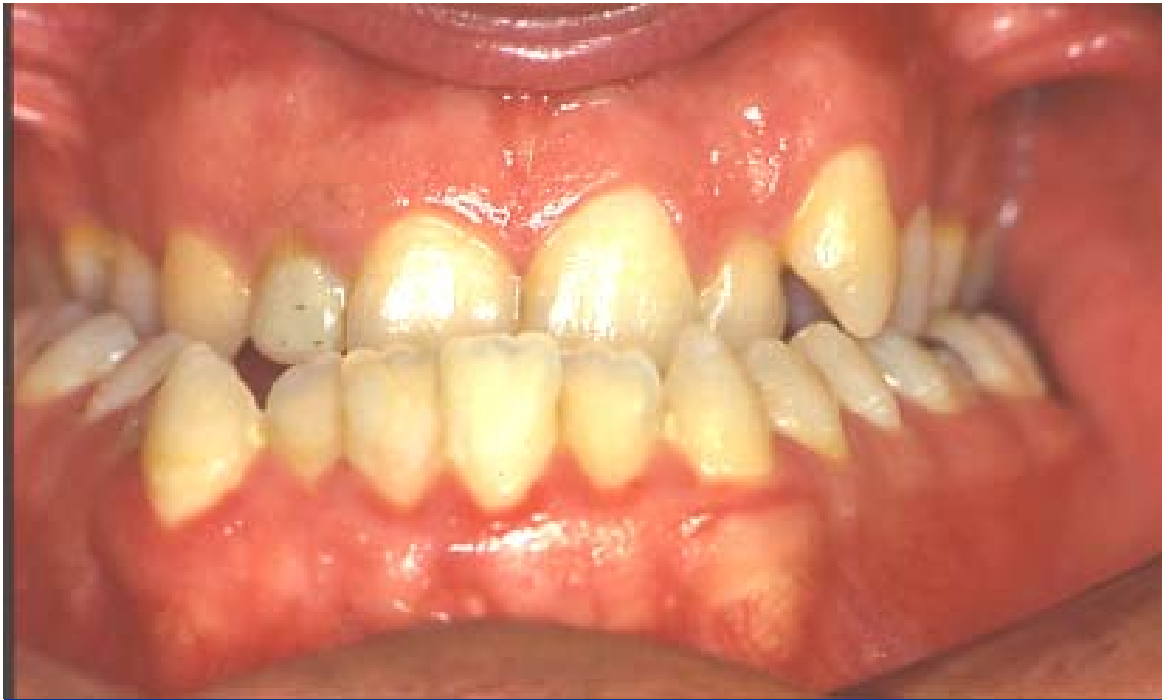


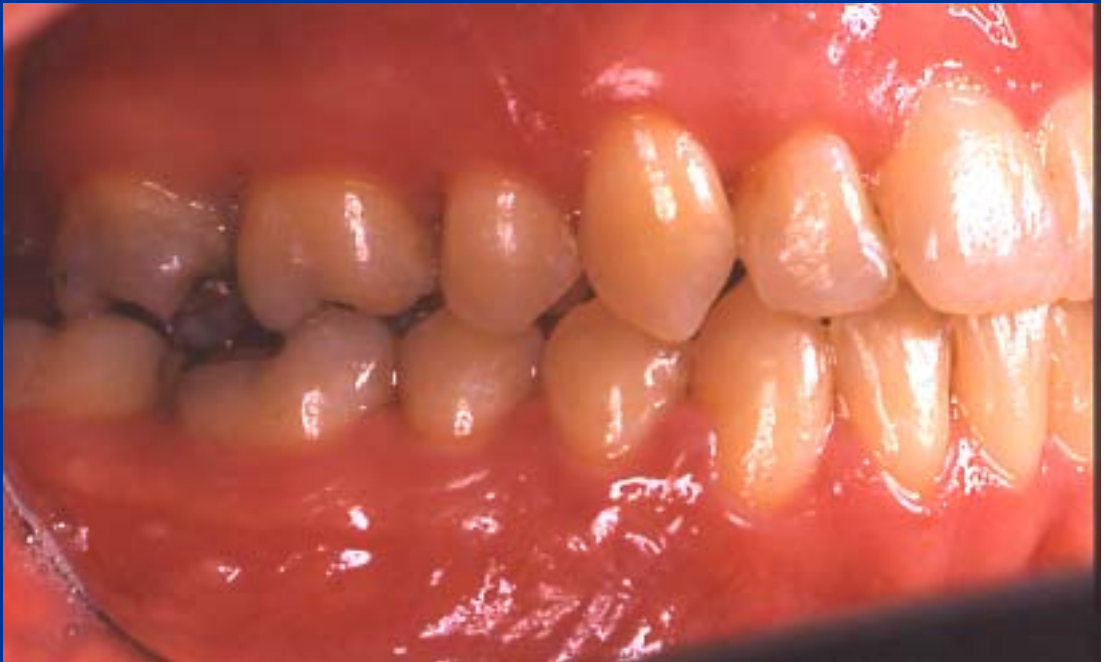
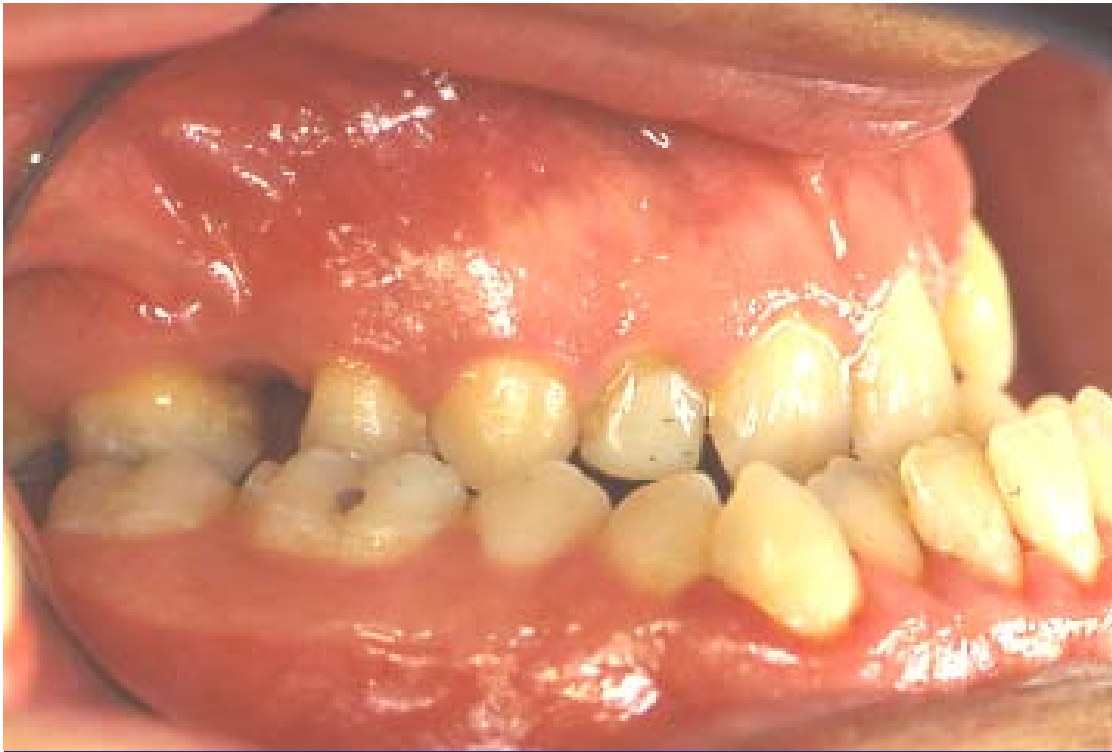


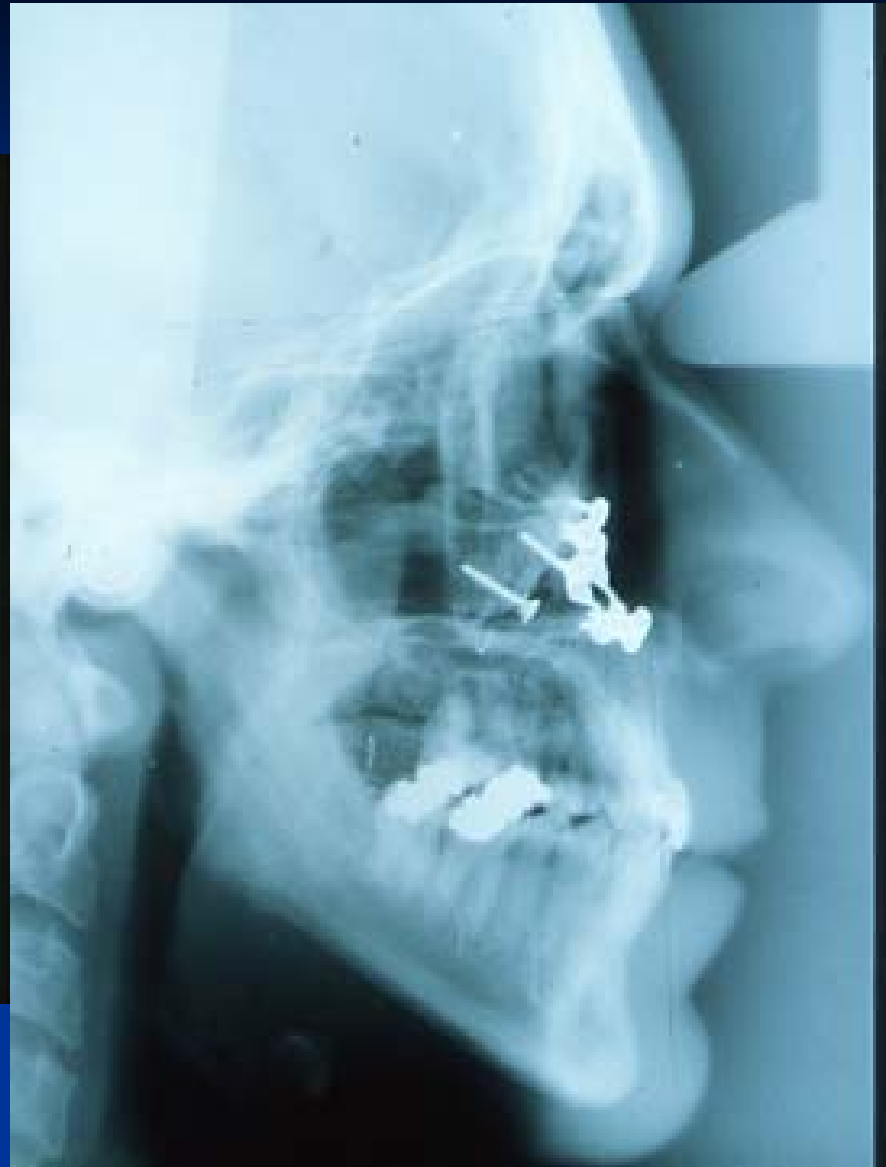
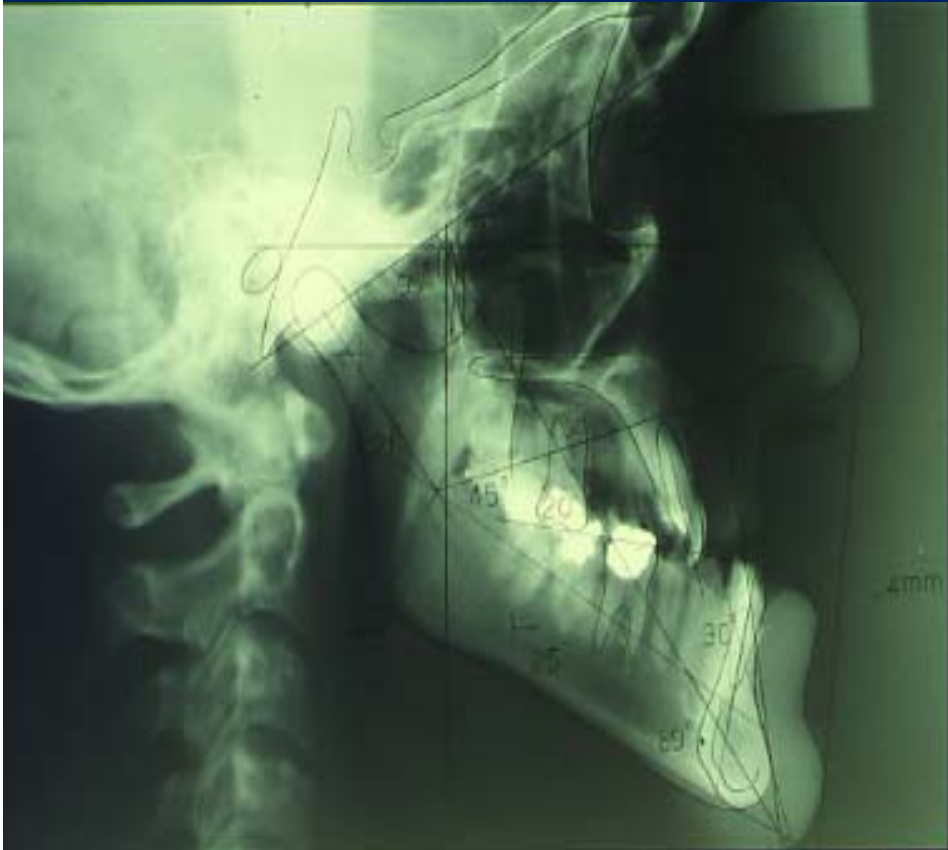


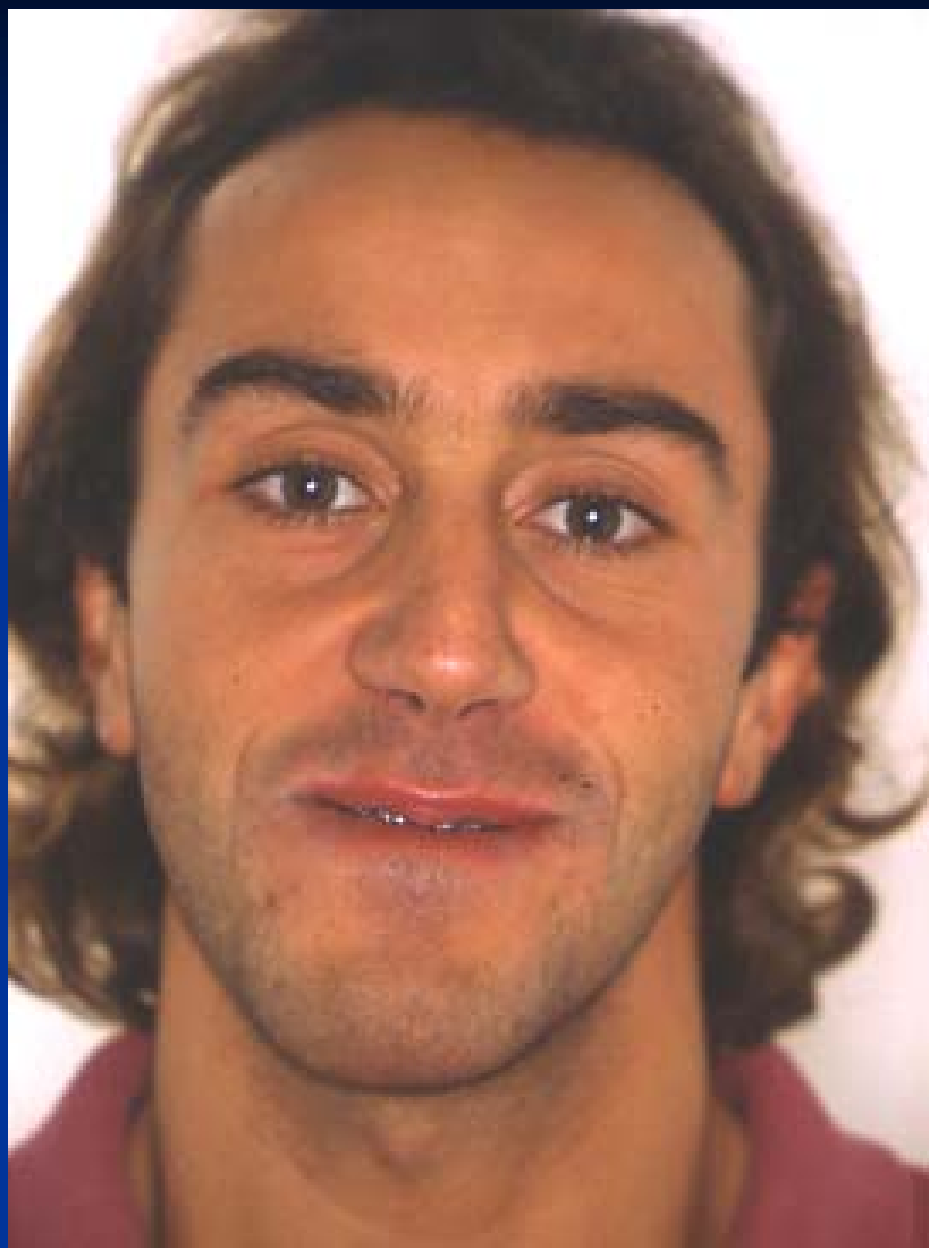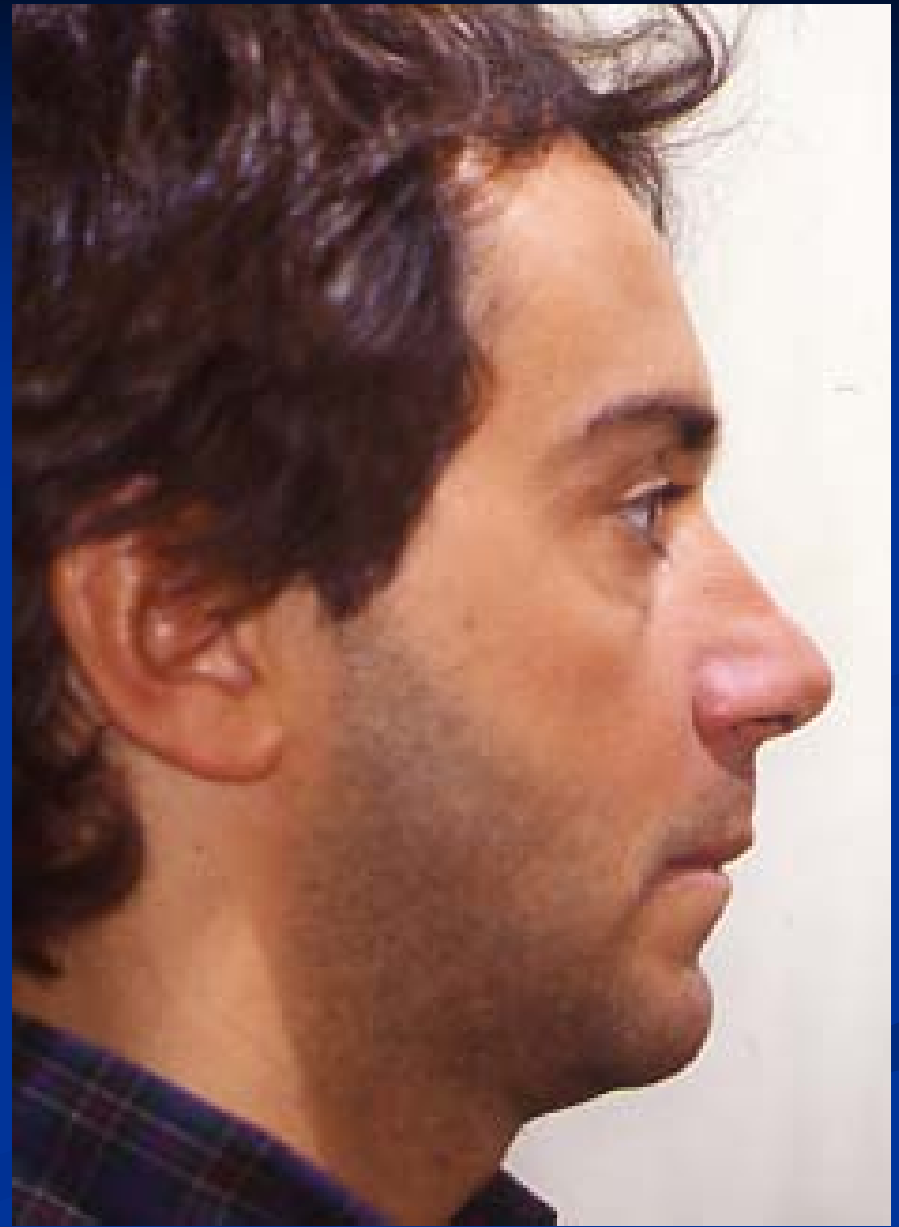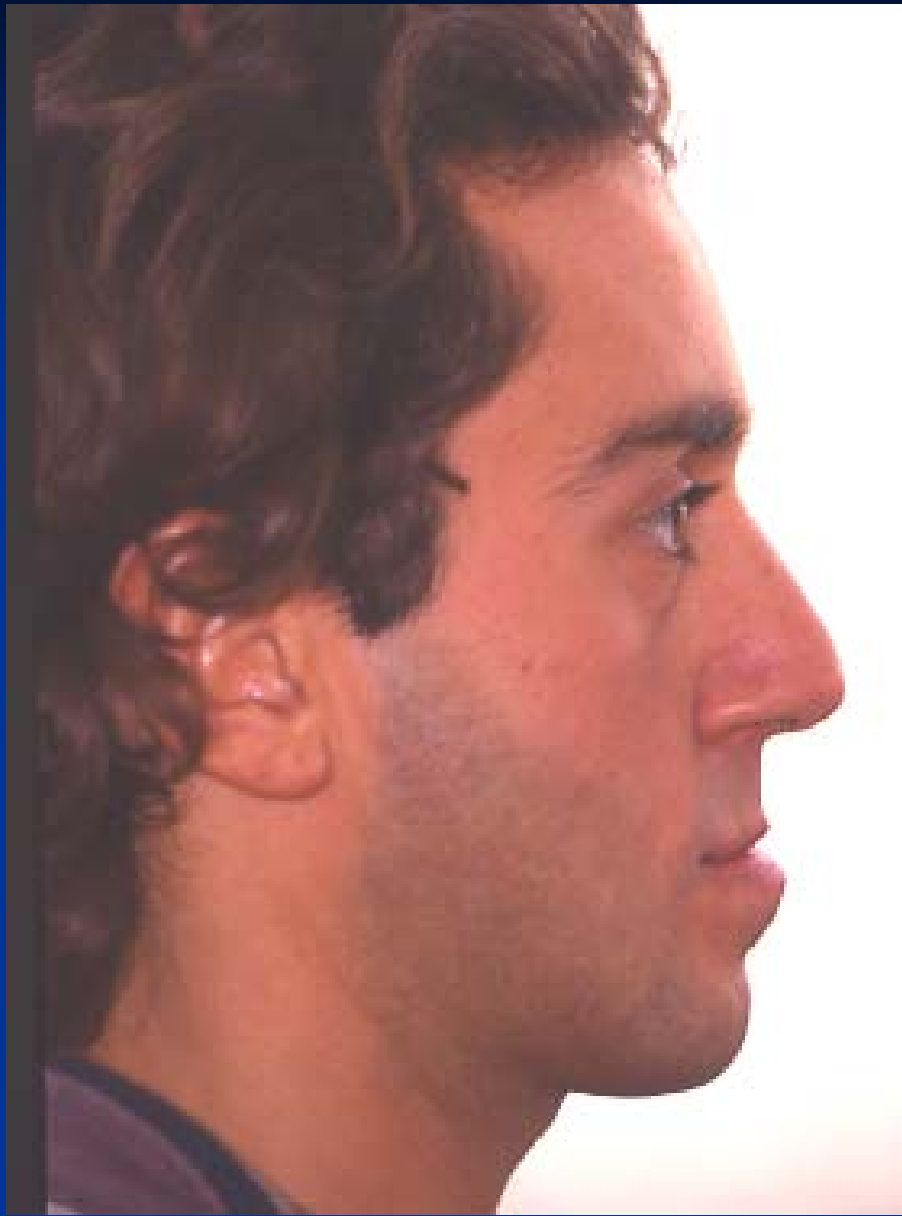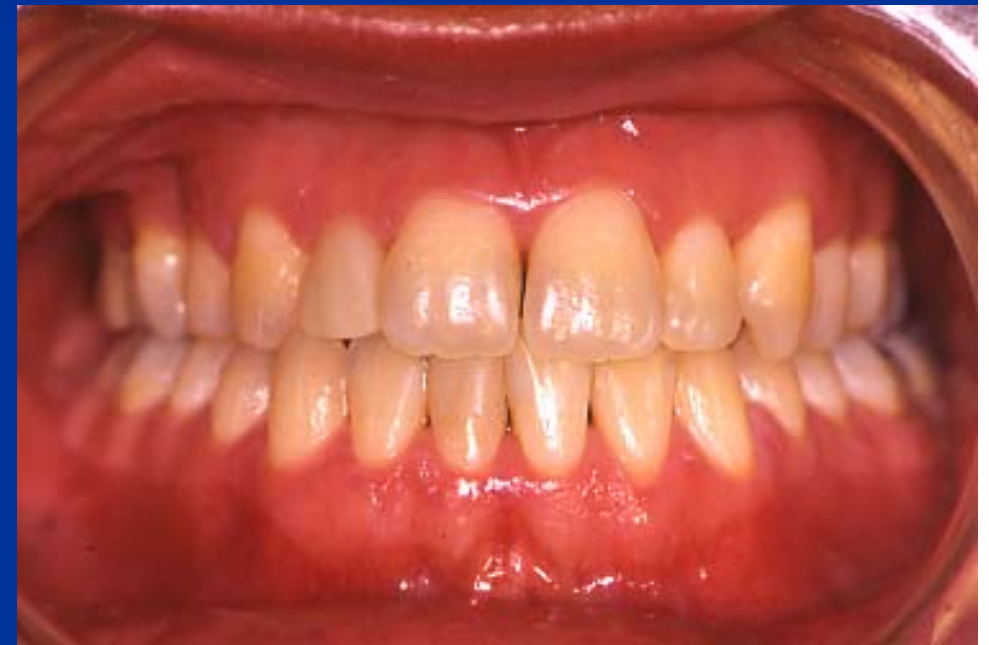# Perchè...

- Necessità
- Opportunità

# Perchè...

## Indice di necessità di trattamento

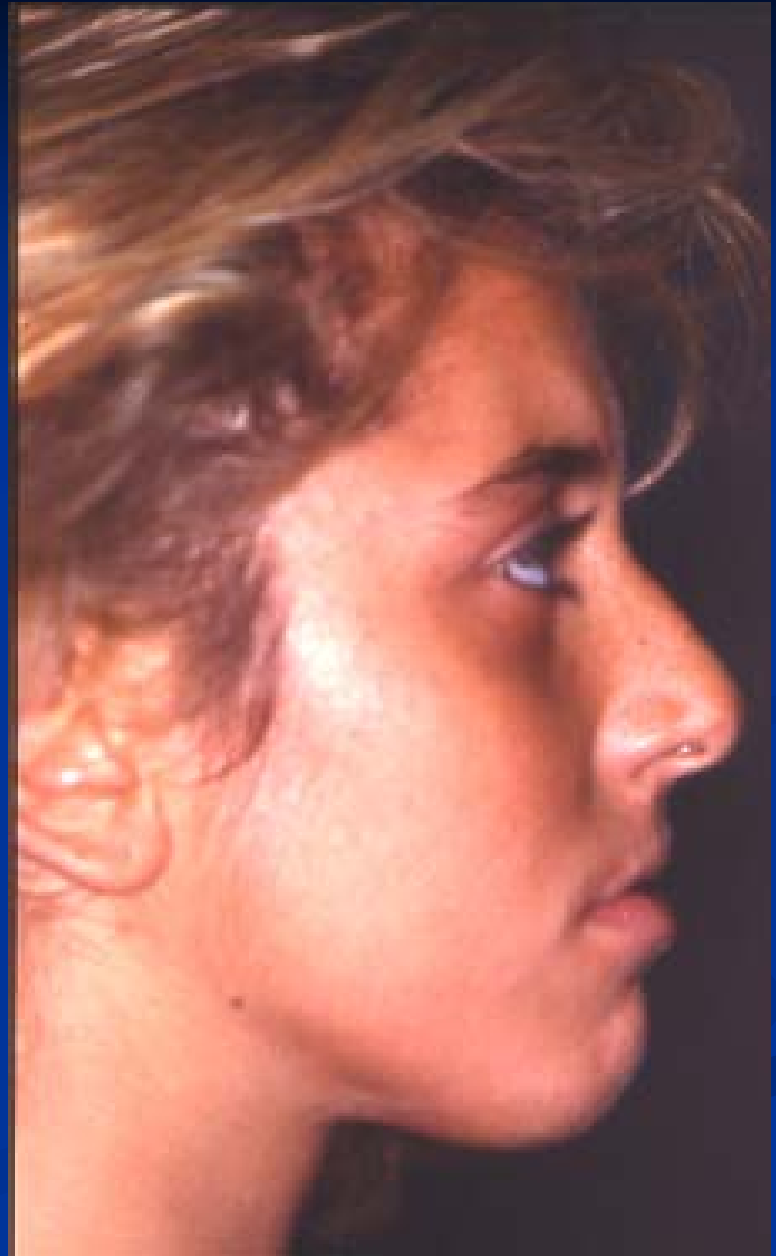Grado 1= lieve malposizione

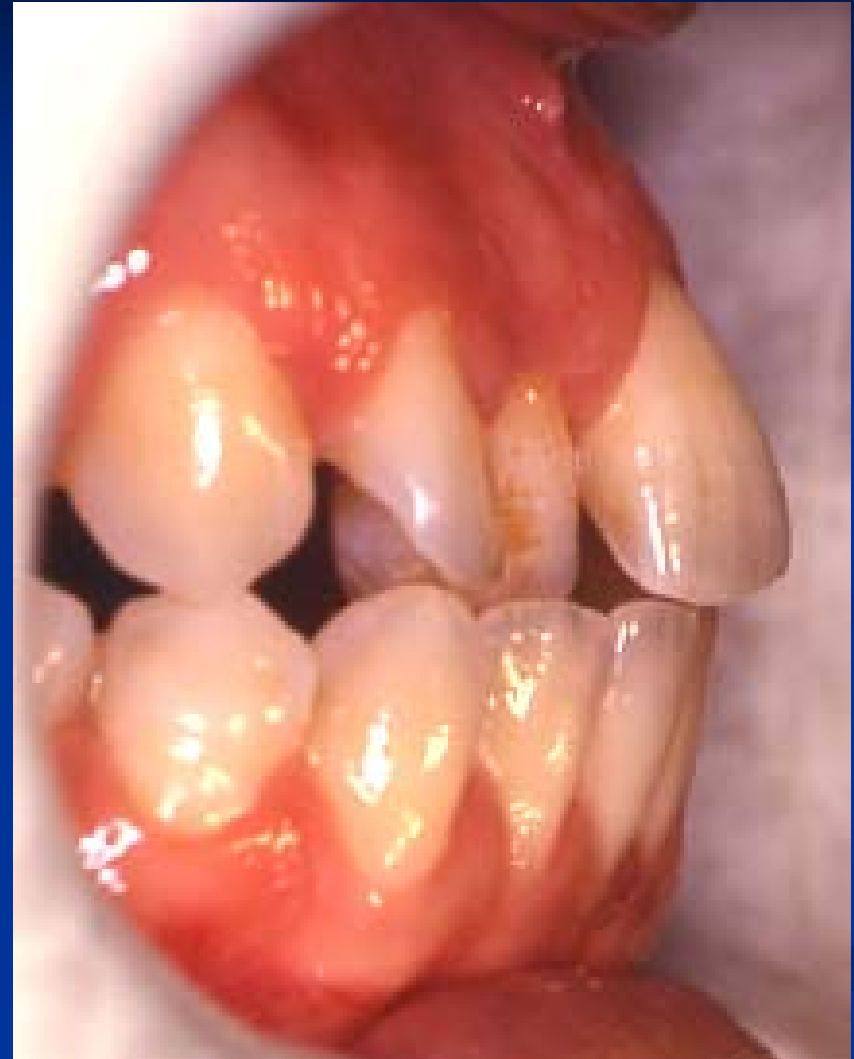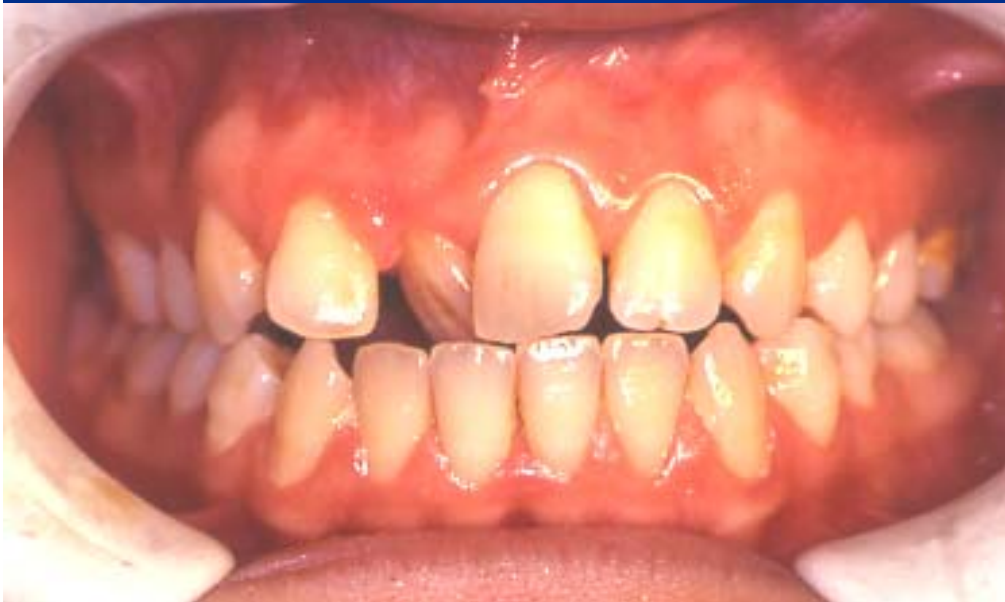Grado 2= medio

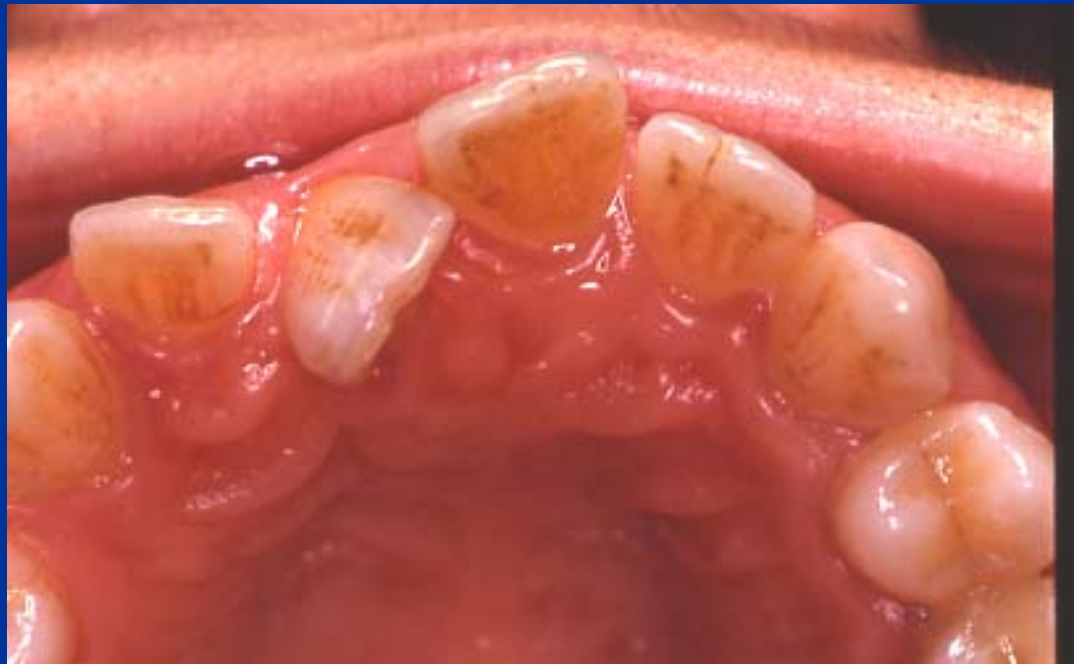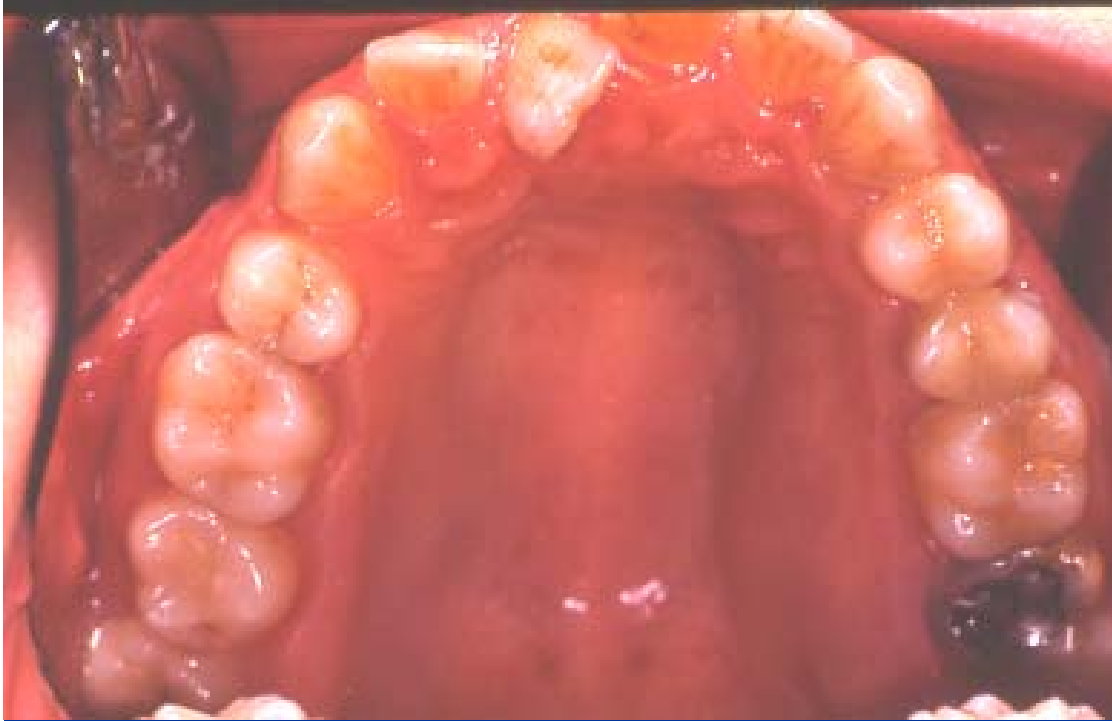Grado 3= moderato

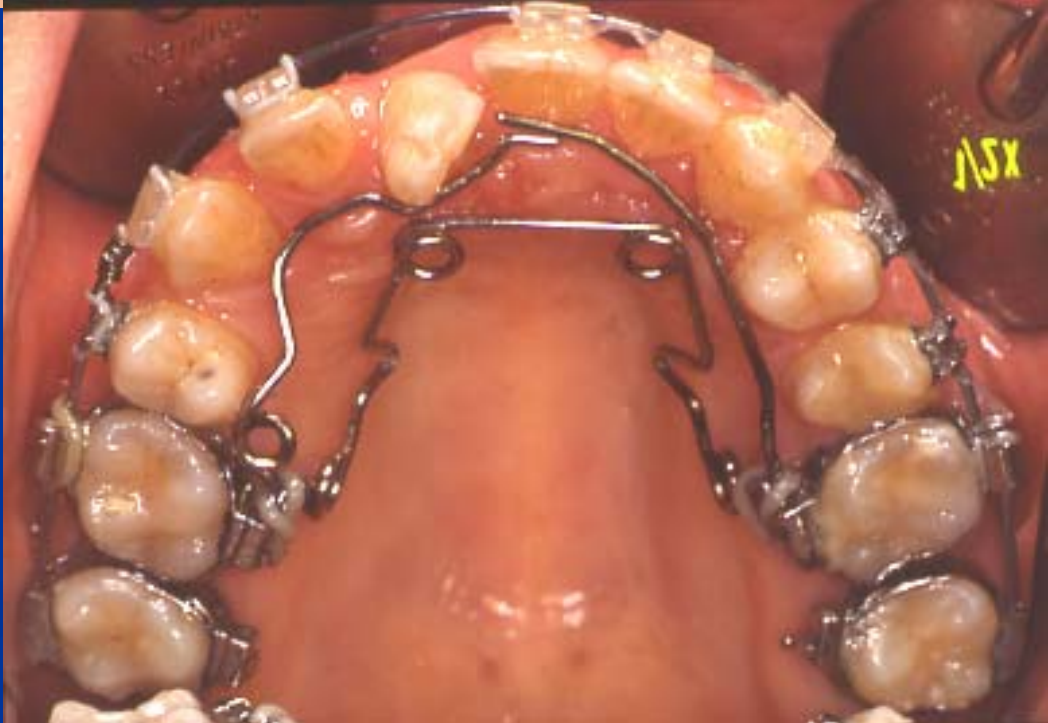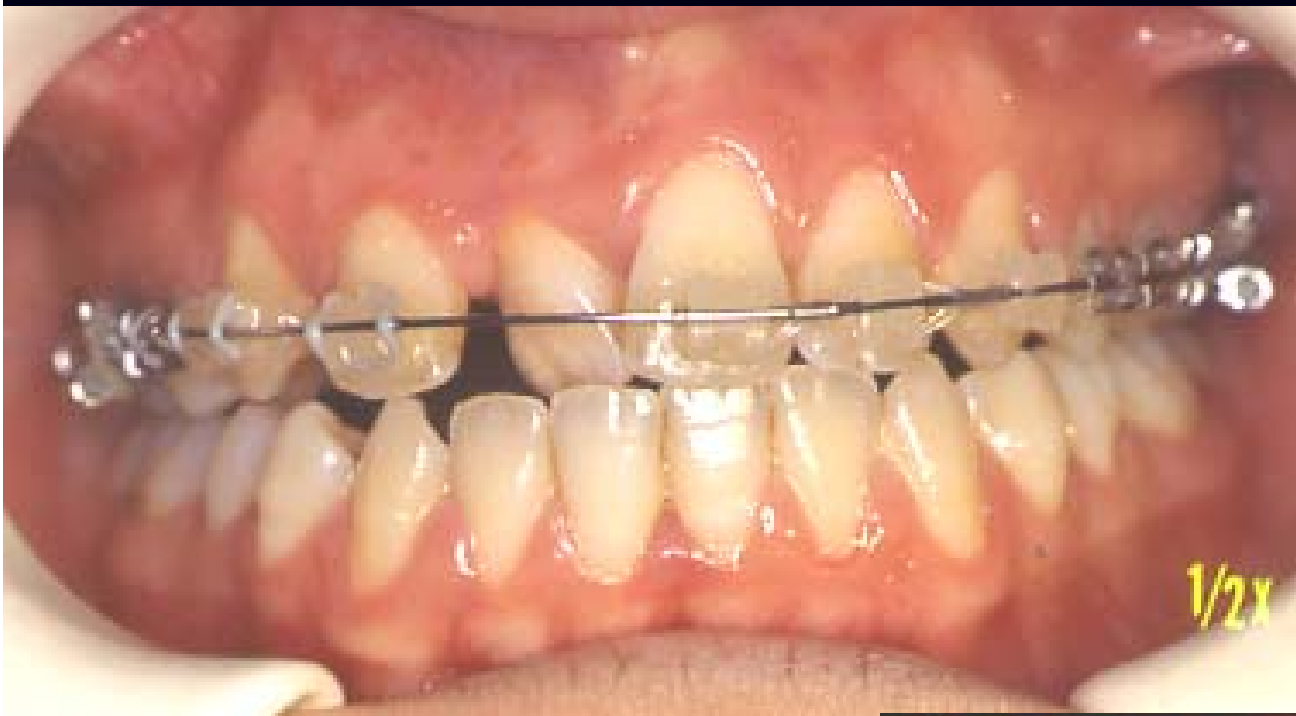Grado 4= grave

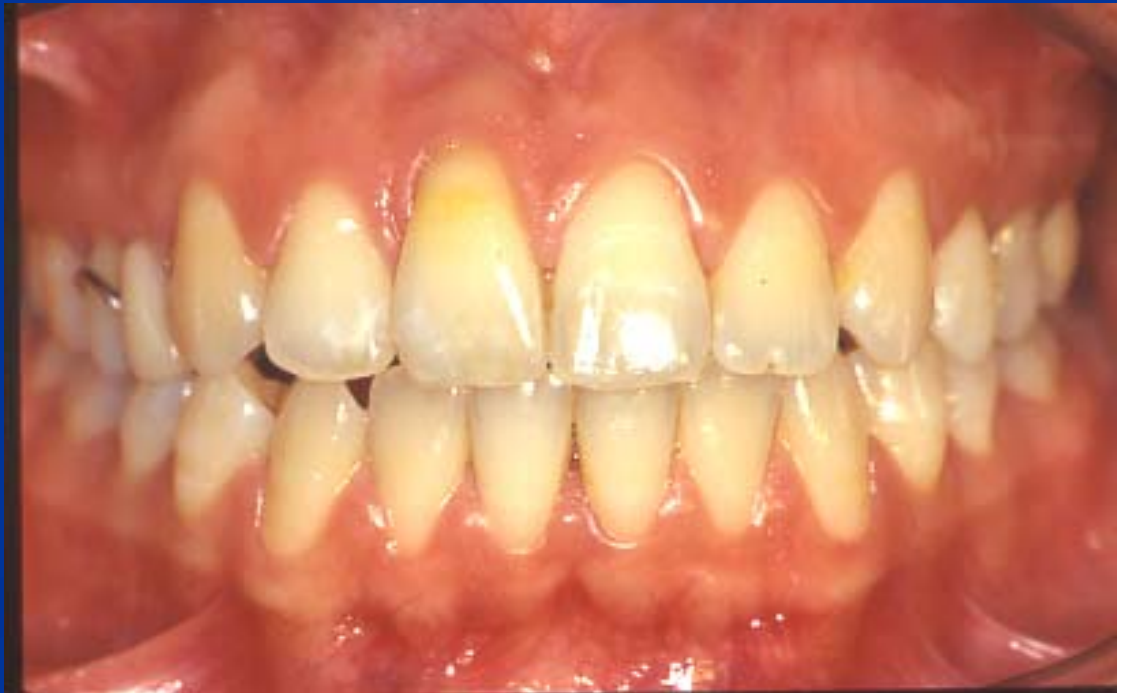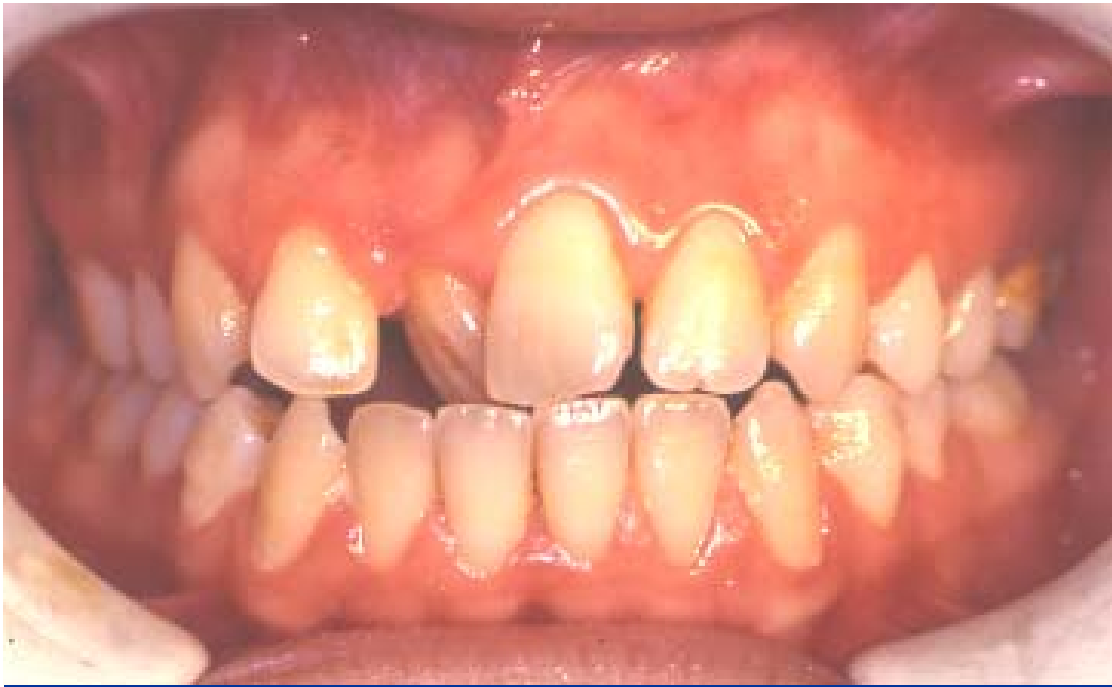Grado 5= molto grave

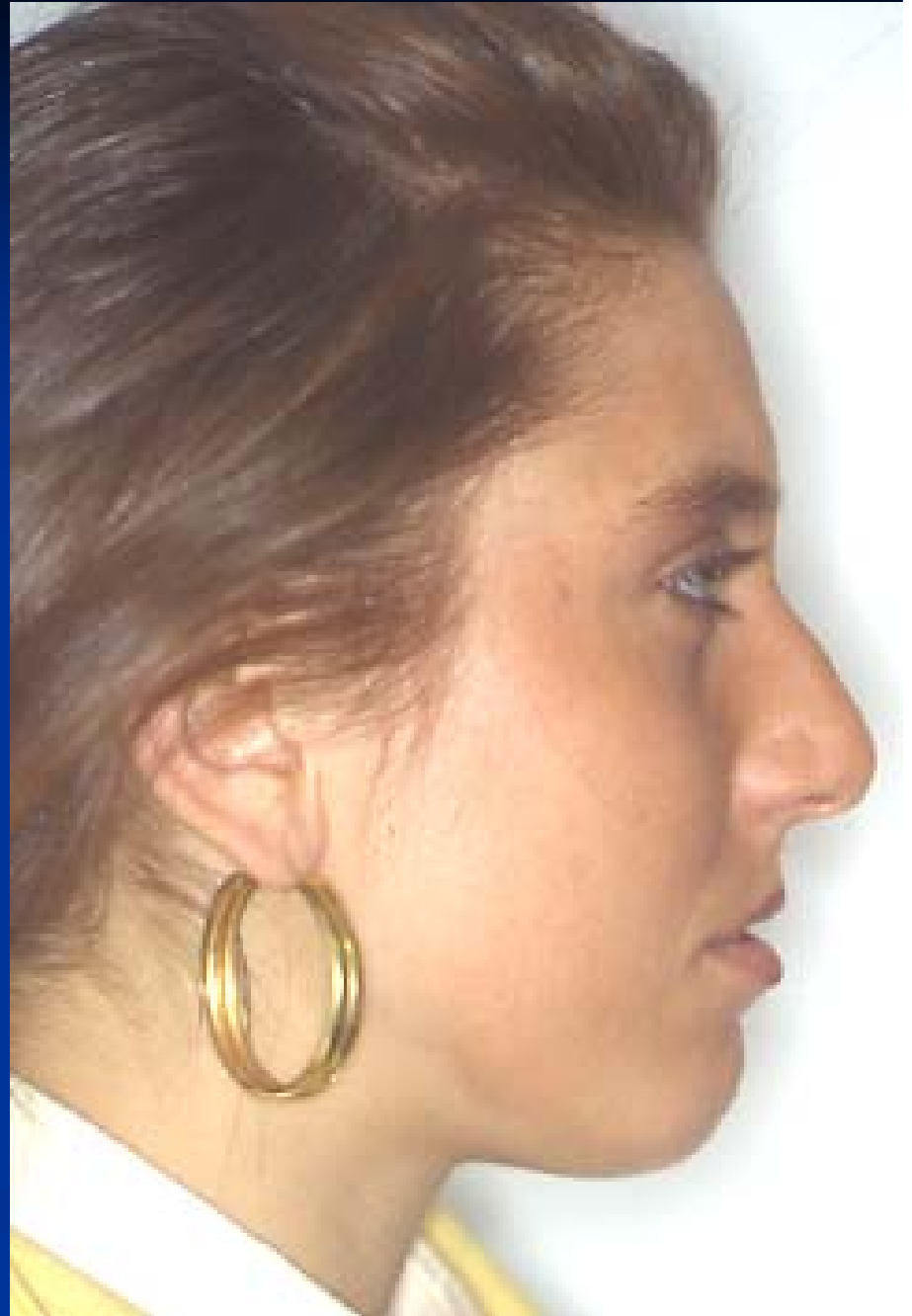
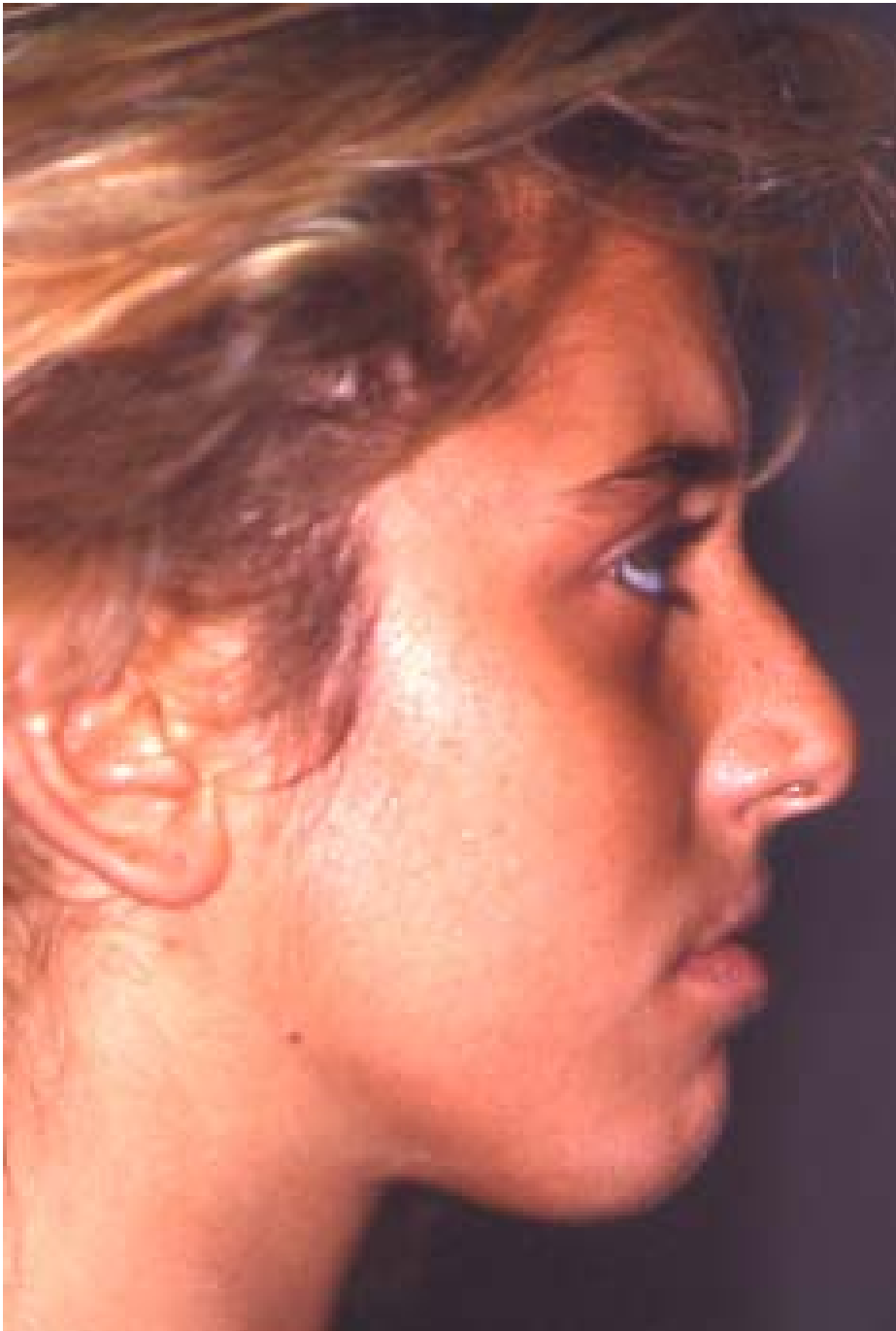








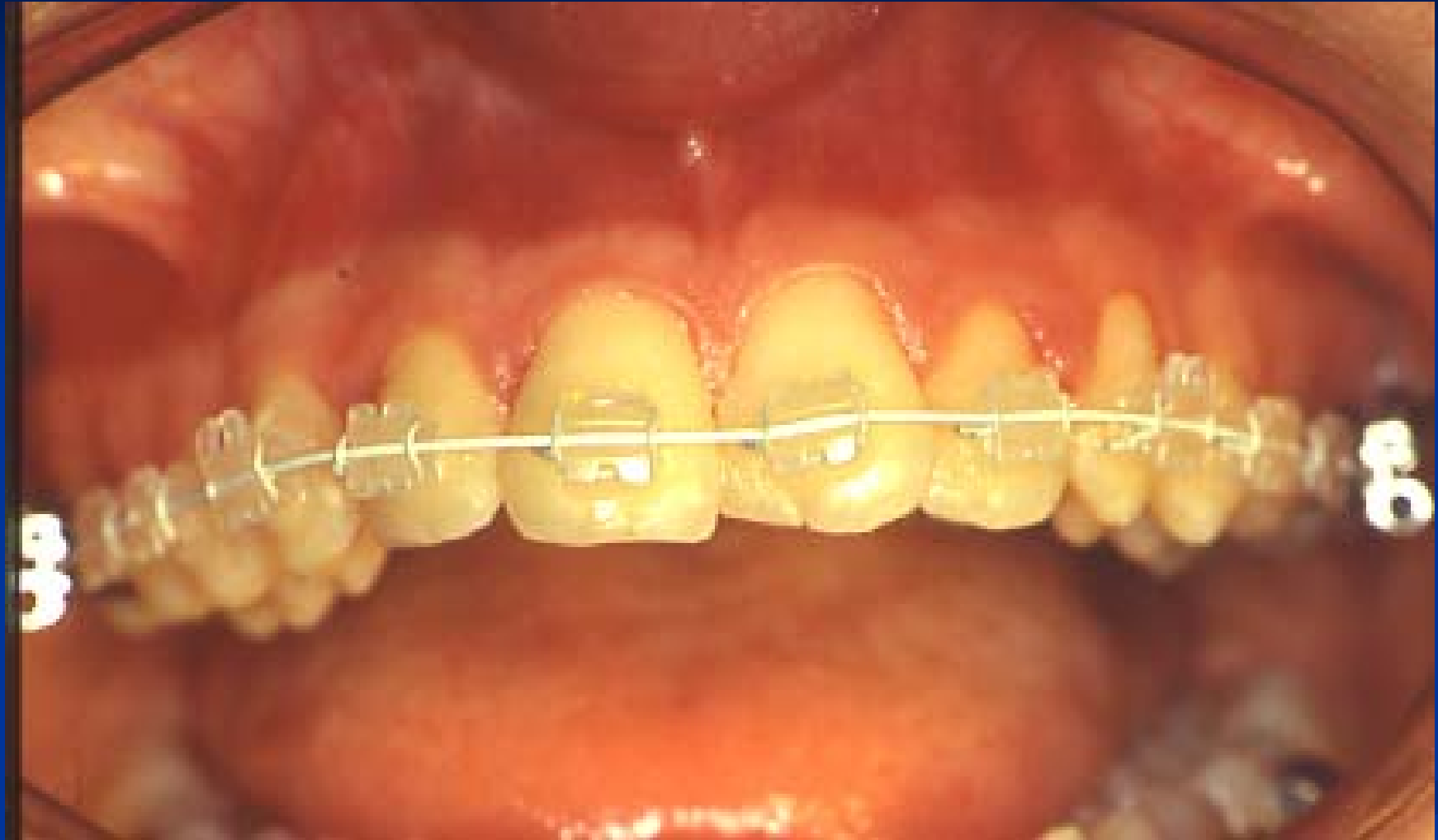


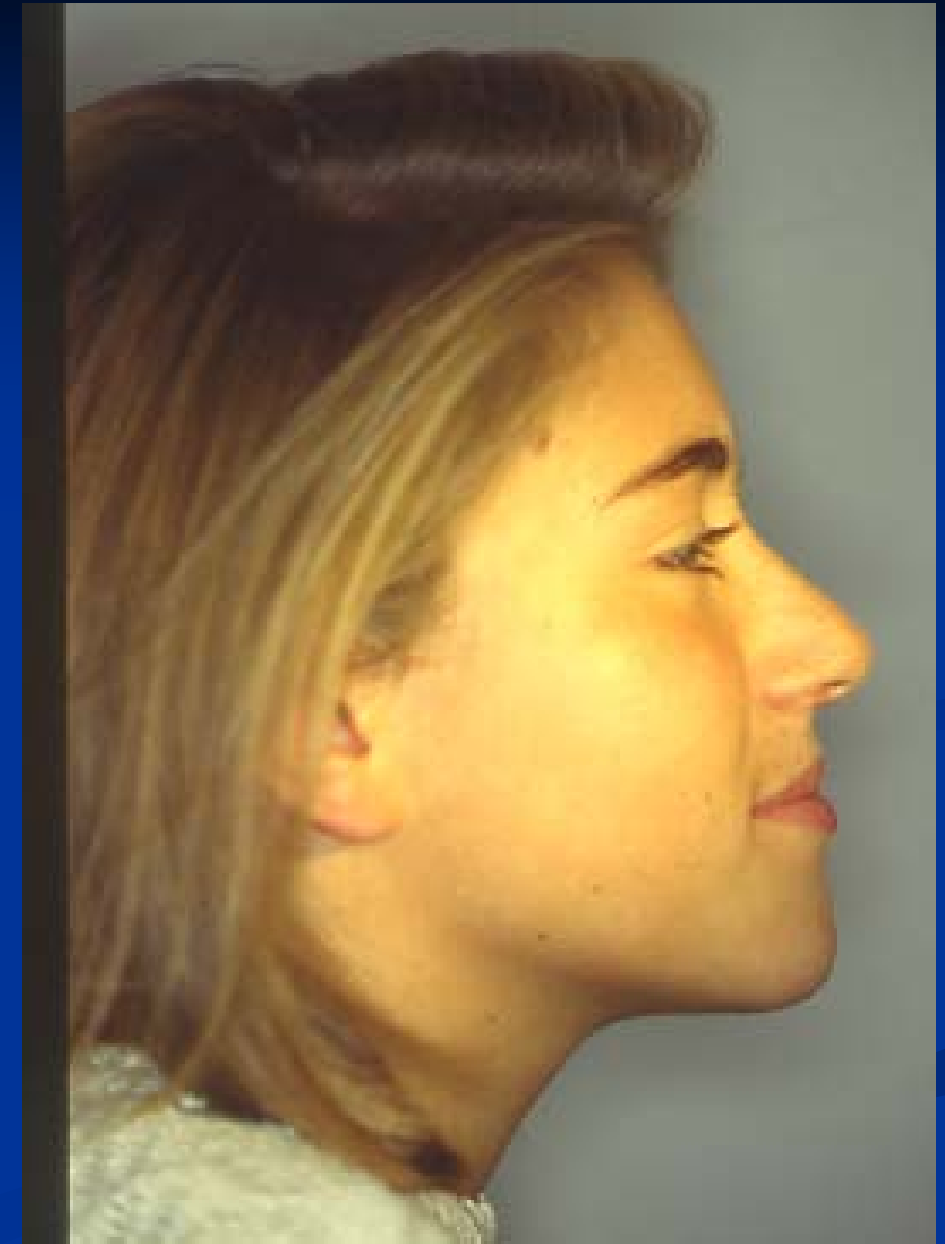
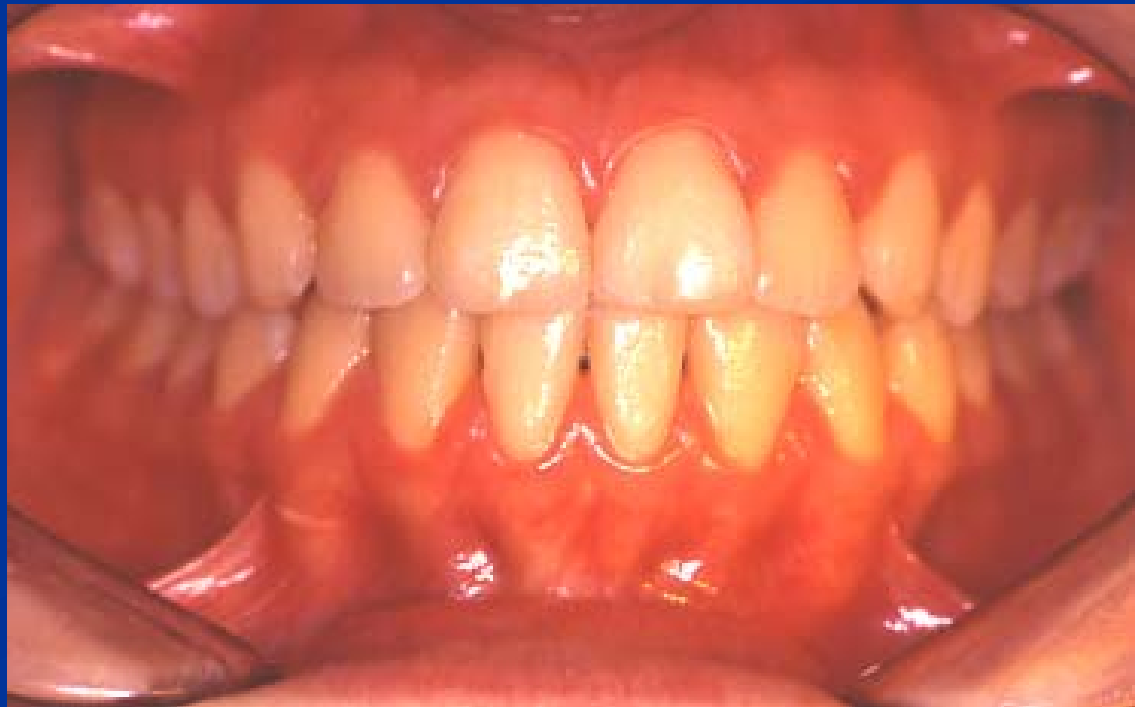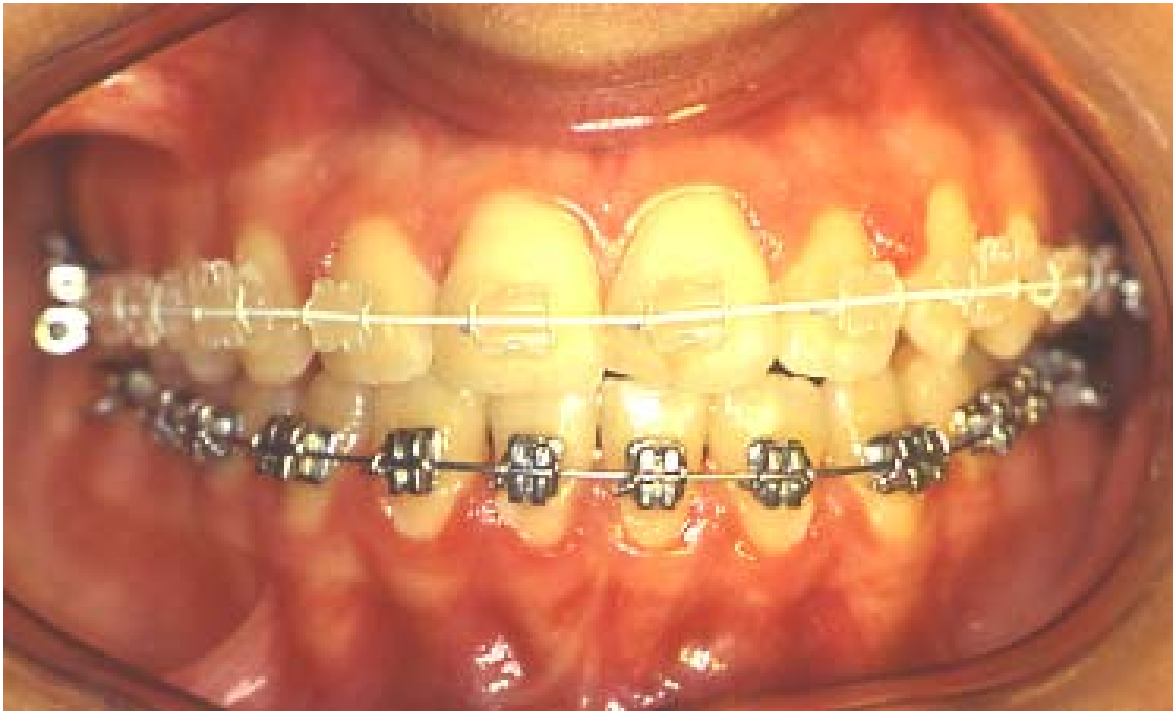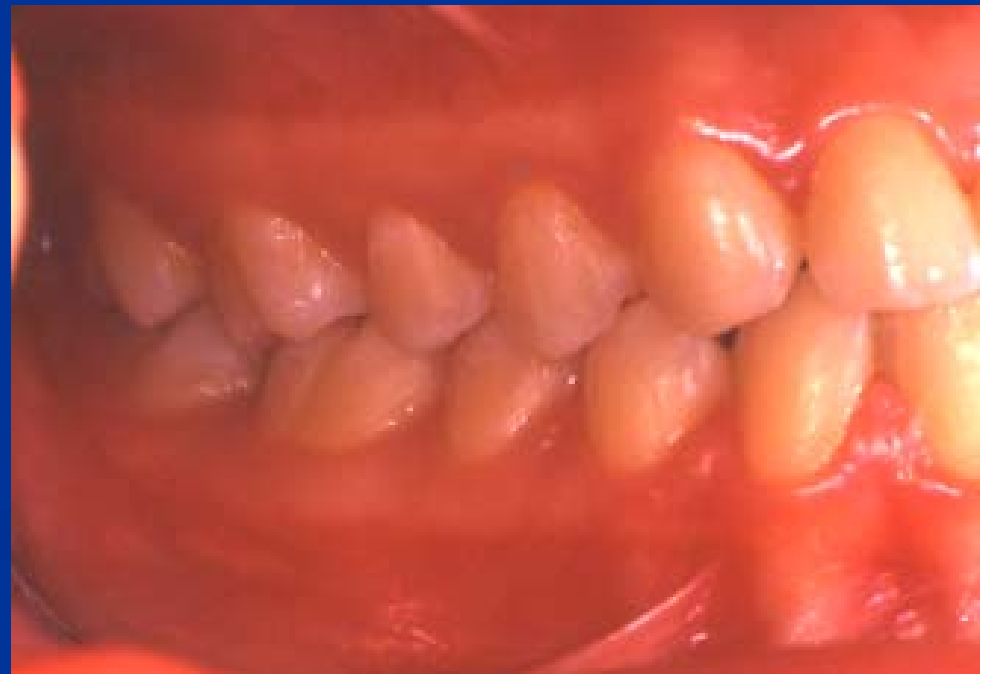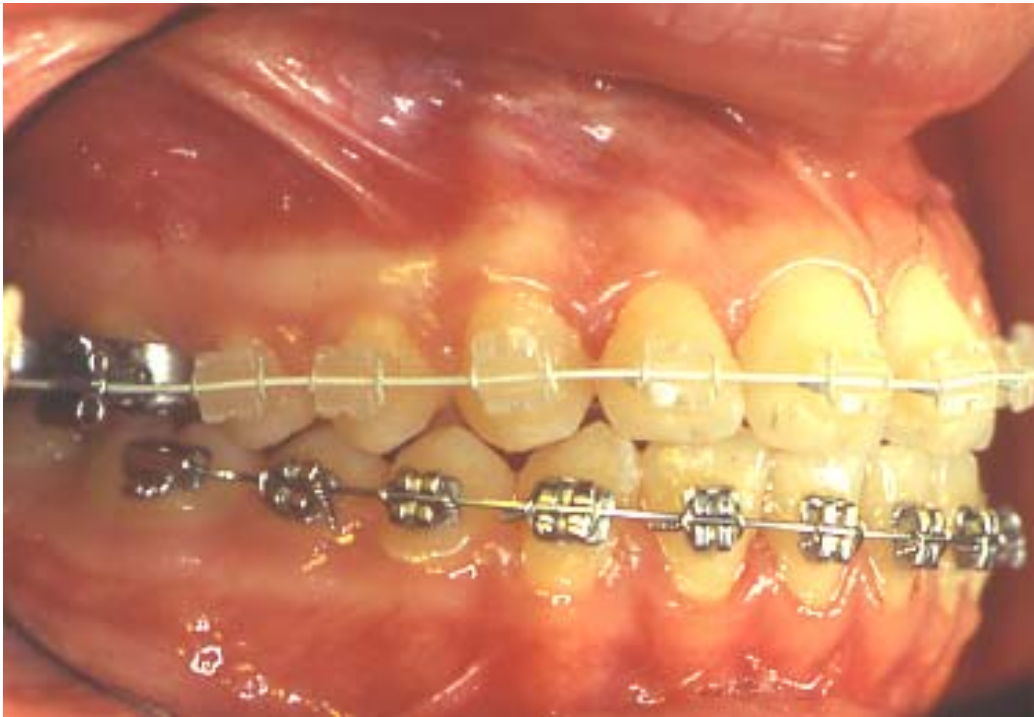
Opportunità...

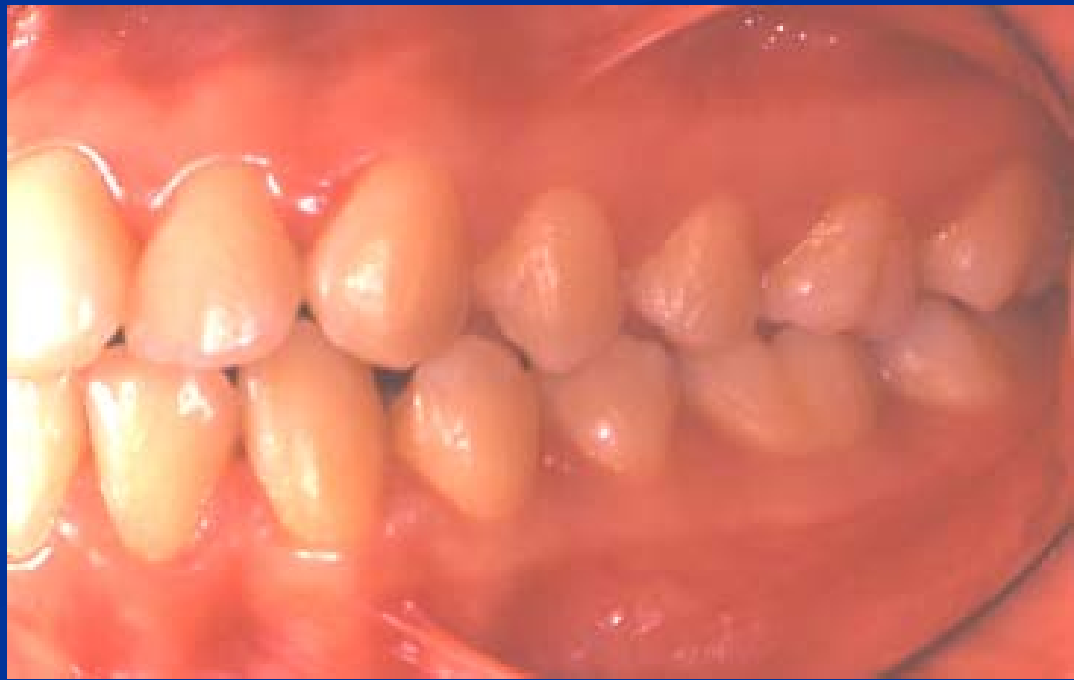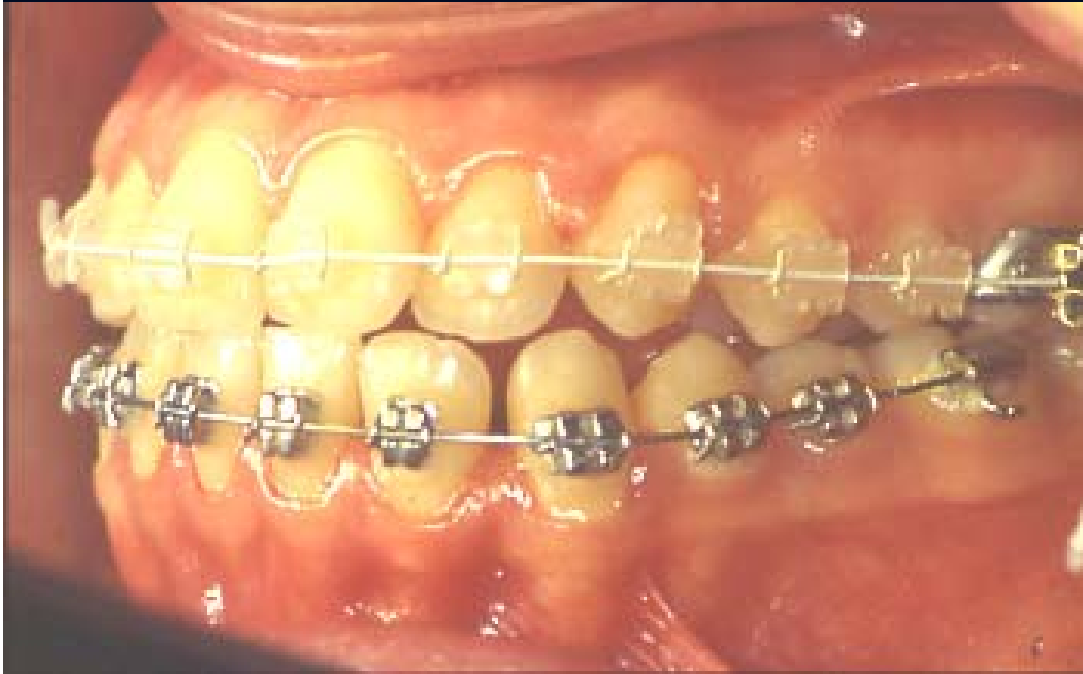
-Cosmetica



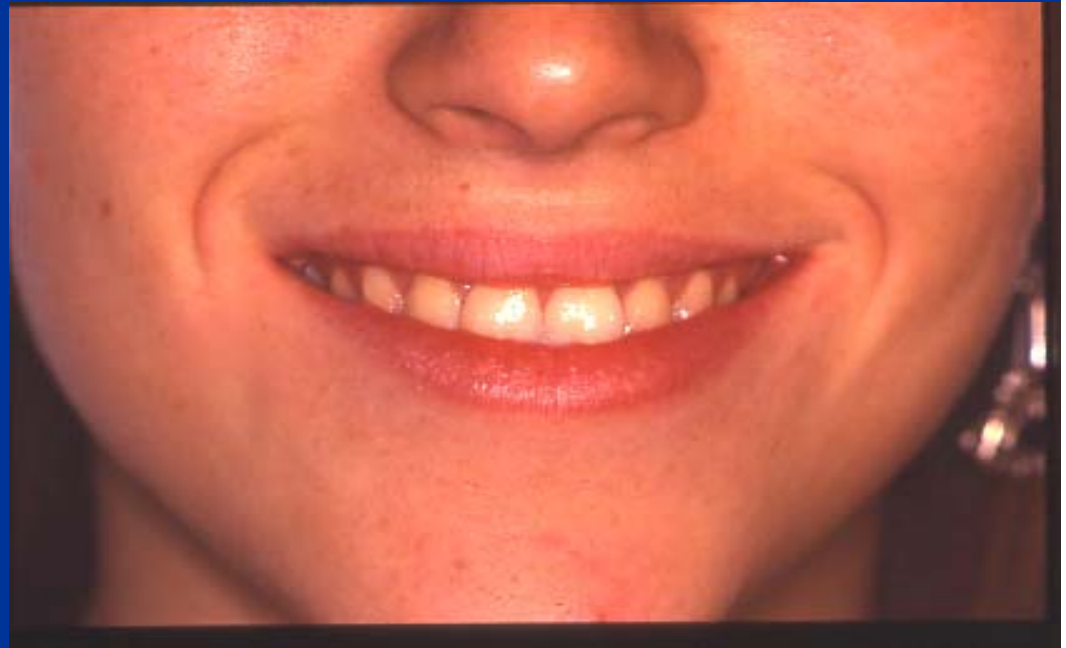

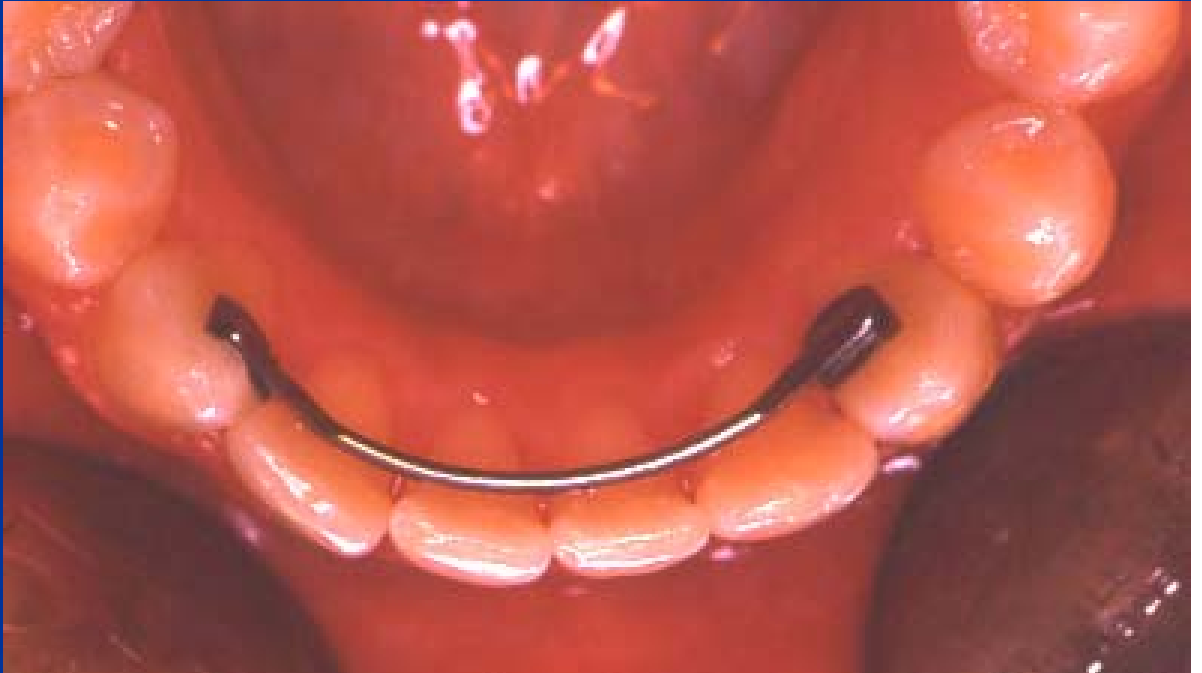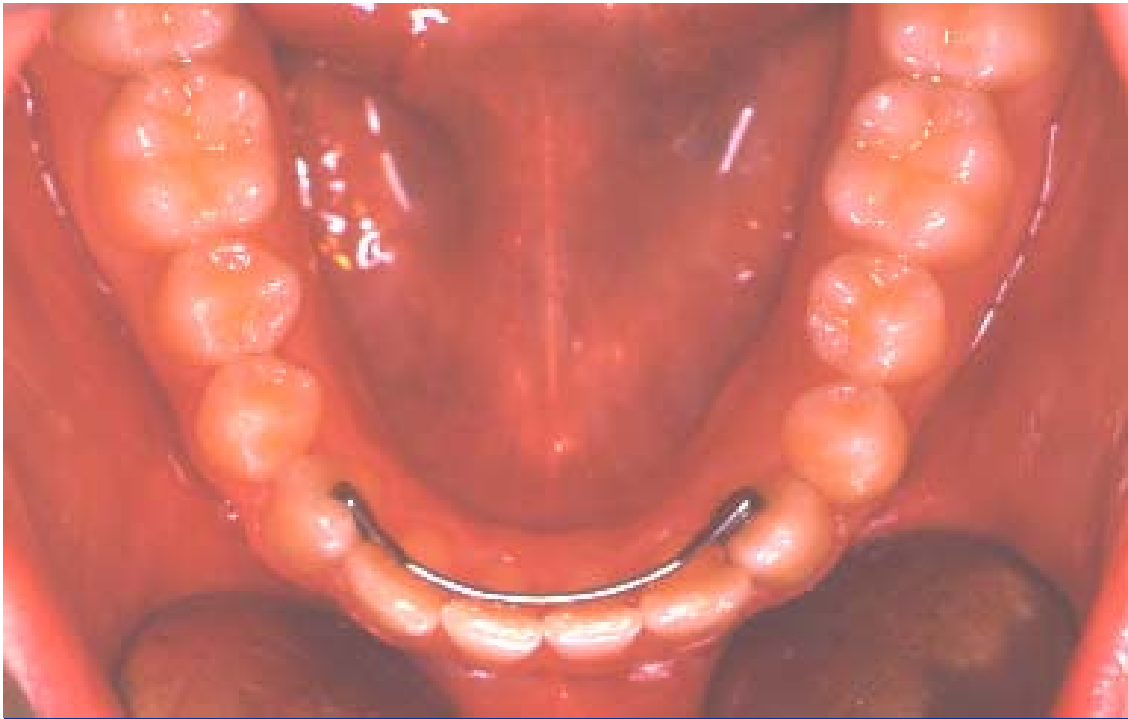














# I trends...



Domani...



**Grazie per la gentile attenzione**