

Distretto Rino-Sinuso-Faringo-Timpanico

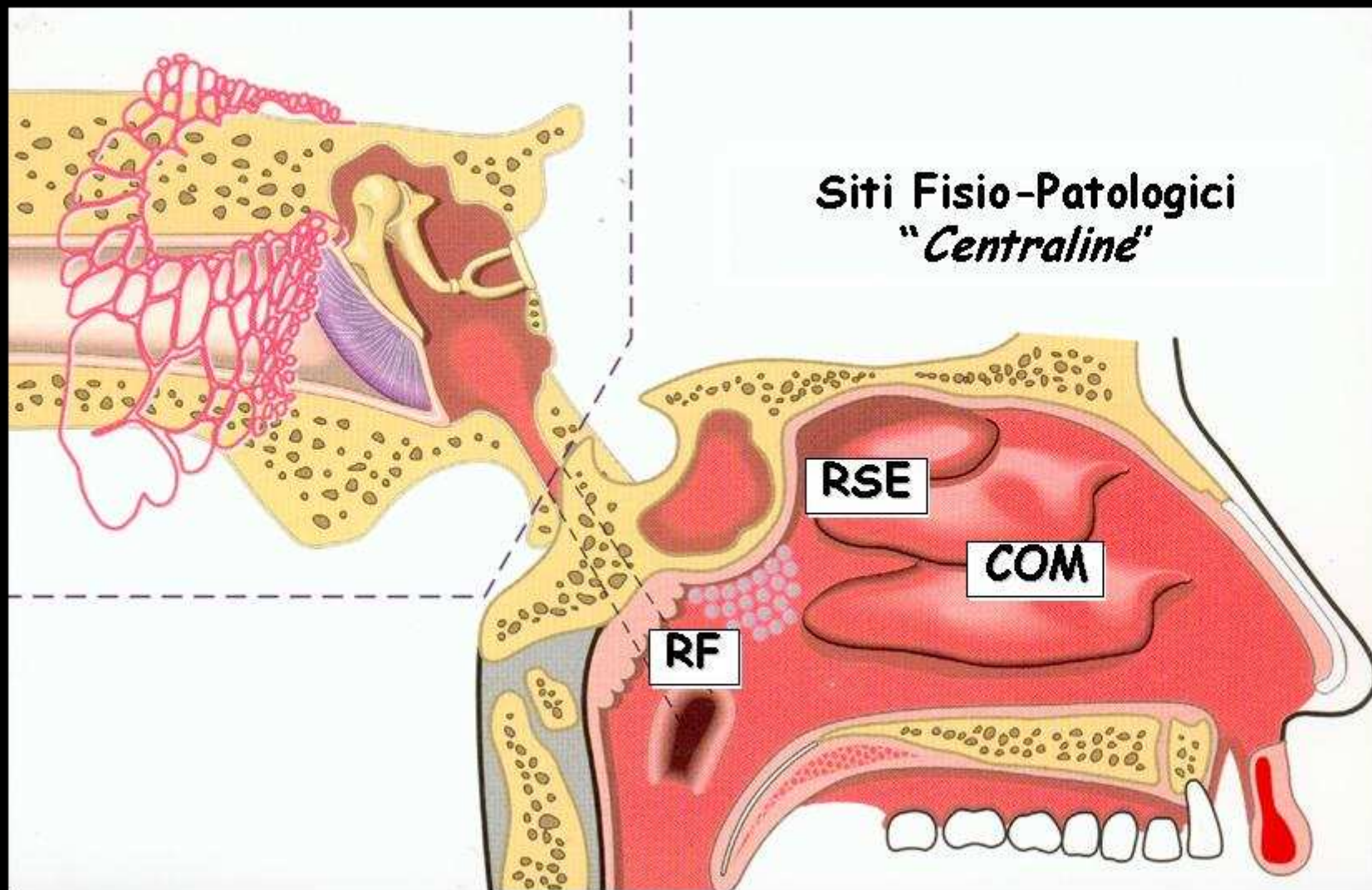


Fig. 1

Complesso Ostio-Meatale e Recesso Sfeno-Etmoidale

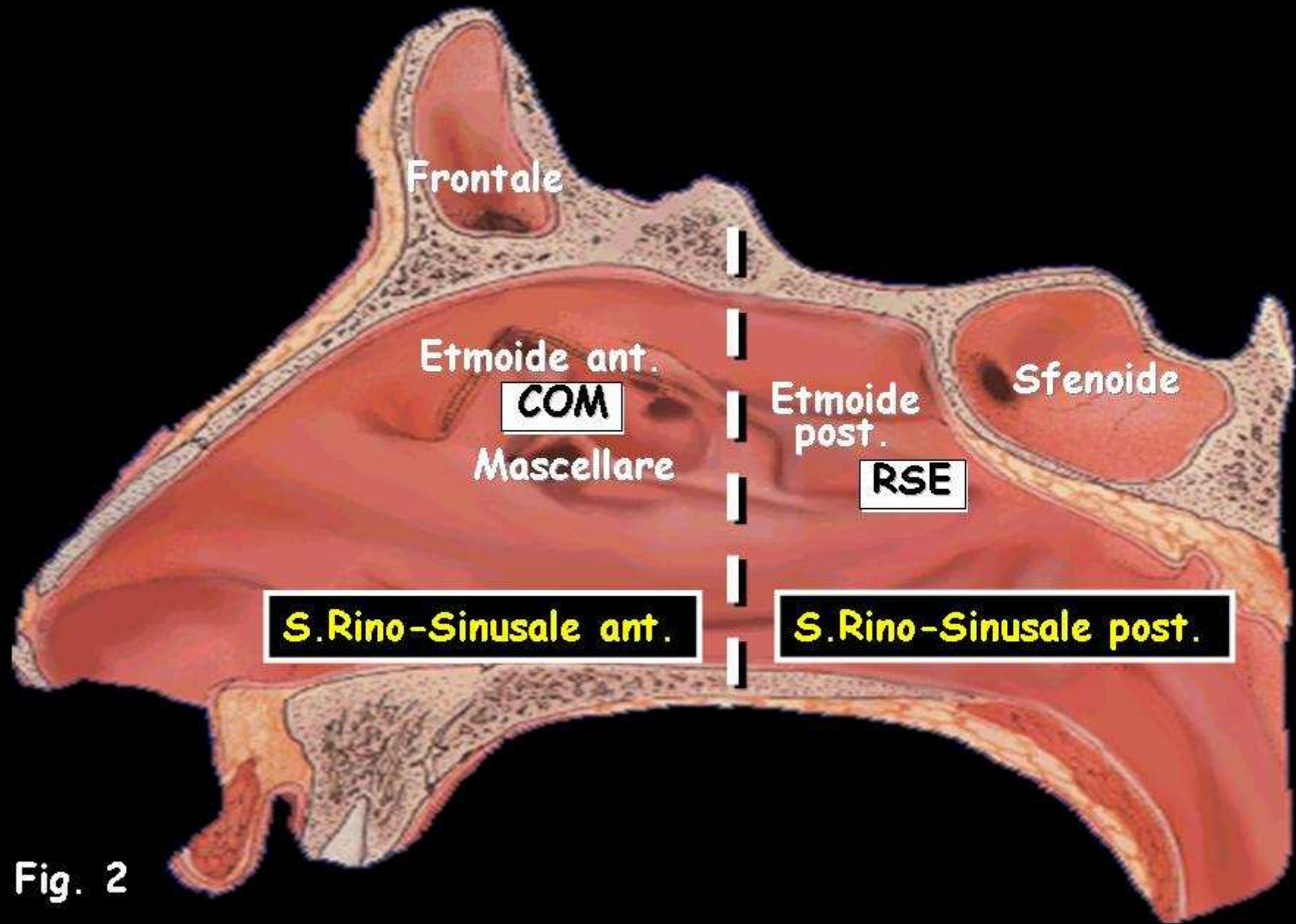


Fig. 2

Rinofaringe

Implicato nella patogenesi delle otiti medie

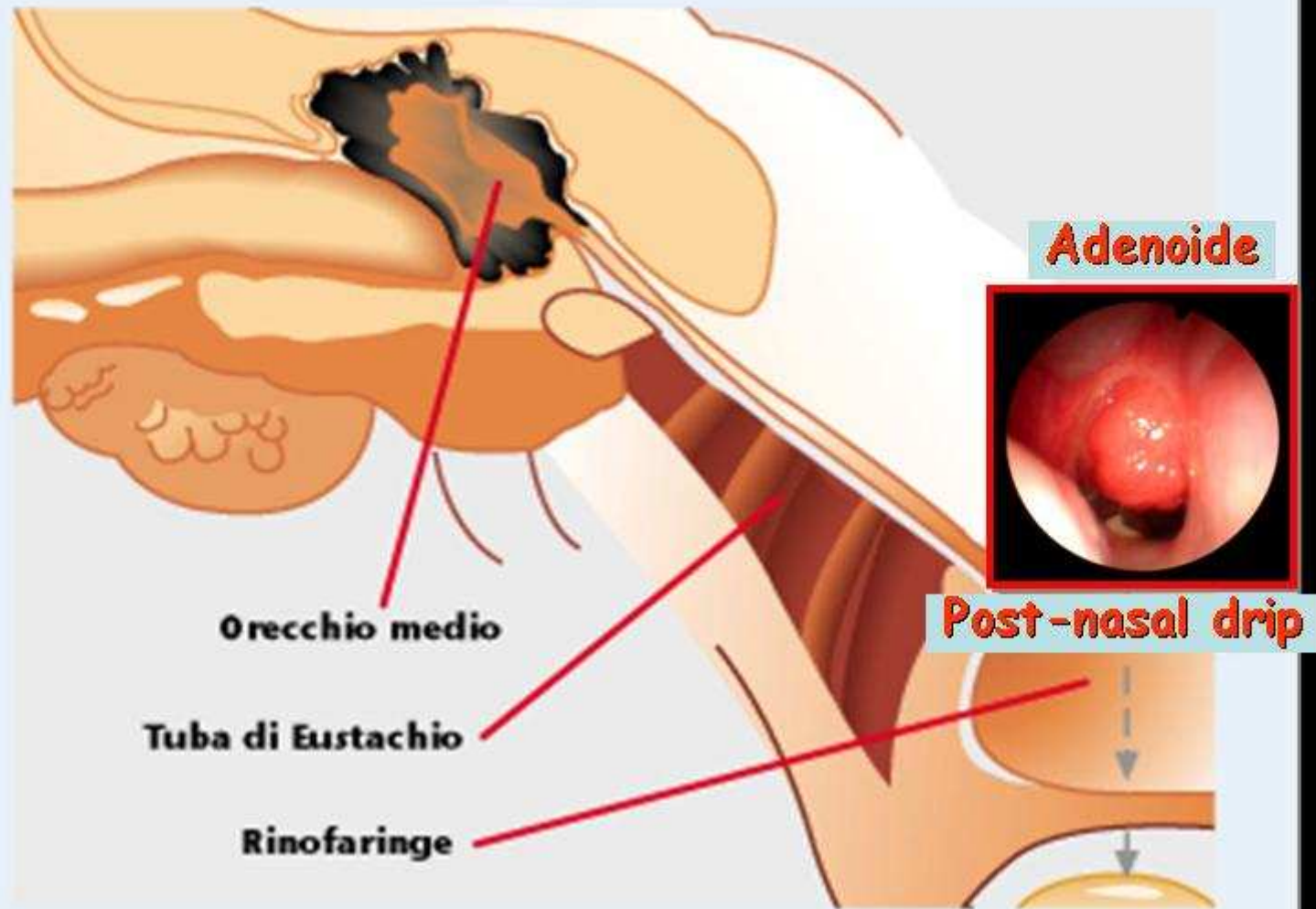


Fig. 3

Spray predosato

La Terapia Inalatoria delle V.A.S.

Spray
predosato

COM e RSE

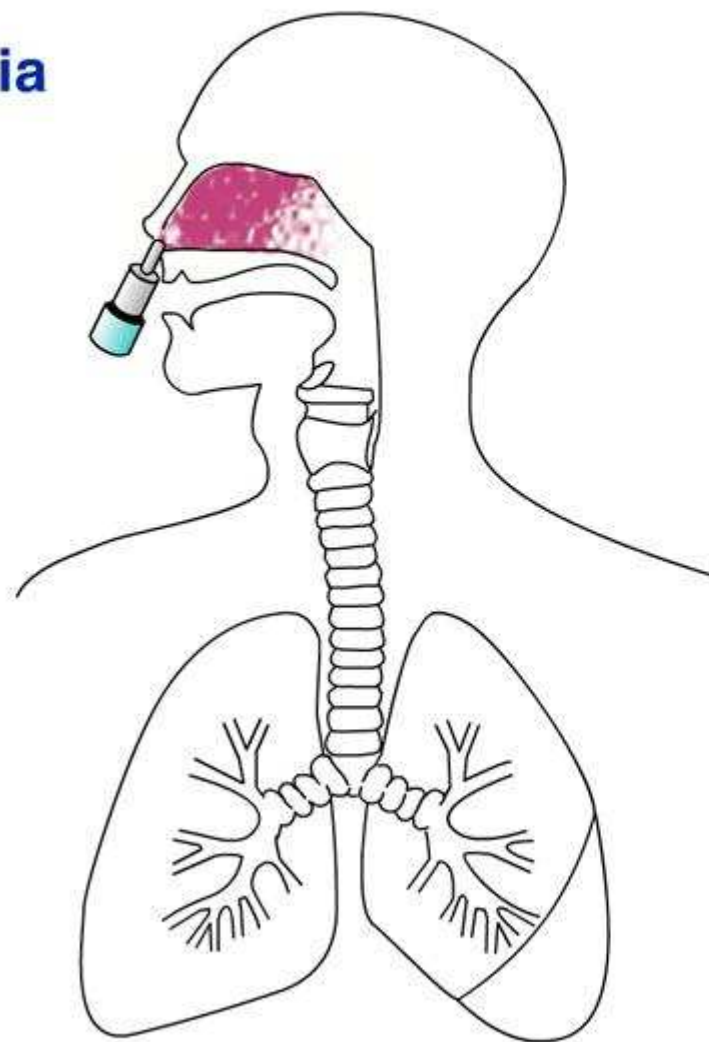
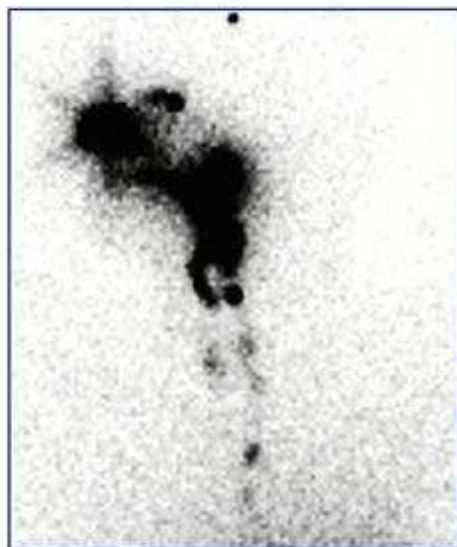

Fig. 4

Doccia Nasale

La Terapia Inalatoria
delle V.A.S.

Doccia nasale

COM - RSE - RF

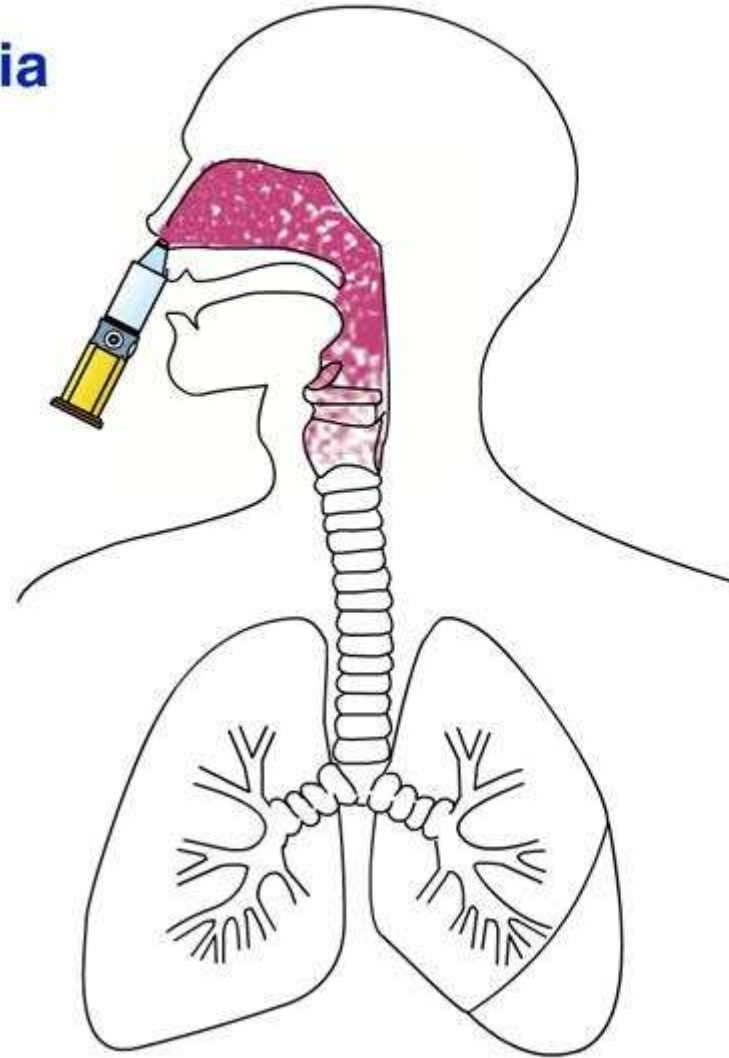
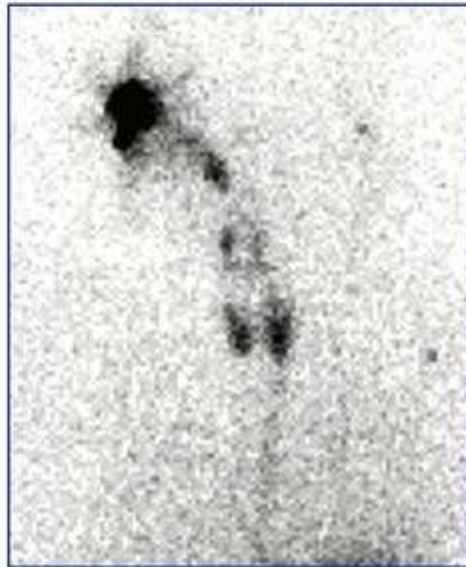


Fig. 5

COM, RSE e RF condizionano le "vie aeree"

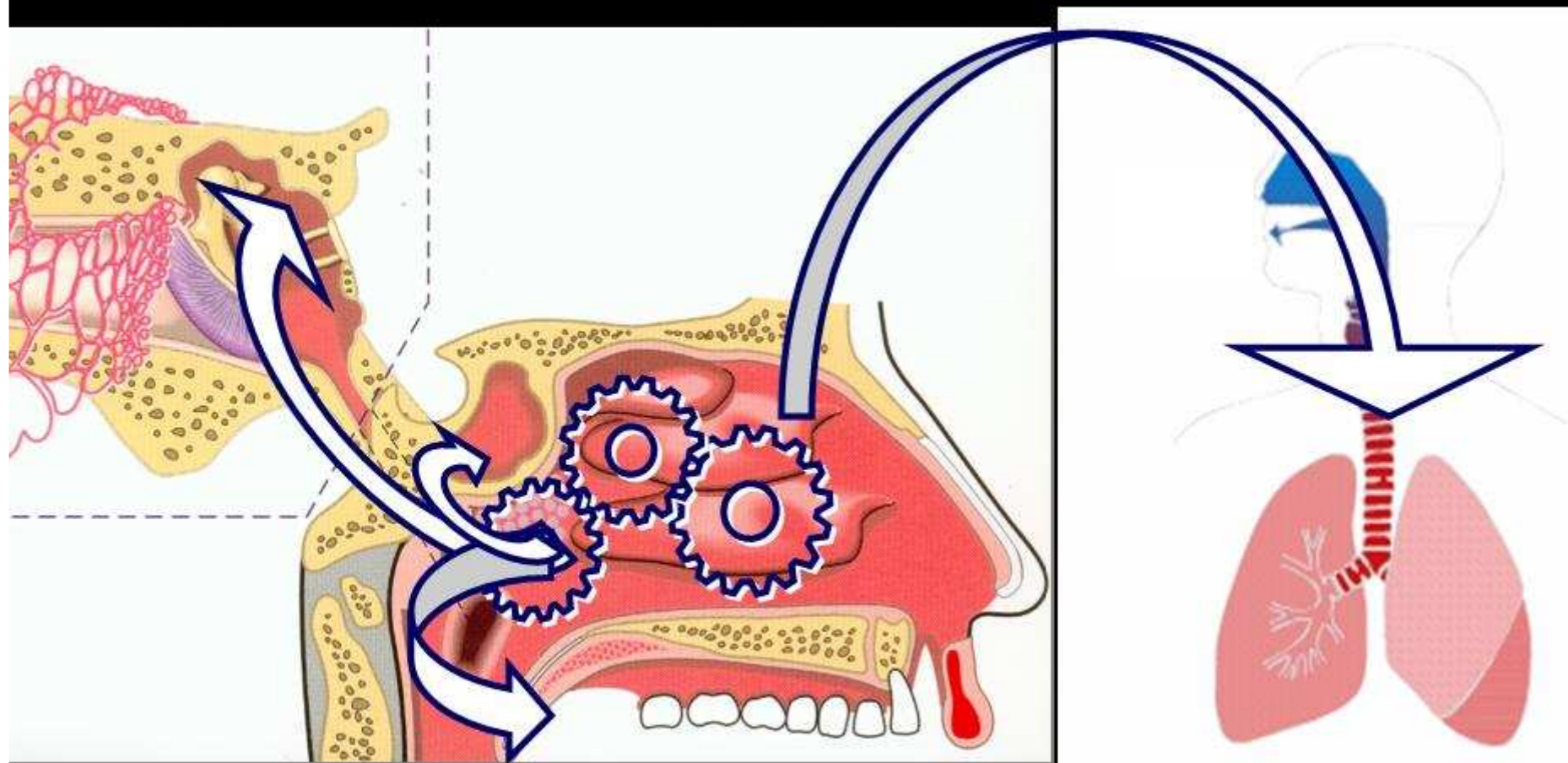


Fig. 6